

Digital, AI and us...

Think aloud

Pr Christian Lovis MD MPH

Division of medical information sciences @HUG
lifesciences, track «Genomics and digital health» @UNIGE

DALL-E, <https://labs.openai.com>



DataRaptor Team acknowledgements & conflict of interests

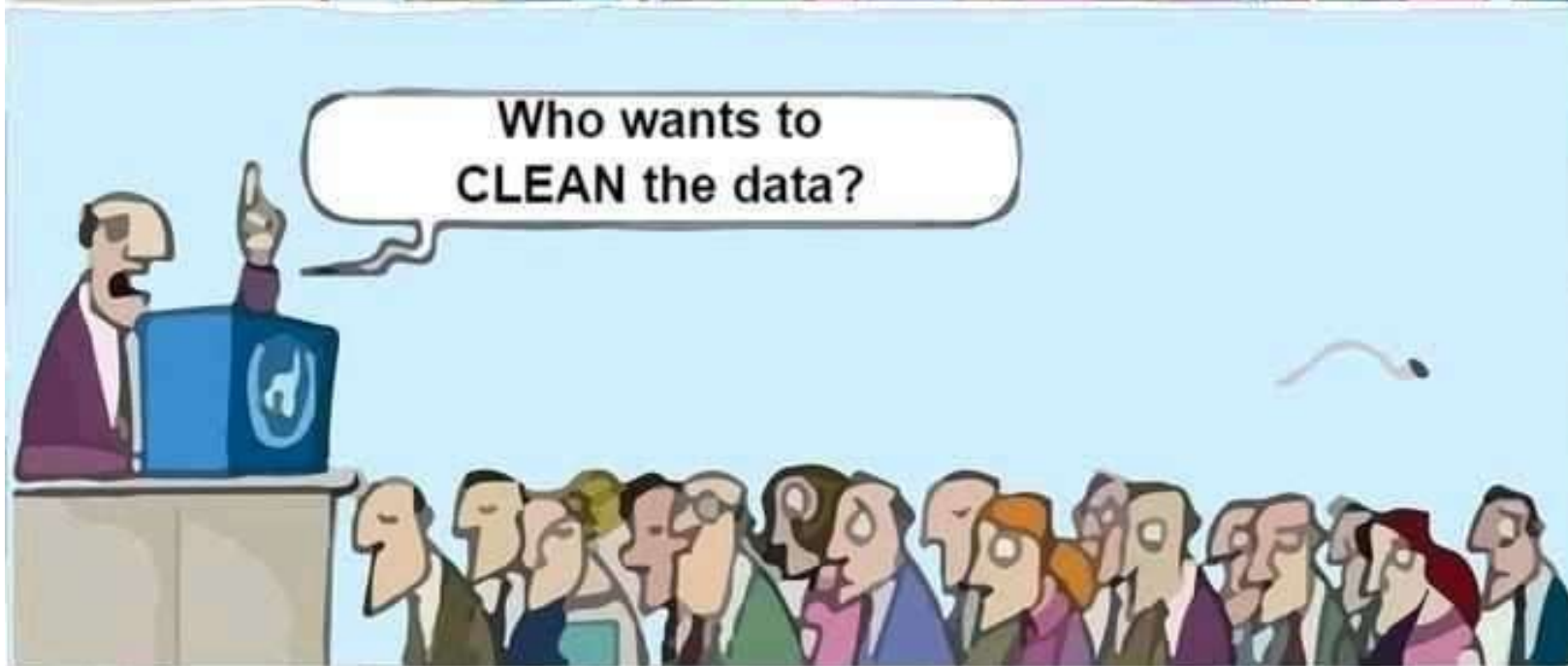

INFORMATION
20 YEARS AGO



INFORMATION
TODAY





"The plural of
anecdote



is not
data."

attributed to
Erika Engelhaupt





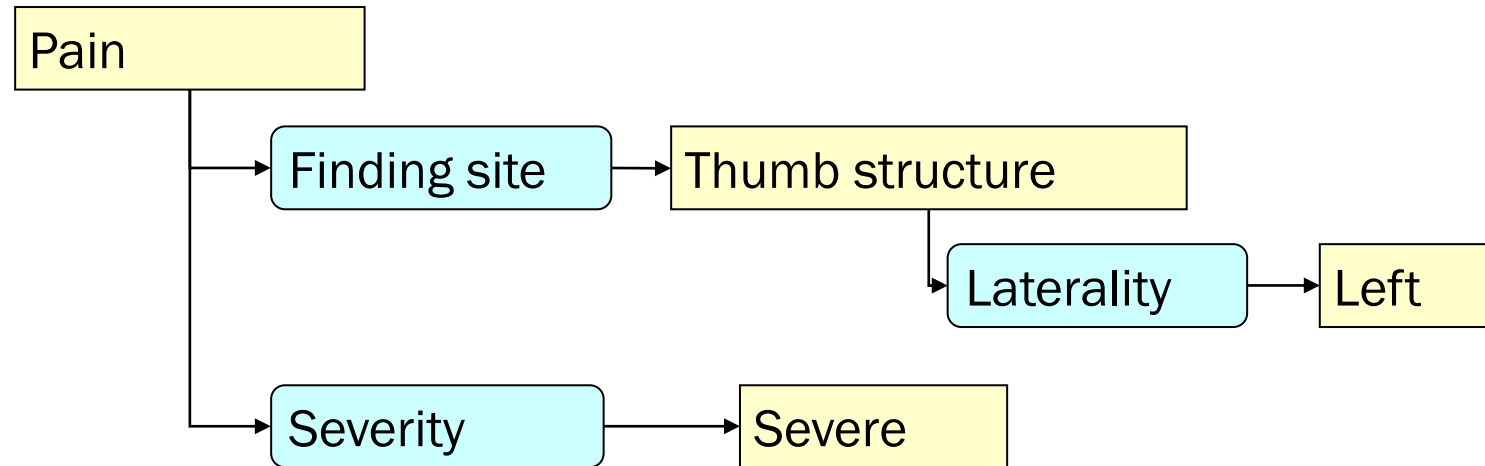
Narrative
representation

Snow white asleep, surrounded
by the mourning dwarves.

ICD-10
representation

- R40.2 Coma
- T57.0 Toxic effect of Arsenic and its compounds
- Z63 Other problems related to primary support group, including family circumstances
- E34.3 Short stature, not elsewhere classified

Quantity of information decreases and losses increases



22253000 | pain |:

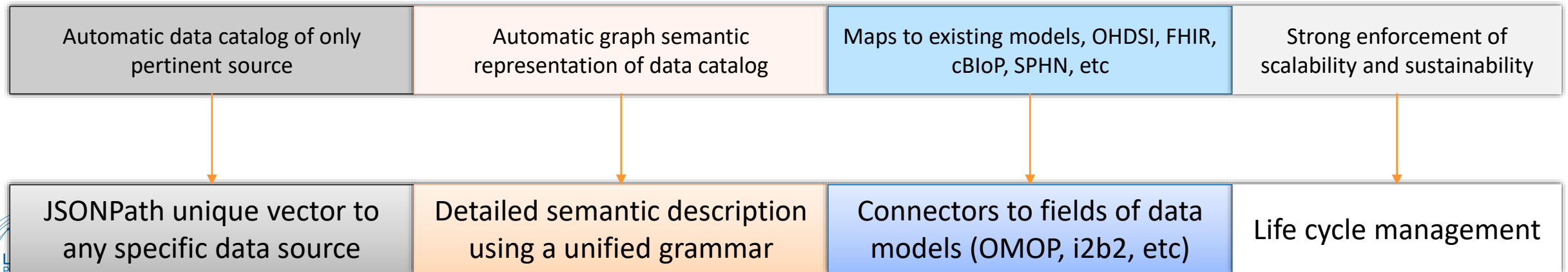
363698007 | finding site | =

(76505004 | thumb structure |:

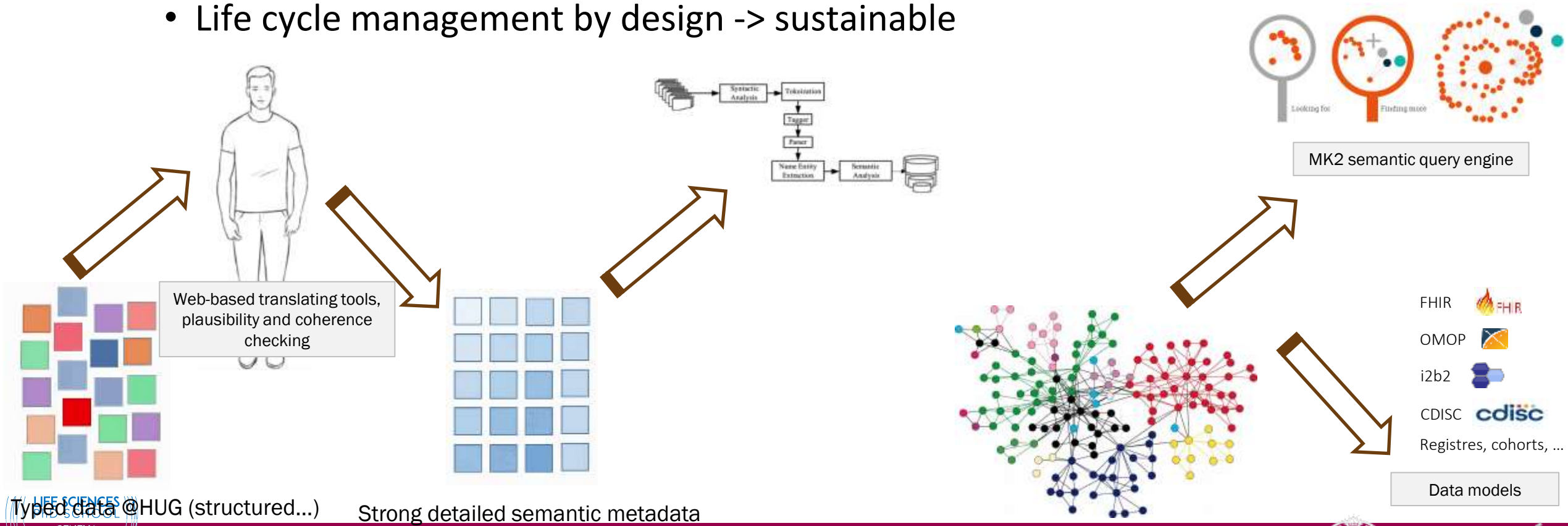
272741003 | laterality | = 7771000 | left |),

246112005 | severity | = 24484000 | severe |

- Allows to include any data source
- Unique grammar accepts multiple classifications (SNOMED, Nanda, Nextstrain, ...)
- Can feed data models, registries, etc.
- Life cycle management by design



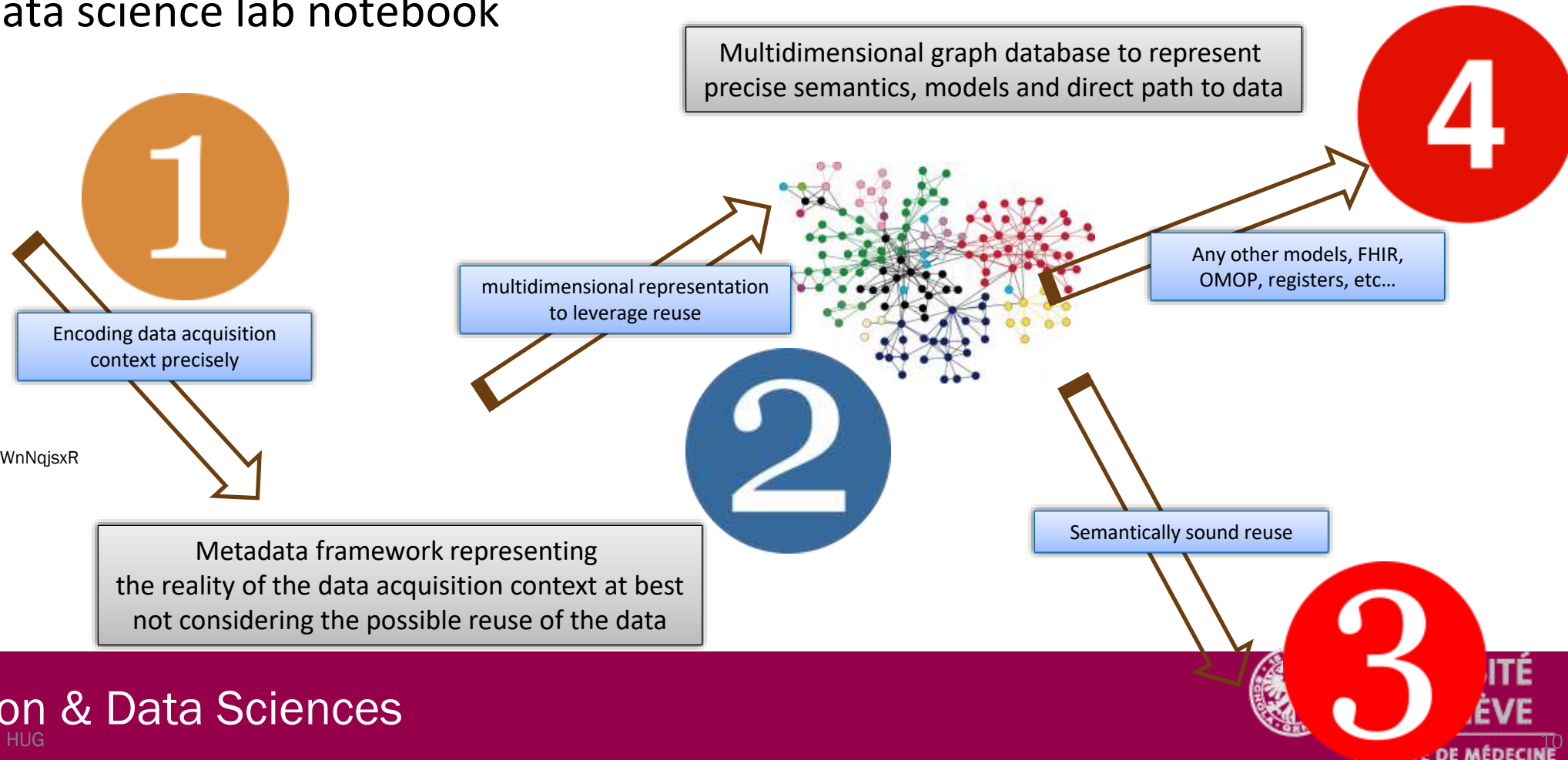
- Semantic coding by human experts, ML/NLP tools -> efficient
- Multilevel documentation and guidelines -> scalable
- Support tools, datascience ELN -> auditable and reproducible
- Life cycle management by design -> sustainable



- Fine tuning using specific human competent resources
- Building guidelines on the fly of building/using
- State-of-the-art technological portable developments
- Embedded data science lab notebook



© DALL-E, 02.07.2023,
<https://labs.openai.com/s/518kUqyrOSCFTNg8WnNqjsxR>



Real world truths (plural)

HUG n=23,596

University Hospitals of Geneva
Echocardiography Imaging Unit

Transthoracic Echocardiography: 28.10.2018

Name	John Doe	Sex	Male
D.O.B	06.01.1975	Weight	80 kg
Size	178 cm	Exam quality	Average

Clinical indications: Evaluation of left ventricular function
Clinical information: Atrial fibrillation since 2007

Measure mode 2D/TM

IVS thickness:	LV diam: 6.7 cm	LVM: 240.4 g
0.77cm		
	LV indx diam: 3.4	LVMI: 121.4 g/m ²
MAPSE: 0.56 cm	TAPSE: 1.8 cm	

Summary
The left ventricle is moderately dilated with a severely decreased ejection fraction, visually estimated to be 15-20% subject to tachycardic AF. Severe global hypokinesia..

3943 ECGs
annotated with both
modalities
74.1% agreement

HUG n=2,278

University Hospitals of Geneva
Imaging Department

Cardiac MRI: 09.11.2018

Name	John Doe	Sex	Male
D.O.B	06.01.1975	Weight	80 kg
Size	178 cm	Exam quality	Average

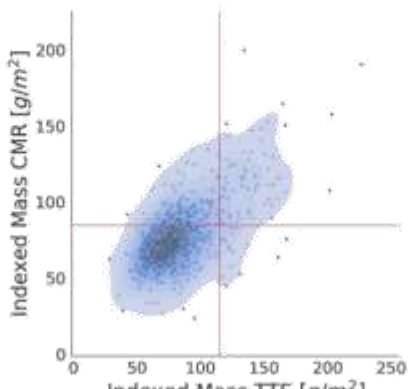
Clinical indications: Reduced LV ejection fraction
Technic: Exam performed on SIEMENS AERA 1.5 Tesla

Description
The atria are severely dilated, calculated at 39 cm² for the left atrium and 29 cm² for the right atrium. LVH with a myocardial mass of 144 g/m².

Left Ventricle

EDV	201 ml/m ²
Cardiac output	5.20 l/min
LVMI	144 g/m²

Gold Standard



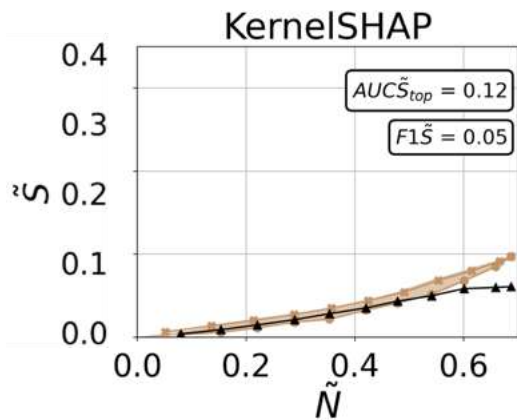
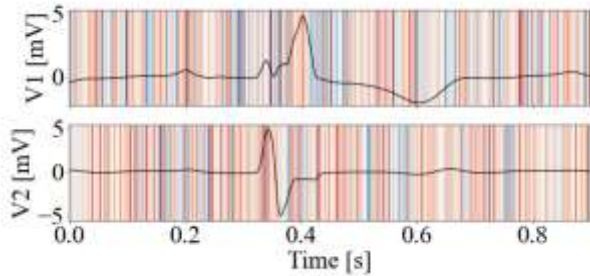
Turbé H et al. Comparing echocardiography and magnetic resonance in left ventricular hypertrophy diagnosis. ACC 2023

Adapted Team SIMED

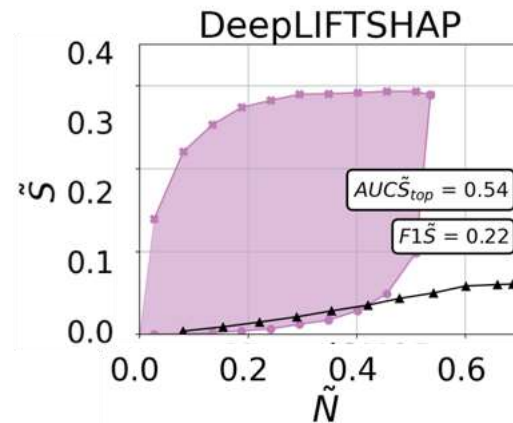
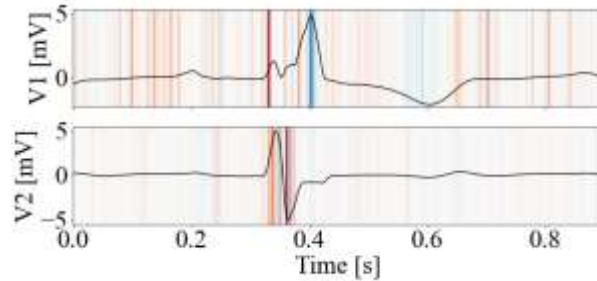
Interpretability



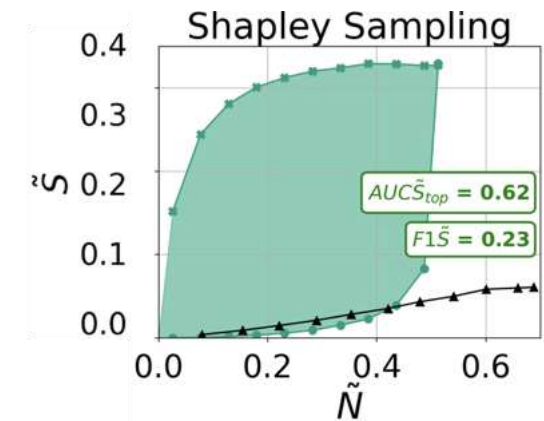
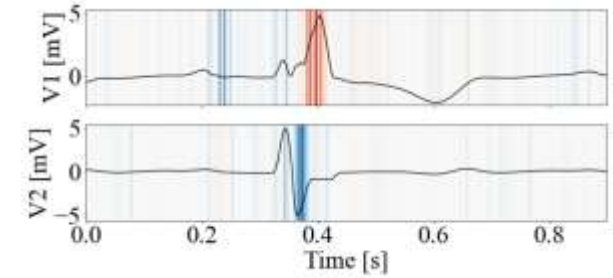
Noisy Map



Approximate Map



correct map



Turbé et al., Nature Machine Intelligence 2023