



*BCNM 2015*

# SPECT/CT INSTRUMENTATION AND CLINICAL APPLICATIONS

**Daniela Miladinova, MD PhD**

**Institute of Pathophysiology and Nuclear Medicine  
Academ.Isak S.Tadzer, Faculty of Medicine,  
University "Ss Cyril and Methodius"**

Medical Physics Workshop  
PET Development and Applications

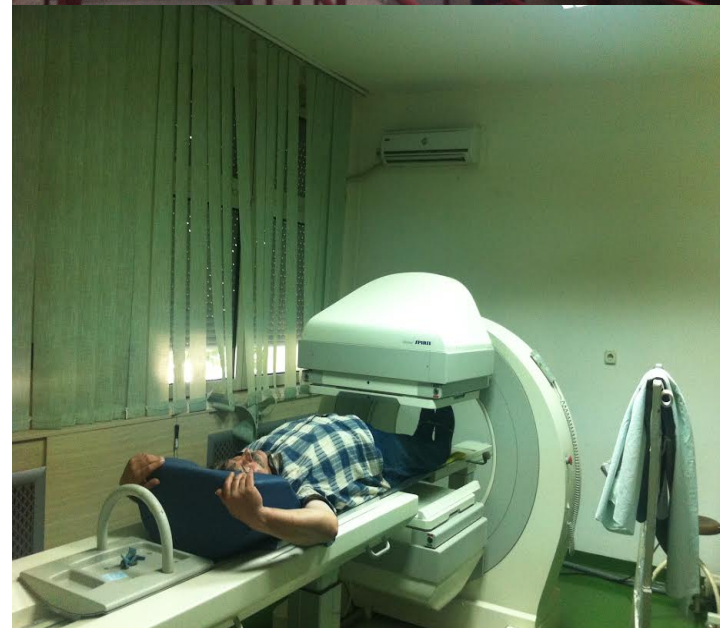Ohrid, 6<sup>th</sup> september 2015




[www.ukim.edu.mk](http://www.ukim.edu.mk)



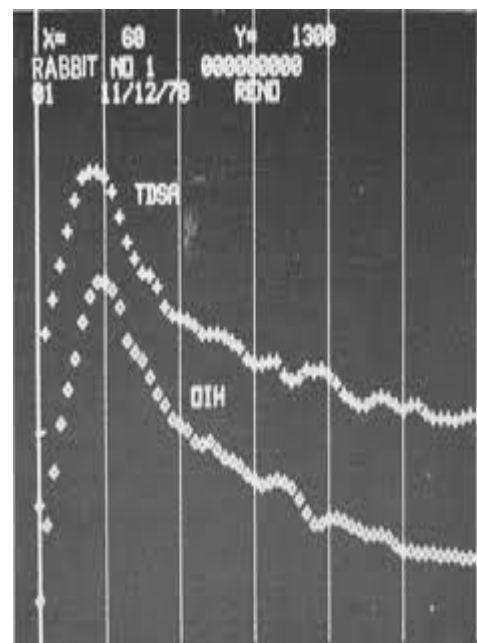
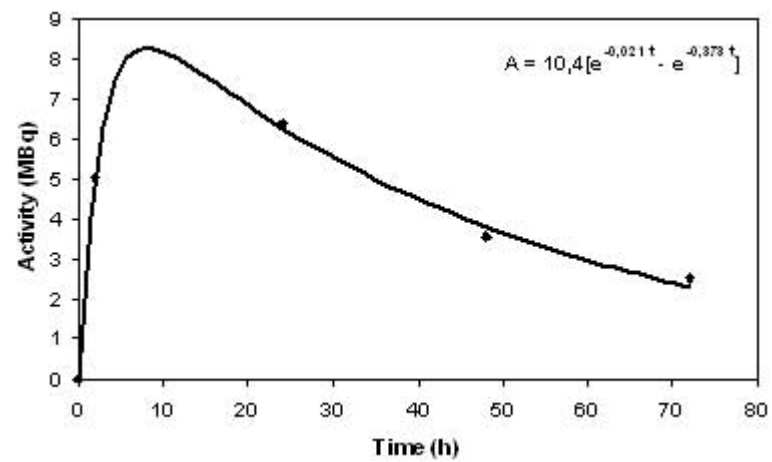
[www.medf.ukim.edu.mk](http://www.medf.ukim.edu.mk)




## SCINTILATION PROBES



## TIME ACTIVITY CURVES

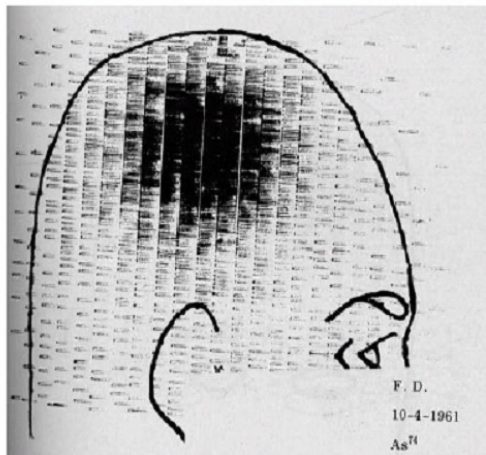
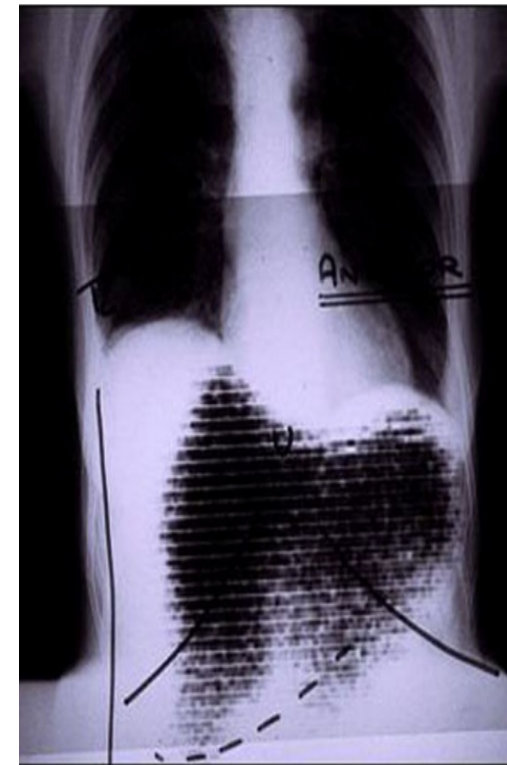


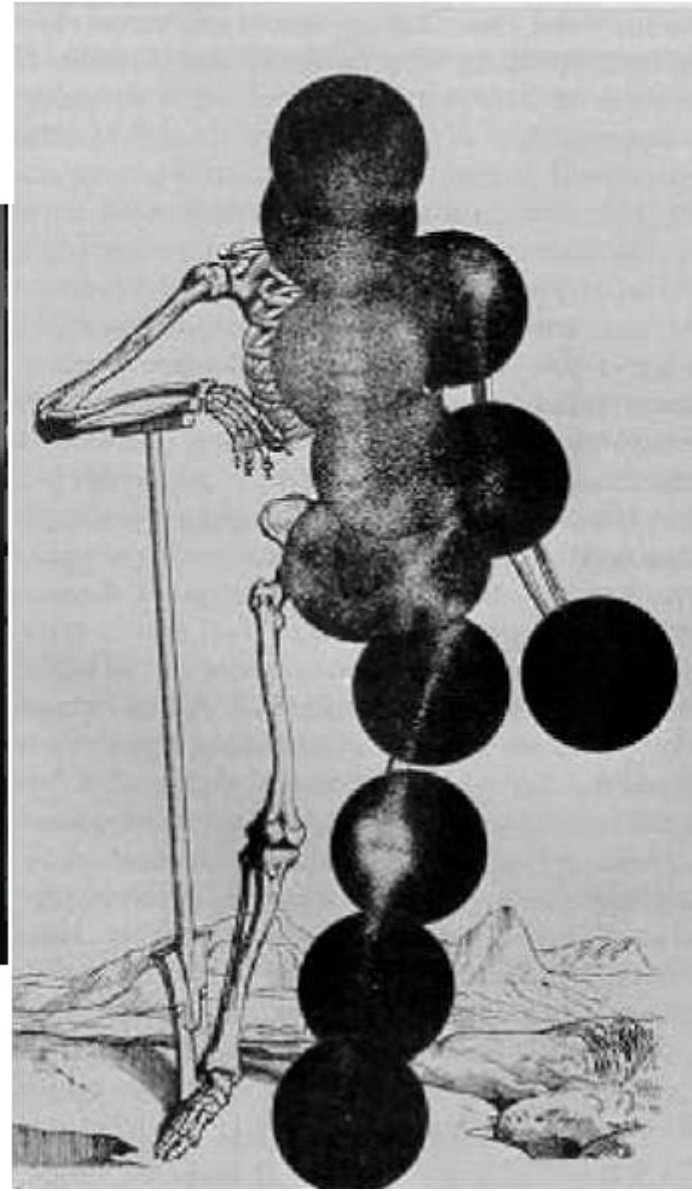


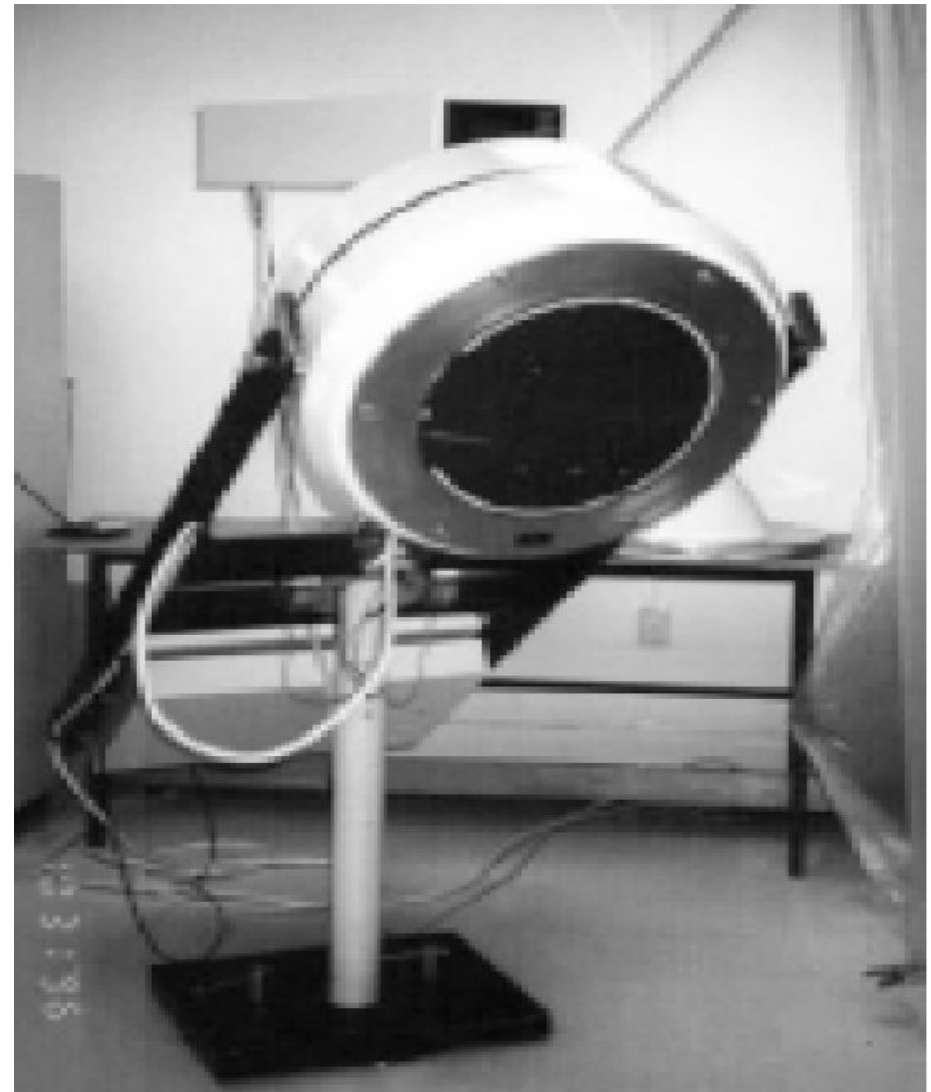
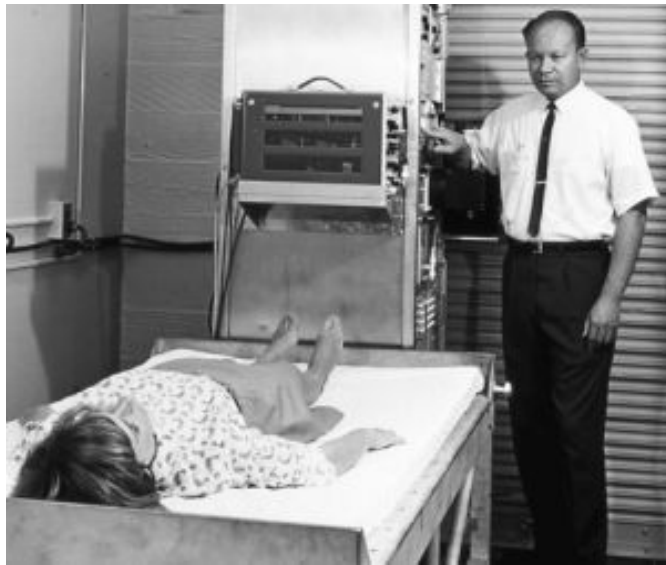



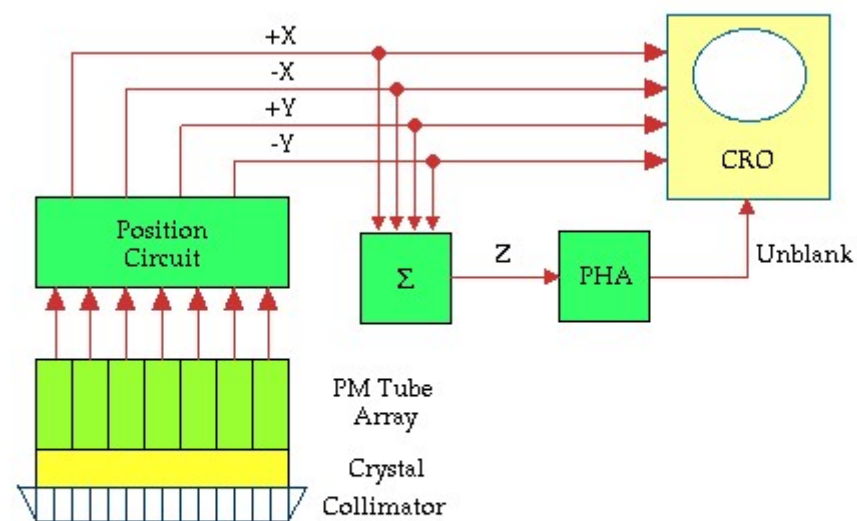
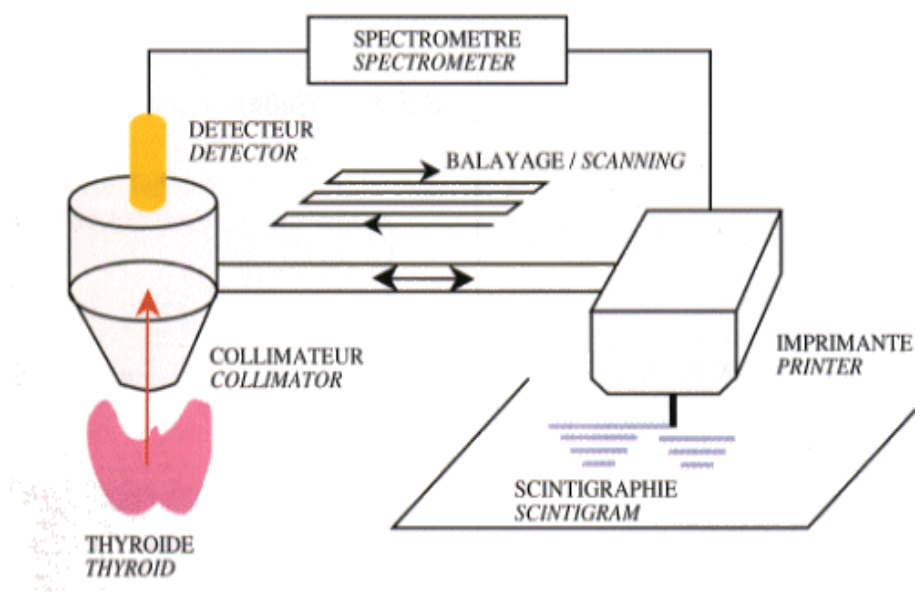
## RECTILNEAR SCANNER

## CORRELATIVE IMAGE









Organ containing  
radiopharmaceutical



**Lead shield**

**2D co-ordinates for the photon position are output from the arithmetic circuits to a CRO display**

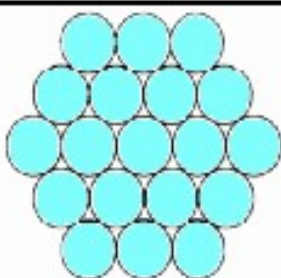
**Photomultiplier tubes (37 - 91 depending on the size of the detector) change light energy into electrical energy**

**Arithmetic circuits combine the output of each photomultiplier tube with that of its neighbour so that an electrical equivalent of light output for each crystal can be obtained**

**Collimator to ensure gamma ray collection from one orientation only**

**Scintillation crystal of sodium iodide (250 mm - 400 mm)**

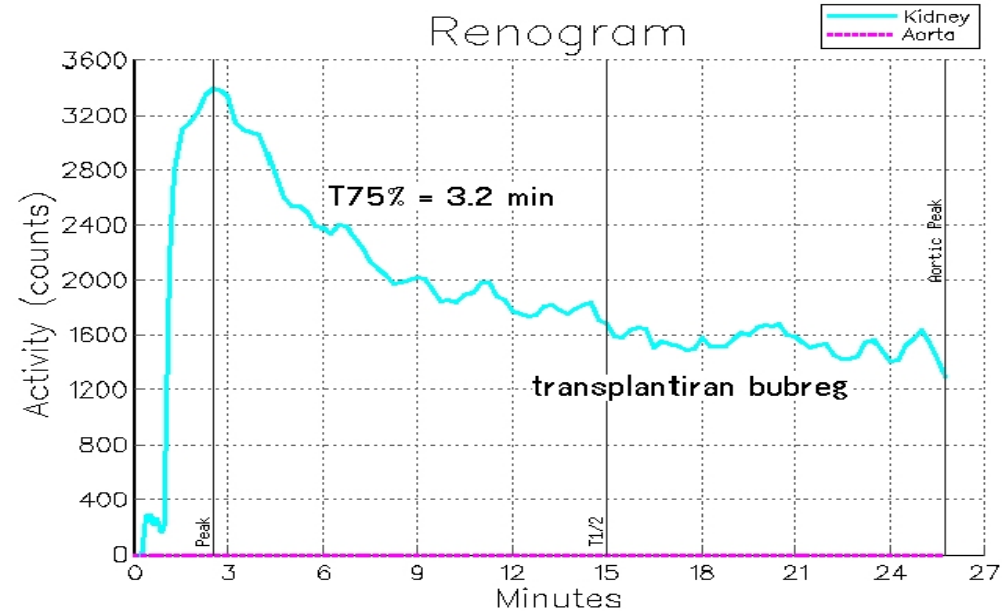
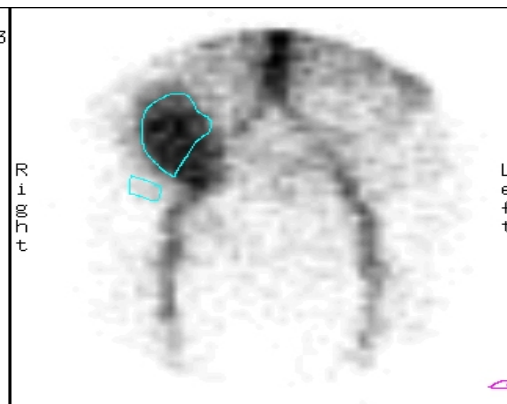

$\gamma$  rays



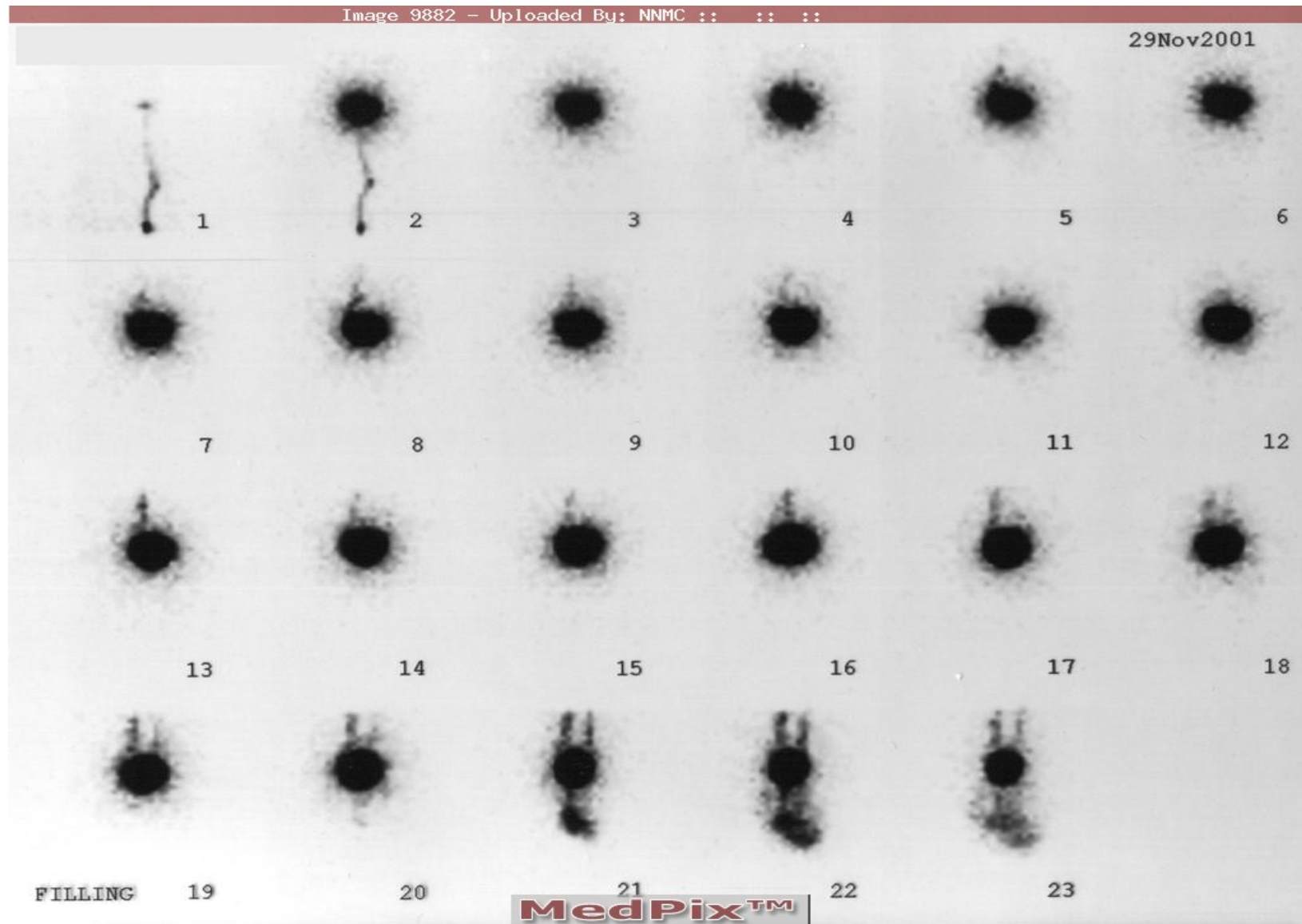
**Close packed arrangement of photo-multiplier tubes that scan the crystal**

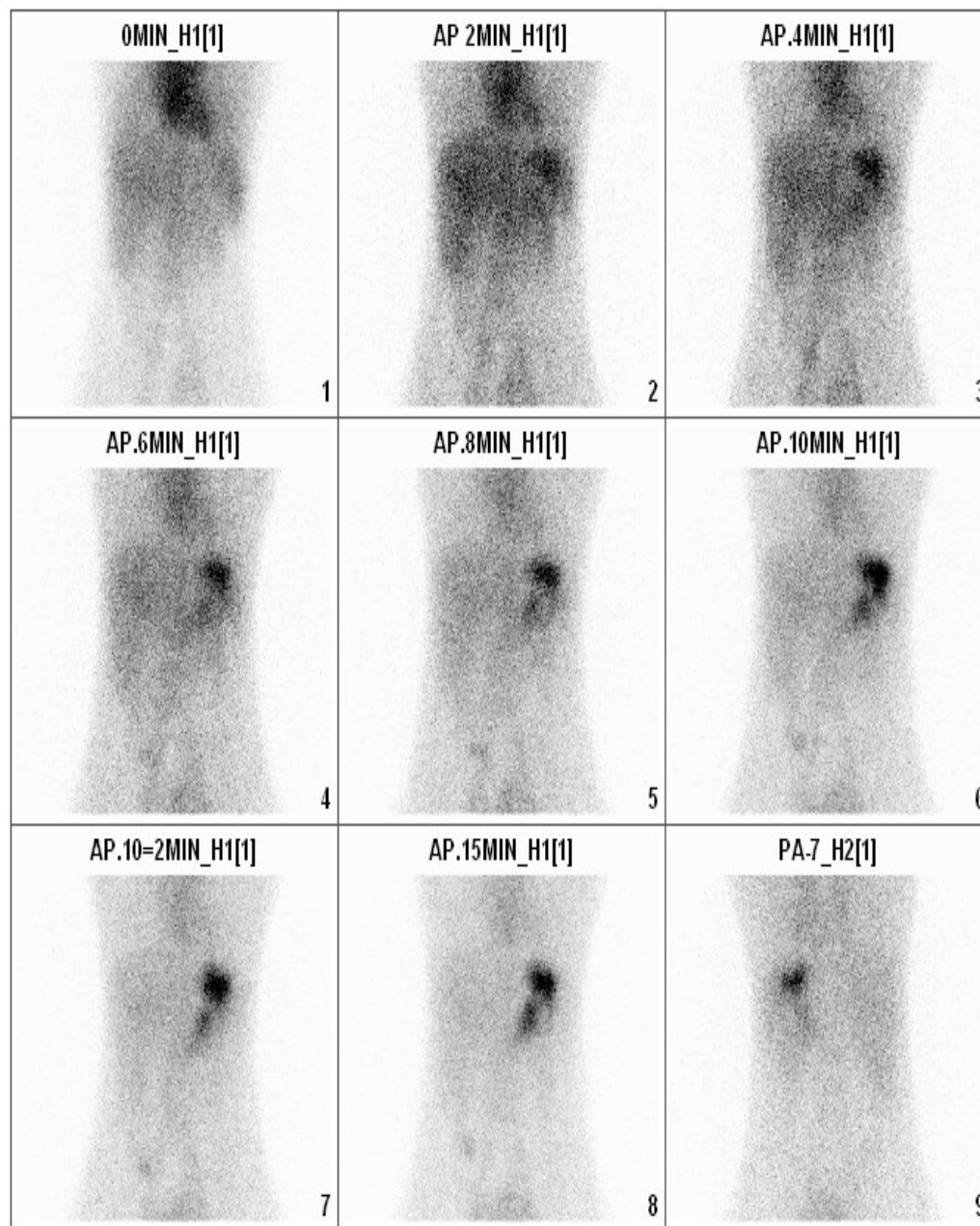
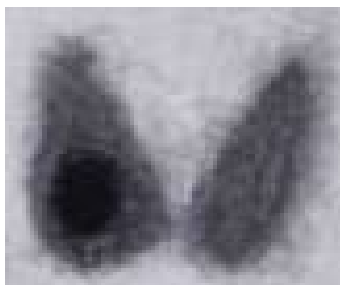
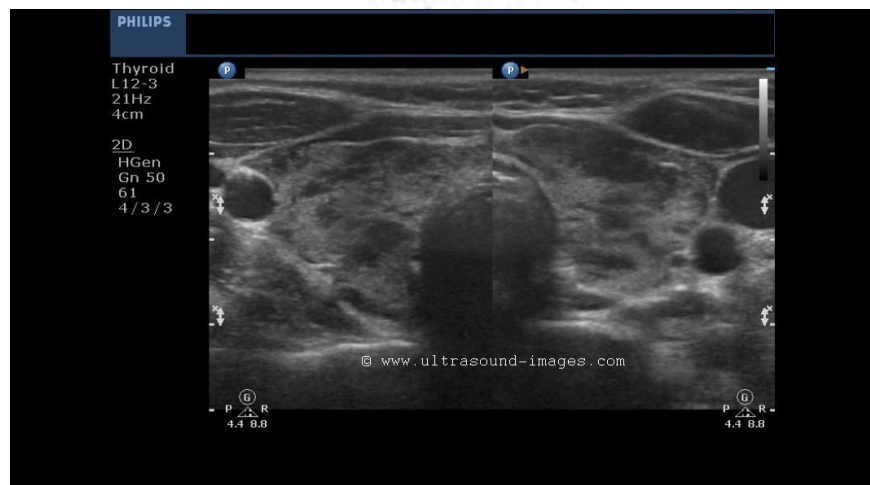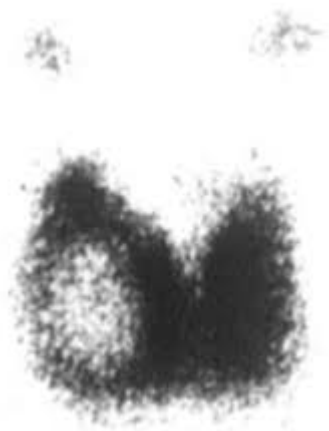ADZIOSKI OLOMAN-TRANSPLANTIRAN  
TRANSPLANTIRAN-

Oct 25, 2006 14:03

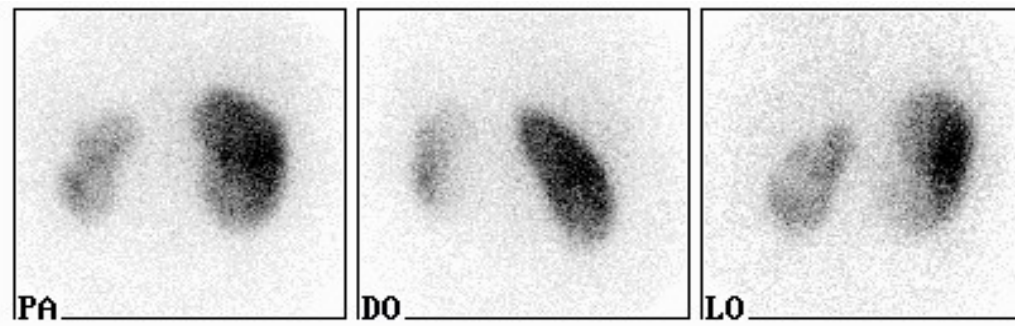
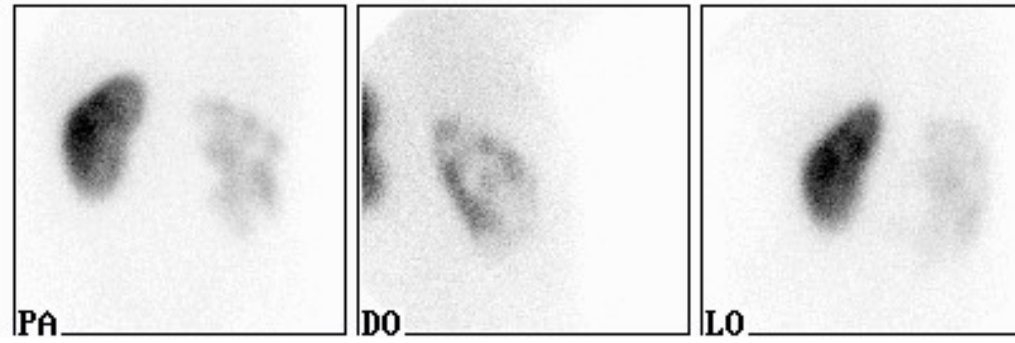
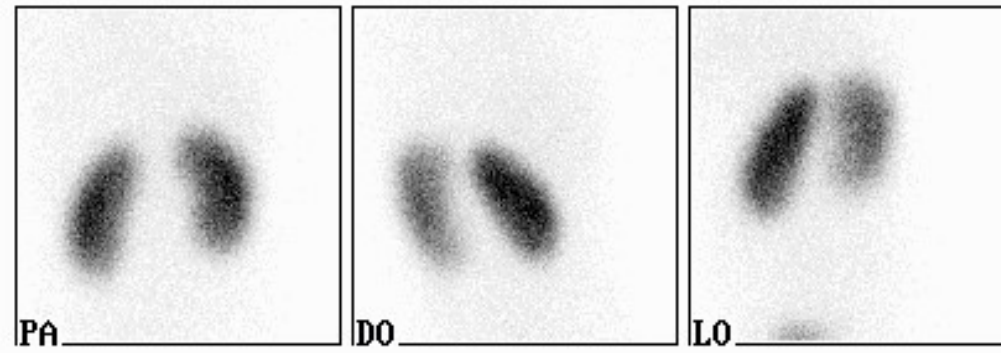


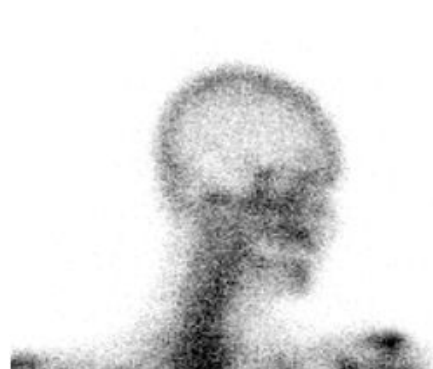Adzioski Oloman  
Transplantiran bubreg  
25-10-2006



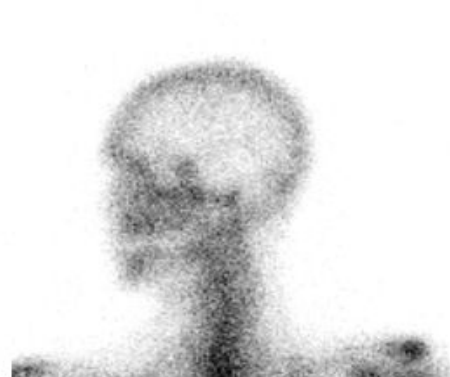



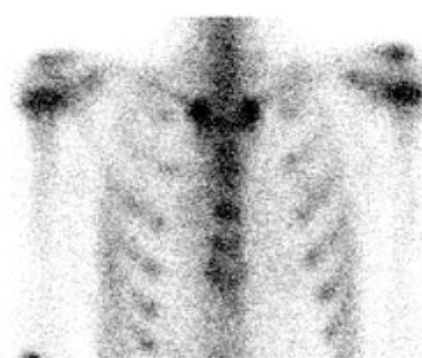




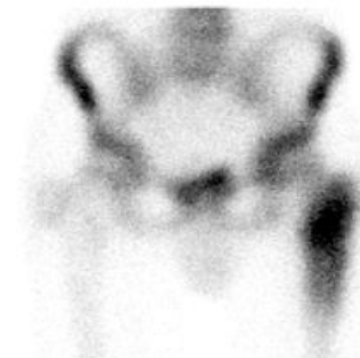DL GLAVA 150K



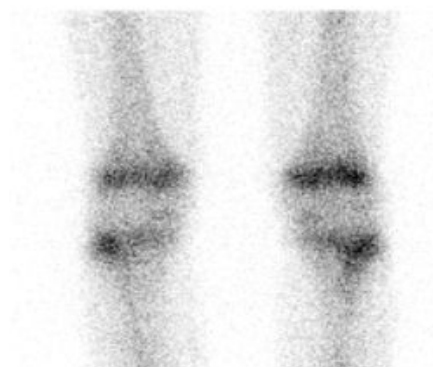
LL GLAVA 150K



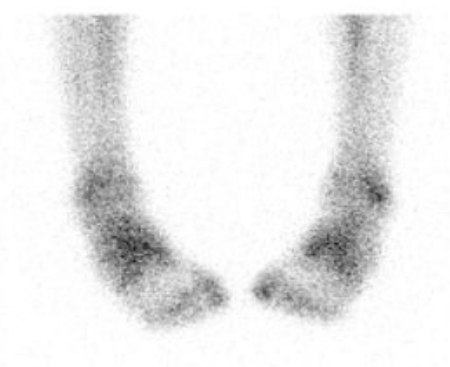AP RAMENJA 300K



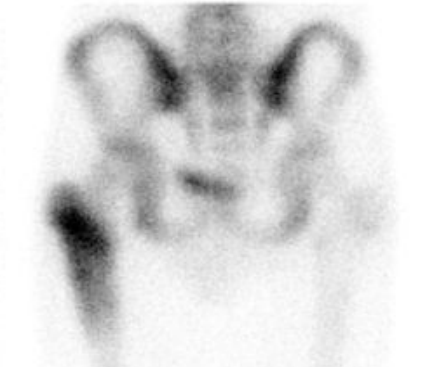AP KARLICA 799K



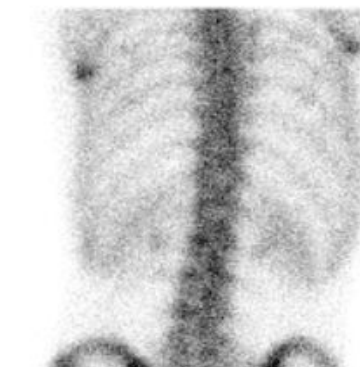AP KOLENA 149K



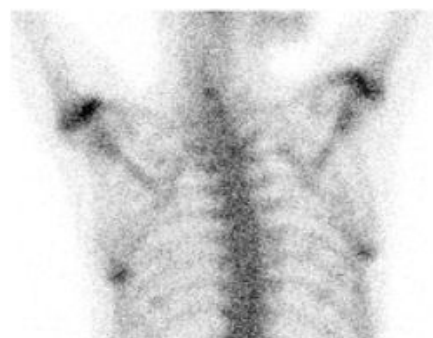AP STAPALA 100K



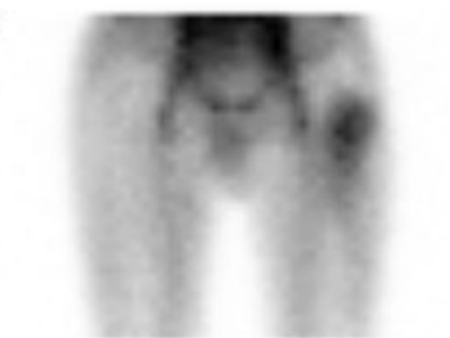
PA KARLICA 799K



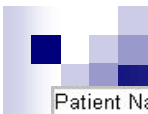PA KICMA 301K



PA RAMENJA 300K



pool 496K




Patient Name: azemi, durmiss

Patient ID: 2487

Study Name: Skelet

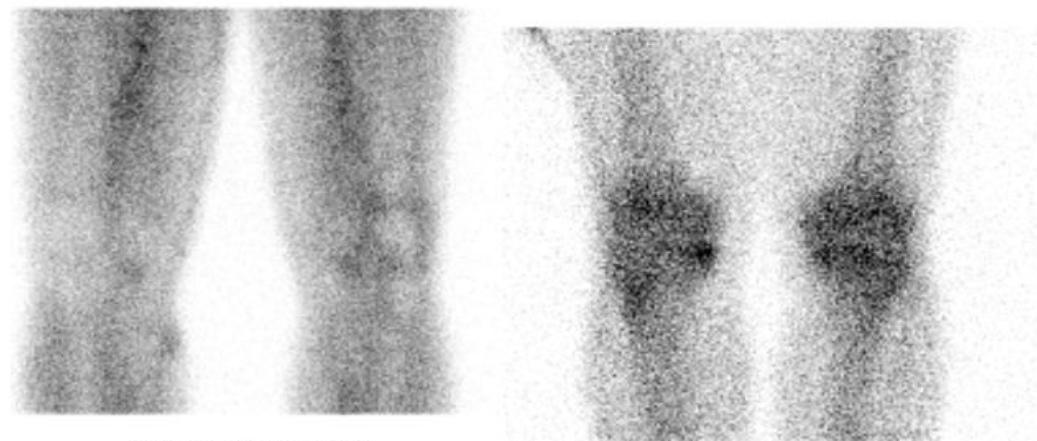
Study Date: 04.02.2005

**vaskularna 04.02.2005**



**statici 04.02.2005**

**<static> 04.02.2005**



pool 500K Duration:134sec

AP 152K Duration:124sec

Patient Name: azemi, durmiss

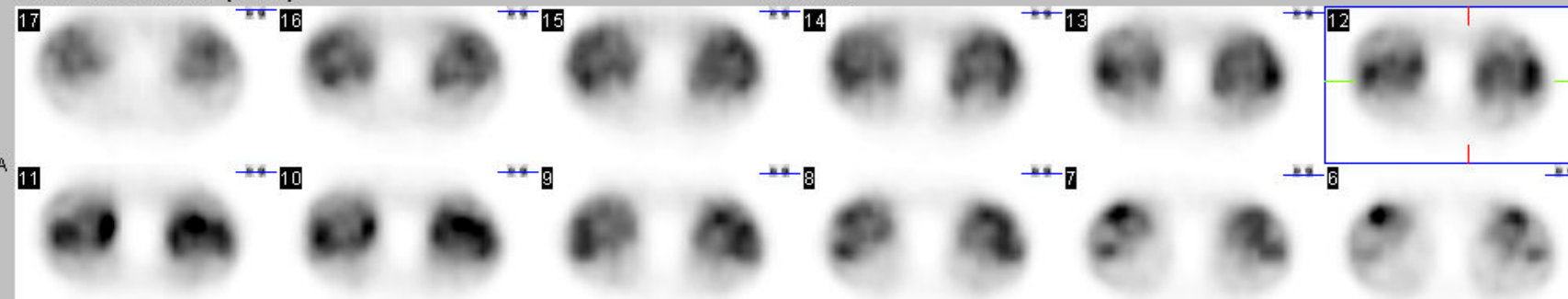
Patient ID: 2487

Study Name: Skelet


Study Date: 04.02.2005

Row A - <SPECT kosi> [Recon]

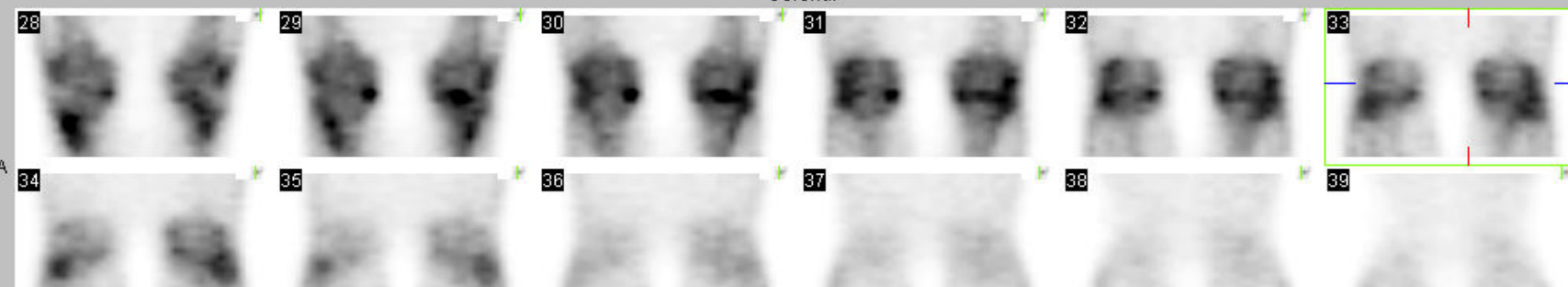
Transverse



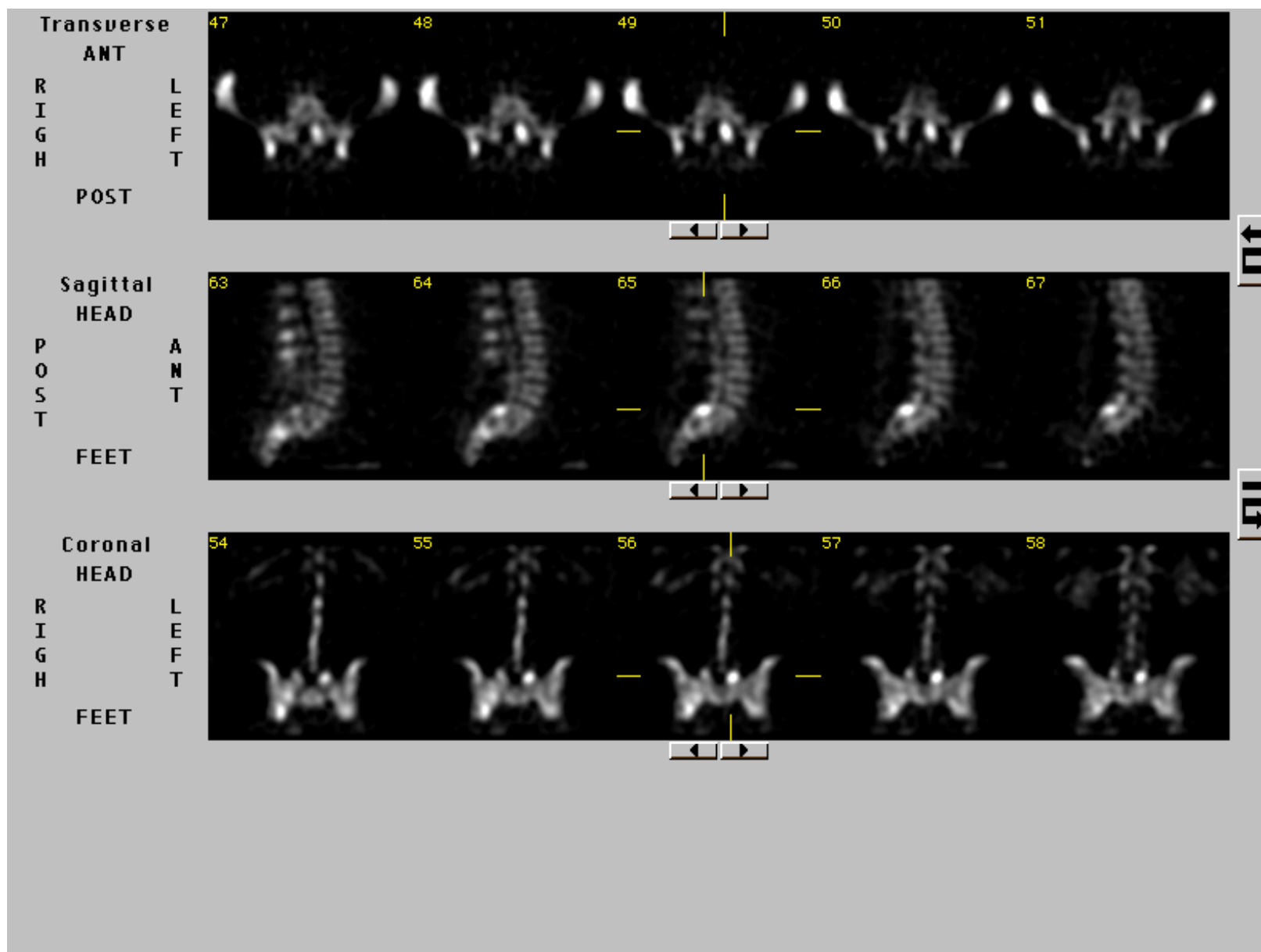
Sagittal

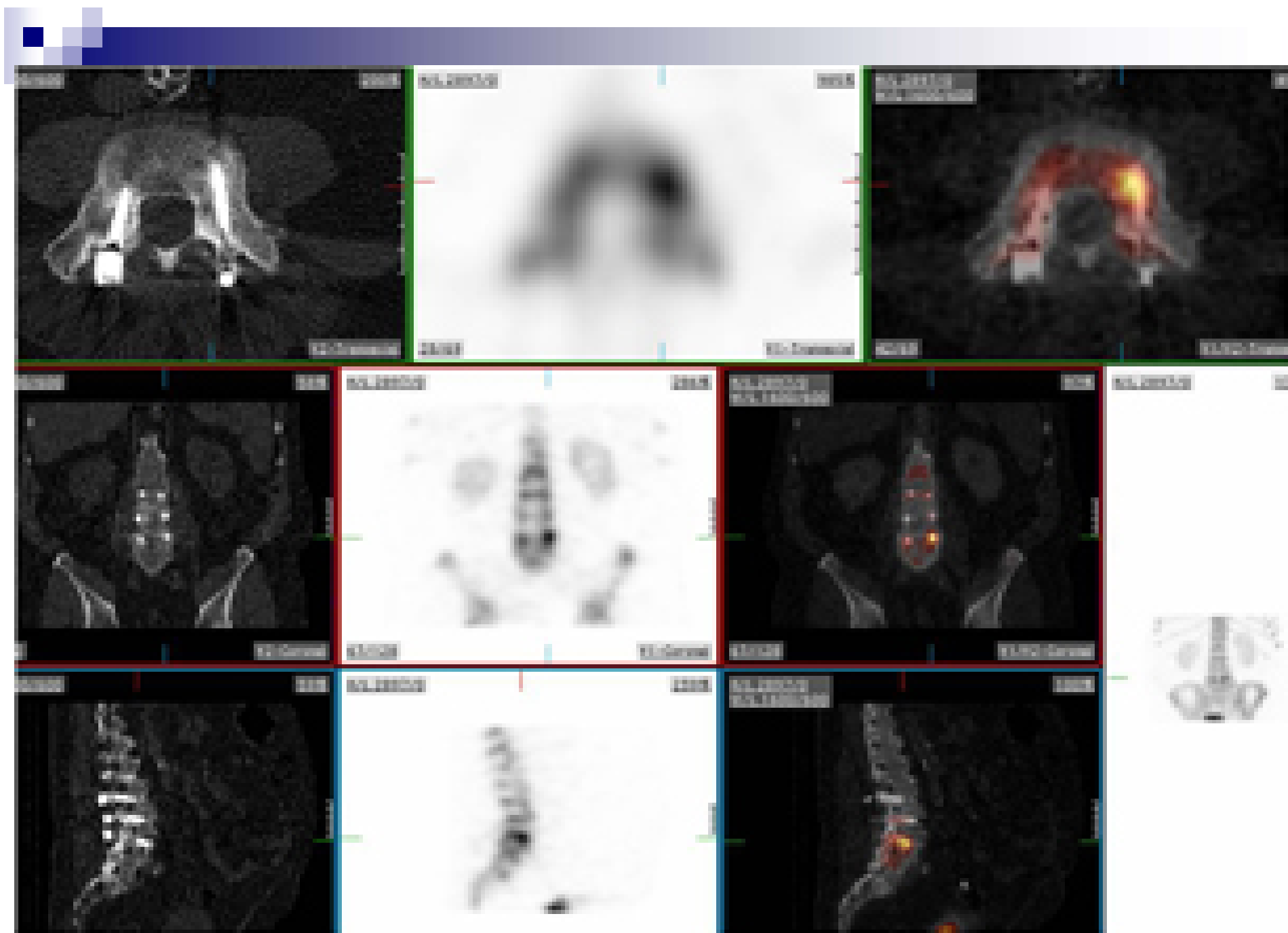


Coronal









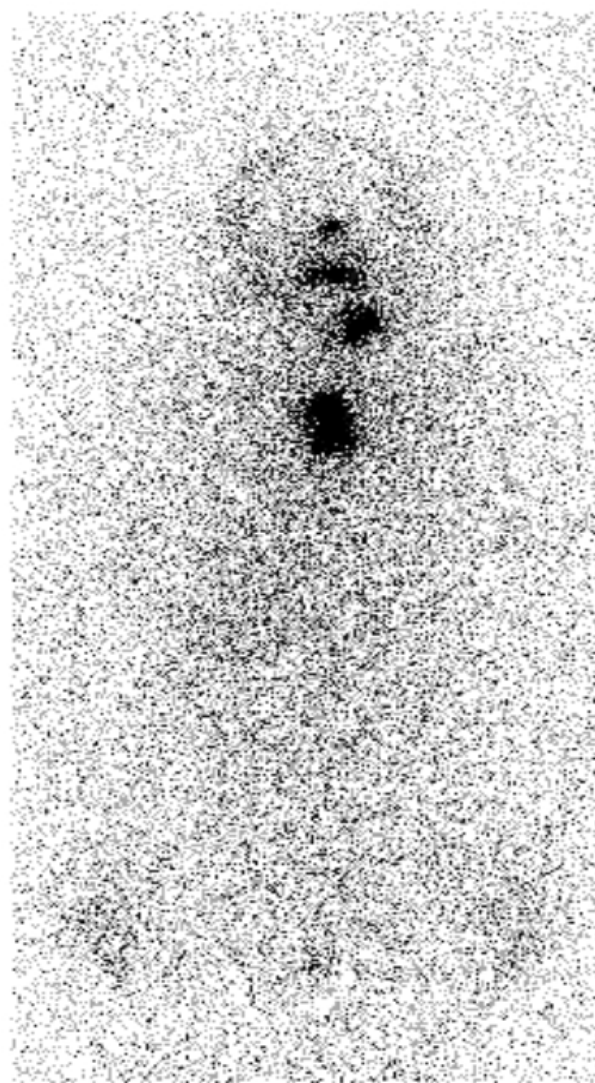
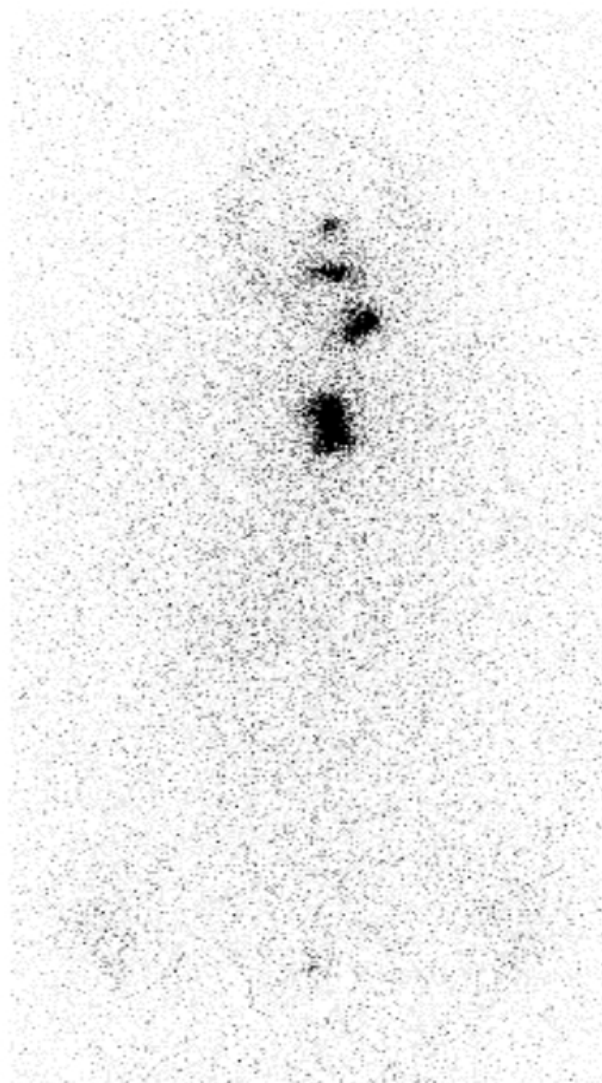


Patient Name: josifoska, dobrica

Patient ID: 13665

Study Date: 04.03.2011

Study Time: 08:37:24





# SPECT/CT

- SPECT principles
- Iterative SPECT reconstruction
- Advantage of SPECT/CT hybrid imaging
- Current clinical applications of SPECT/CT





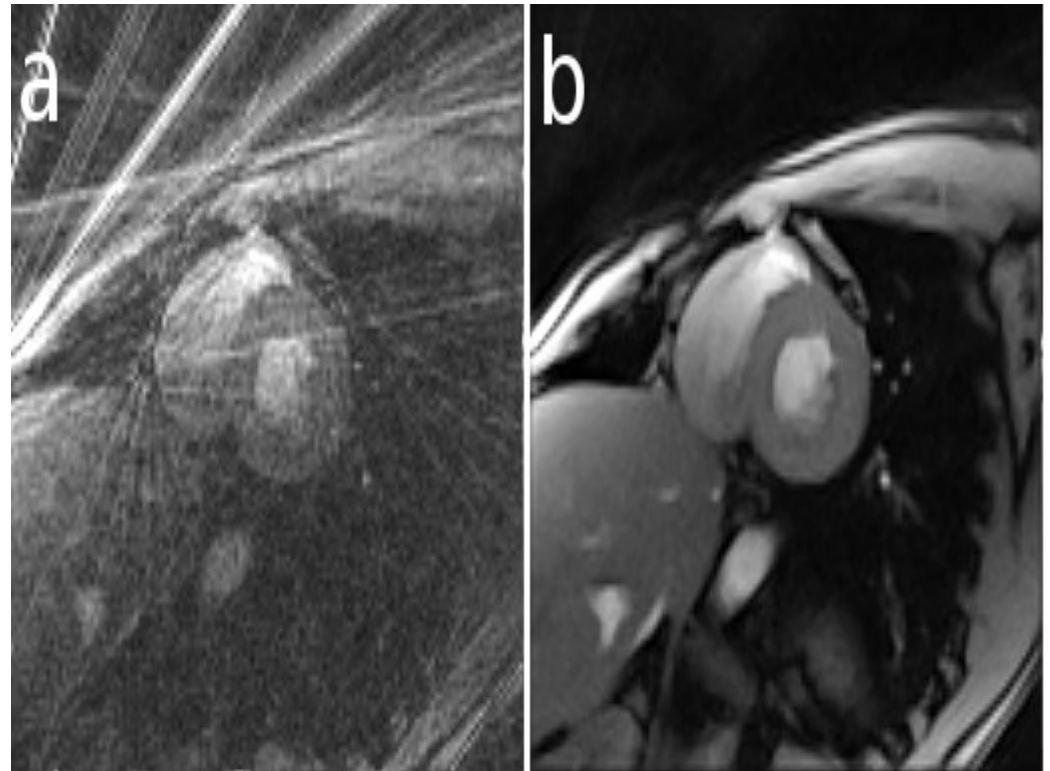
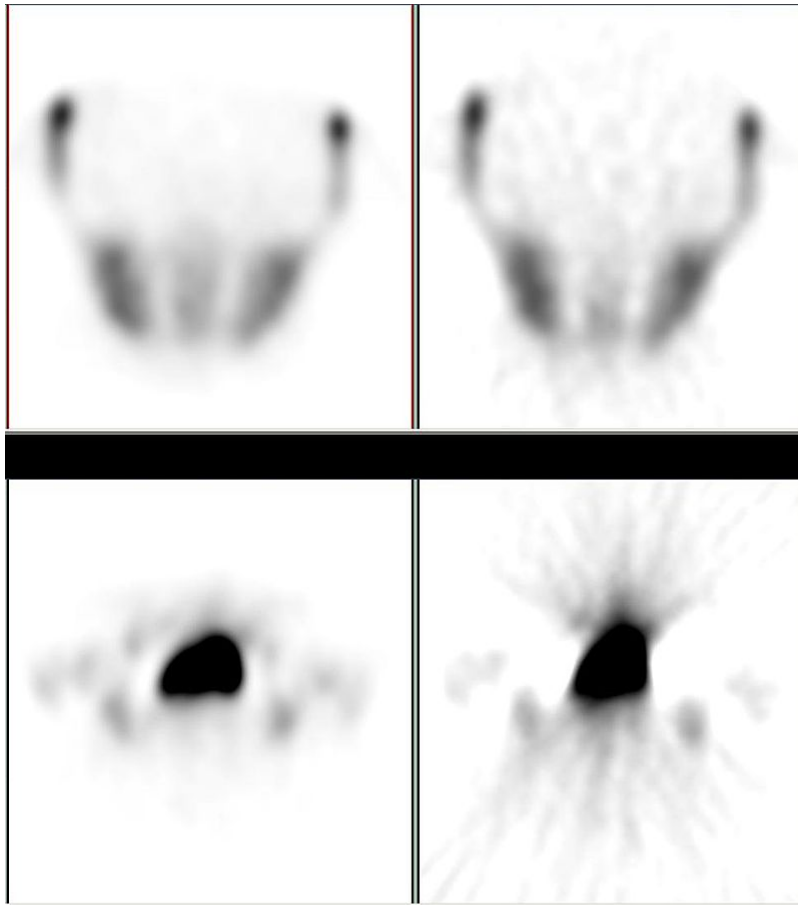
# SPECT principles

- Flat panel *head* used for detection
- Acquisition time depending on
  - detector, collimator
  - size of the imaging region
  - amount of activity available

**Data Acquisition** - low energy  
all purpose collimator/high  
resolution; 30sec/projection in  
64 projections over 360  
degrees on single-headed  
gamma camera

- acquisition processing
- uniformity correction
- filtered backprojection

# Iterative reconstruction / filtered back projection





## Dual Isotope Imaging with SPECT

- Bone scan with  $^{99m}\text{Tc}$ -MDP and Thyroid imaging with  $^{123}\text{I}$ /thyroid and parathyroid imaging
- $^{99m}\text{Tc}$  (140.5 keV)
- $^{123}\text{I}$  (159.0 keV)

Energy window ( $^{99m}\text{Tc}$ )

140 keV

Energy window ( $^{123}\text{I}$ )

160 keV

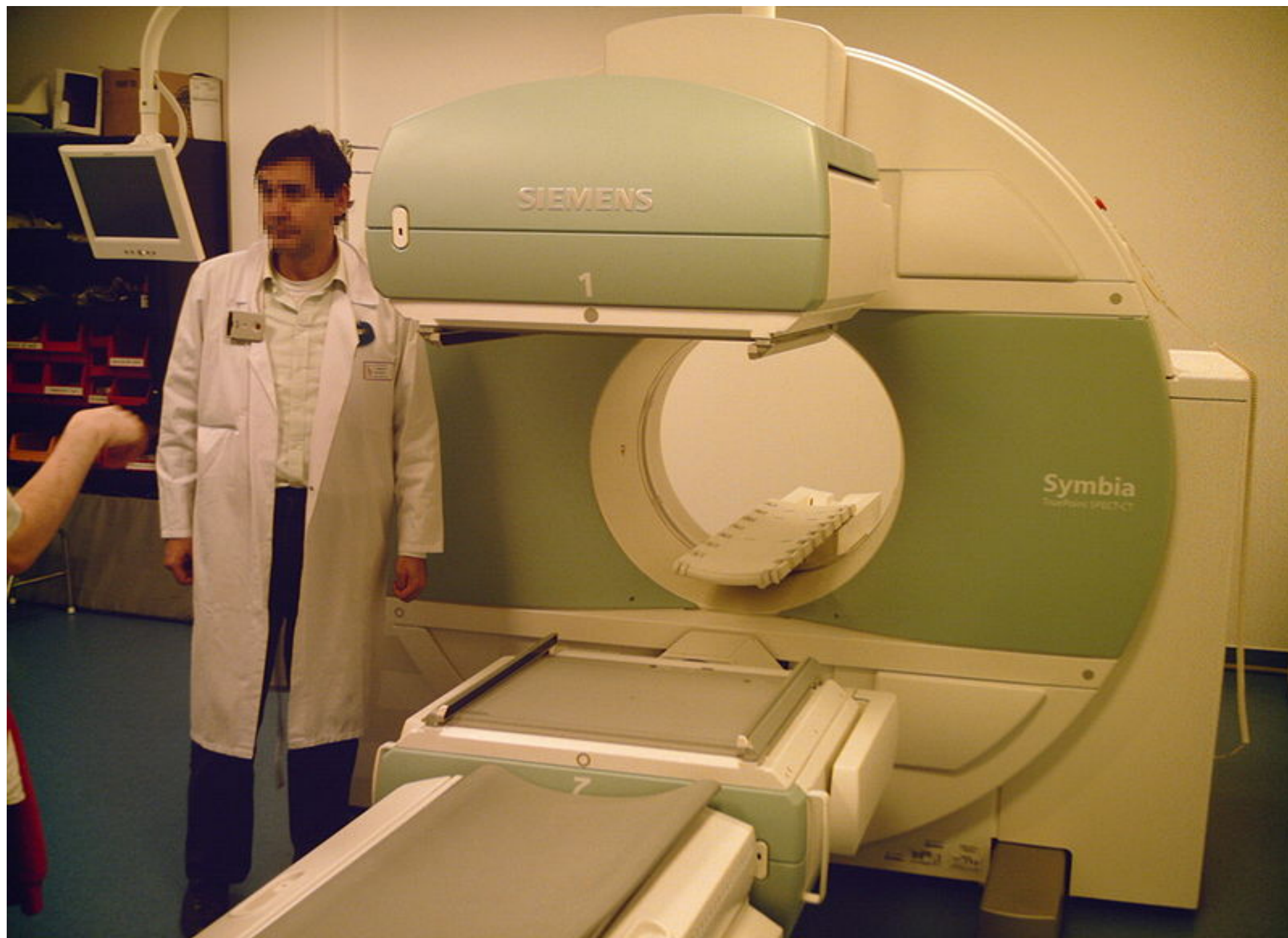

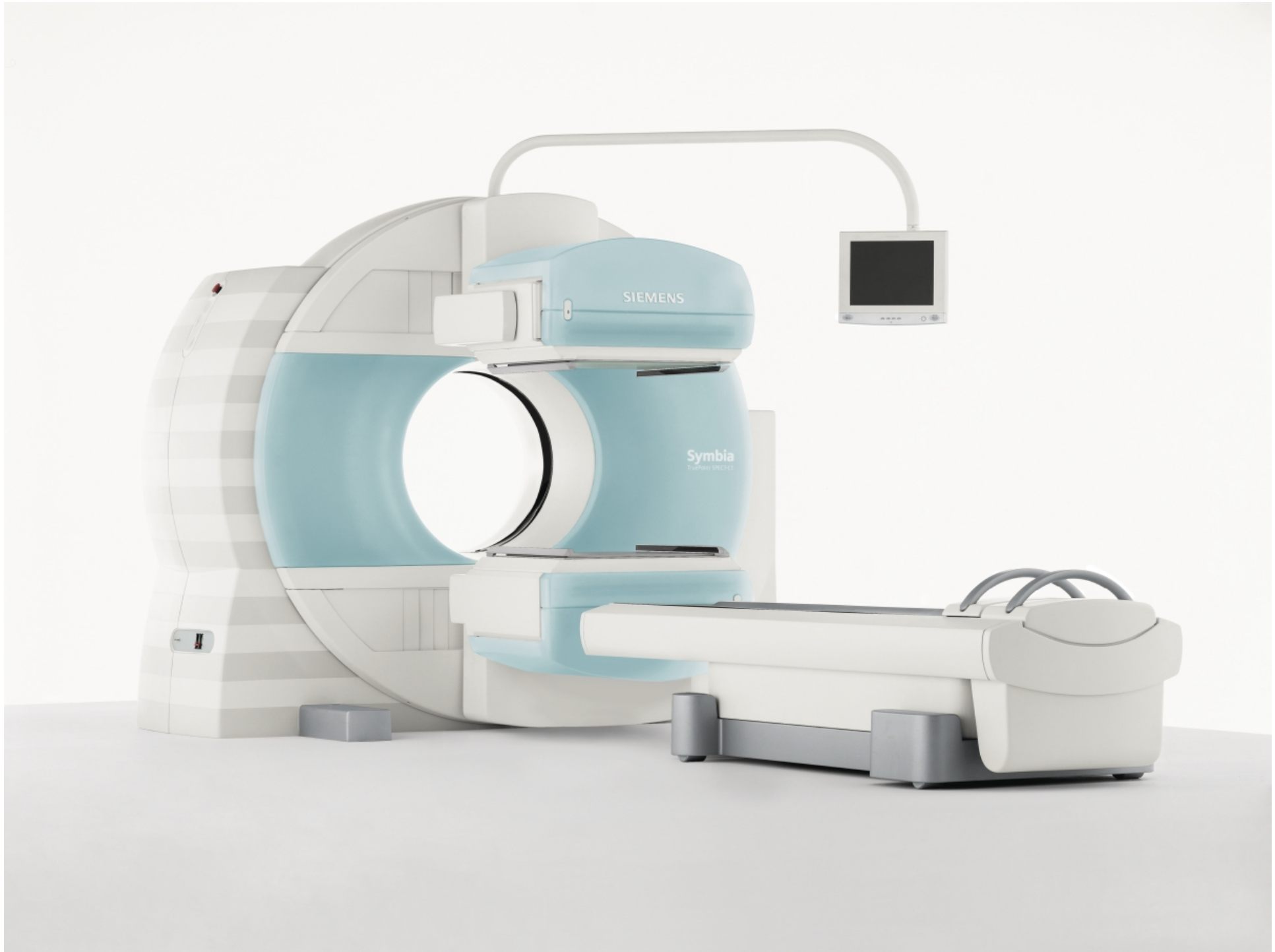# SPECT radionuclides

- $^{99m}\text{Tc}$   $T_{1/2} = 6 \text{ hr}$ ,  $\gamma = 140 \text{ keV}$
- $^{111}\text{In}$   $T_{1/2} = 67 \text{ hr}$ ;  $\gamma$ 's = 172, 245 keV
- $^{123}\text{I}$   $T_{1/2} = 13 \text{ hr}$ ,  $\gamma = 159 \text{ keV}$
- $^{67}\text{Ga}$   $T_{1/2} = 78 \text{ hr}$ ;  $\gamma$ 's = 93, 184, 296 keV
- $^{201}\text{Tl}$   $T_{1/2} = 73 \text{ hr}$ , 70 keV X-rays,  $\gamma = 167 \text{ keV}$
- $^{131}\text{I}$   $T_{1/2} = 193 \text{ hr}$ ,  $\gamma = 364 \text{ keV}^*$
- $^{153}\text{Sm}$   $T_{1/2} = 46 \text{ hr}$ ,  $\gamma = 103 \text{ keV}^*$

\* used for internal therapy ( $\beta^-$ ) as well!!!



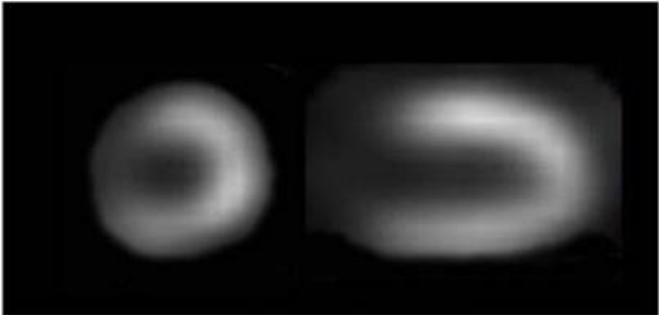
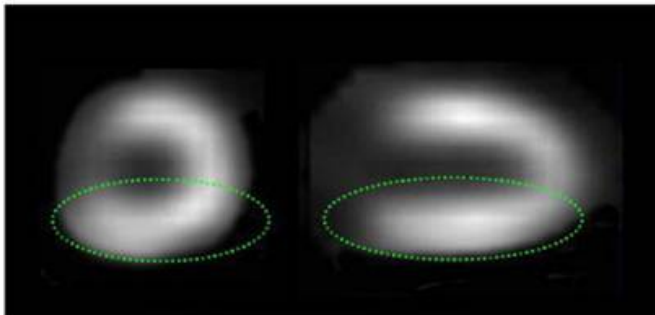

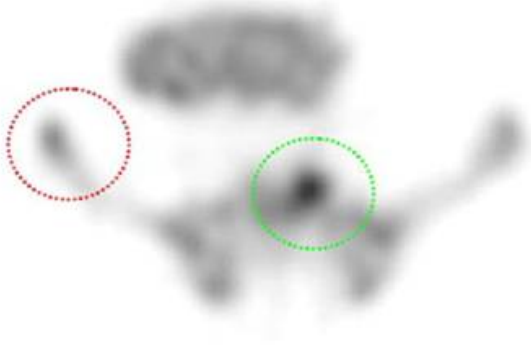

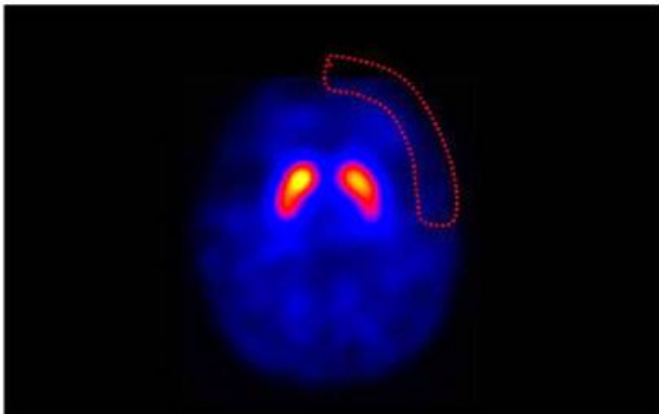






# BENEFITS OF FUSION IMAGING

- Increased sensitivity and specificity
- Precise anatomic localization of findings seen in nuclear imaging
- Identify normal physiologic activity which can be misinterpreted as disease
- Patient convenience. Eliminates need for multi-day imaging protocol

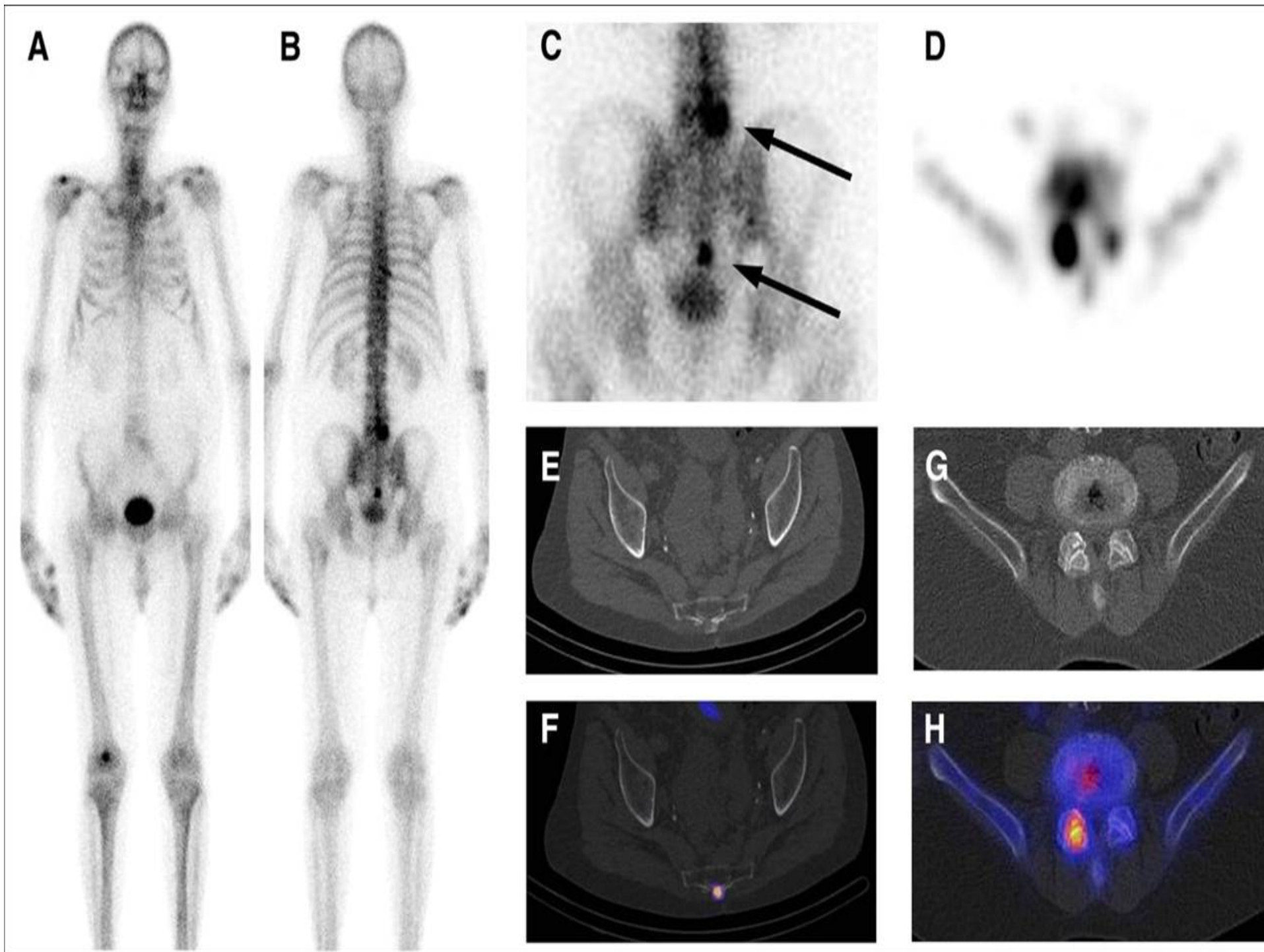
	without CT attenuation correction	with CT attenuation correction
cardiac		
skeletal		
brain		





# **MAIN INDICATIONS FOR SPECT/CT**

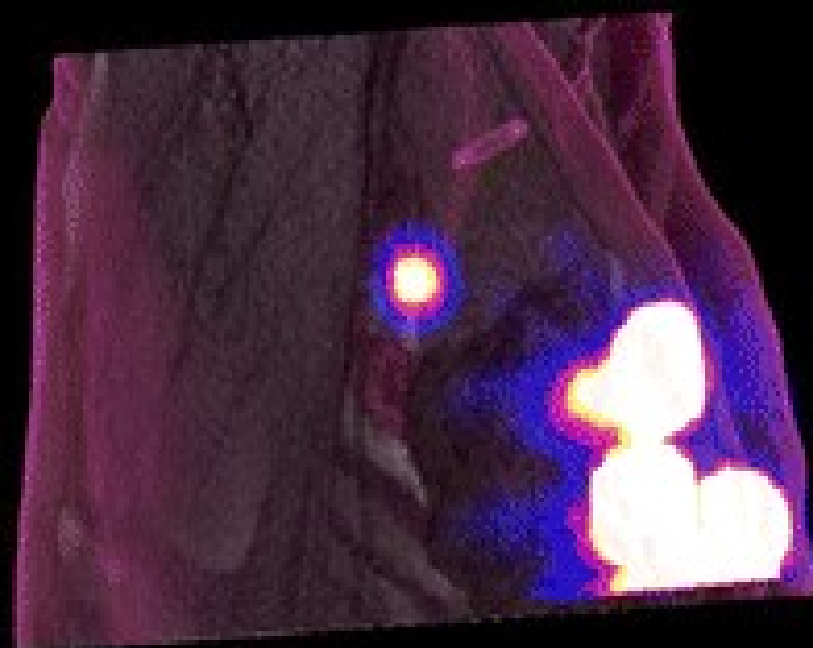
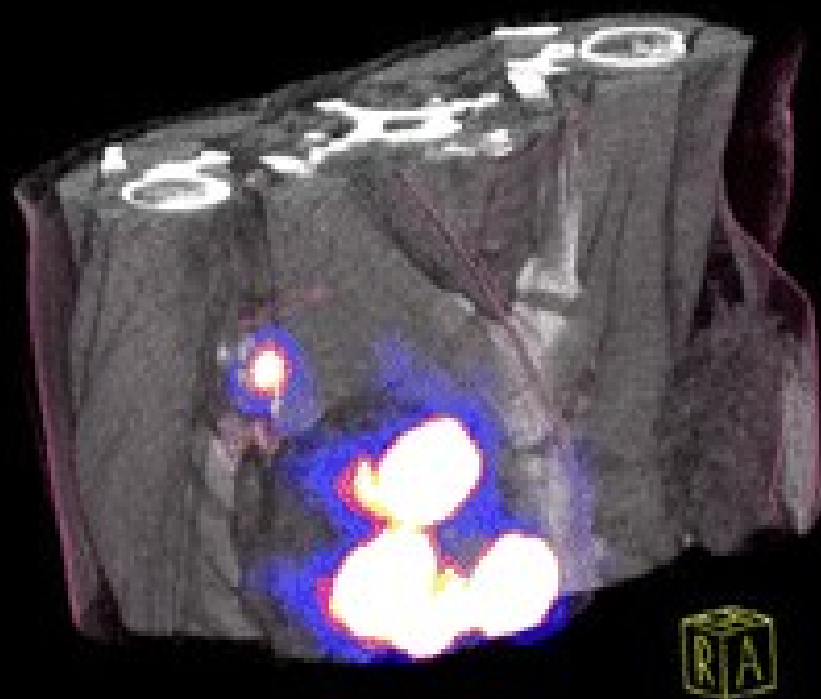
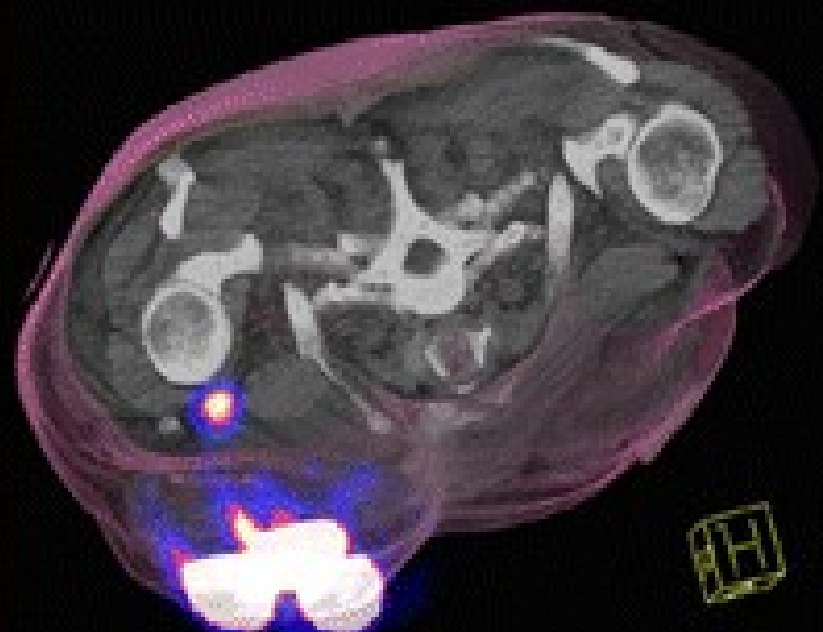
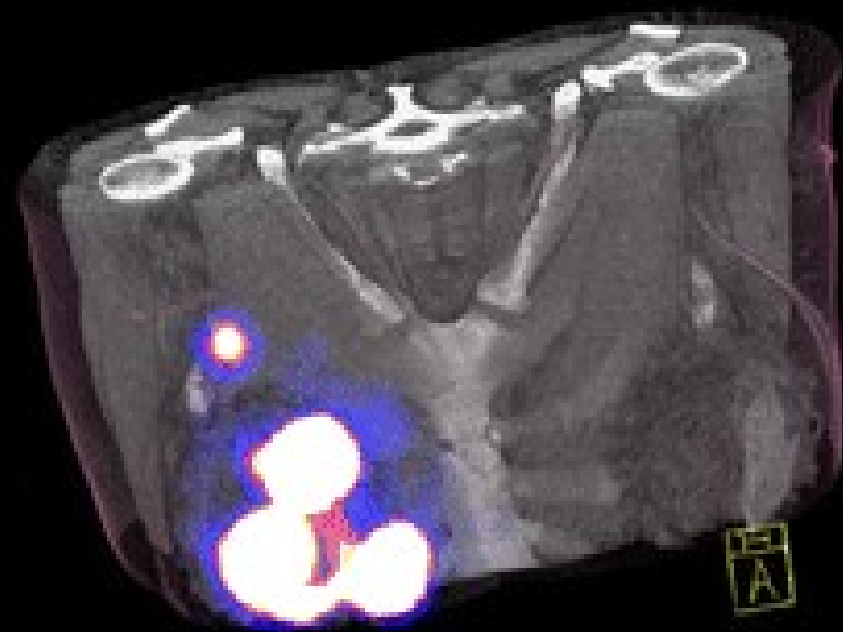
- Bone Scanning
- Graft Infections
- Cardiac Imaging
- Parathyroid Imaging
- Lymphoscintigraphy
- Tumor and mass localization
- Patients with abdominal pain
- Thyroid Cancer Staging



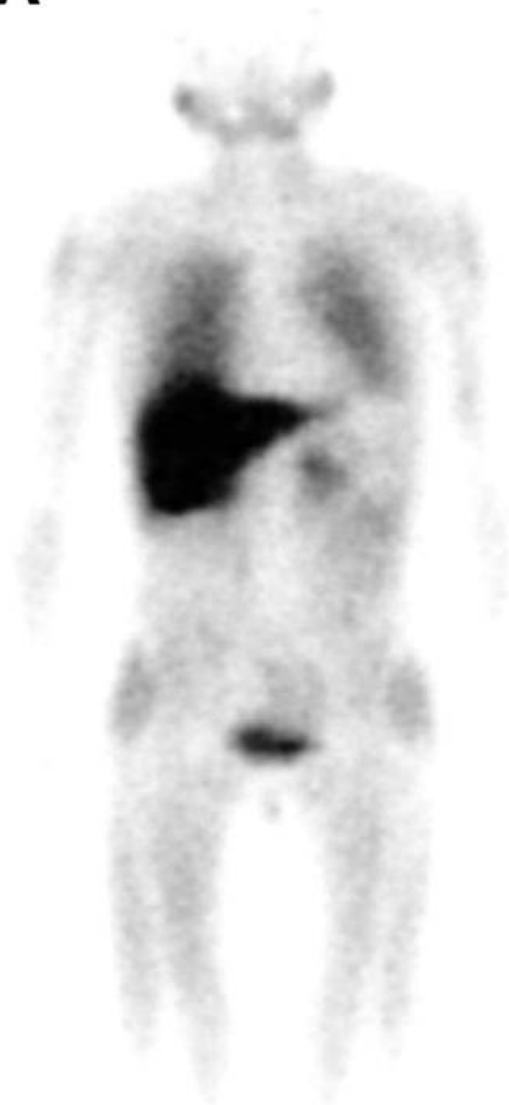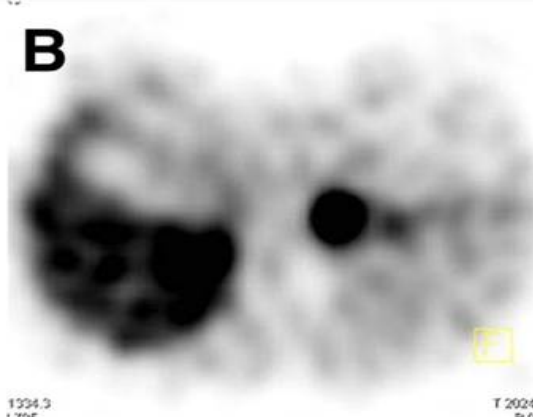
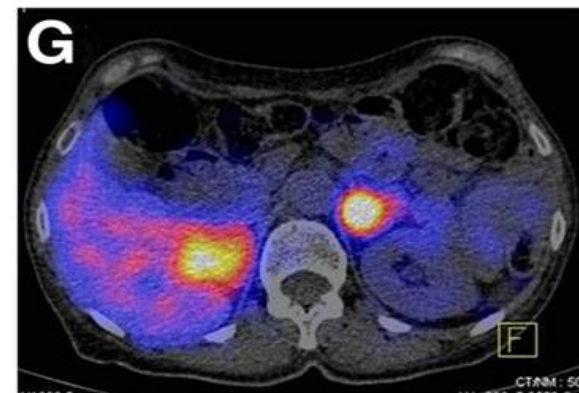
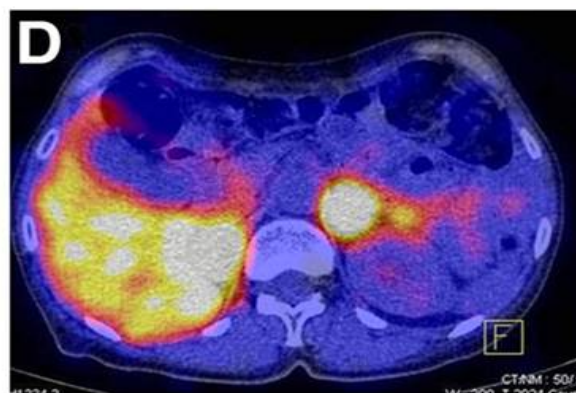
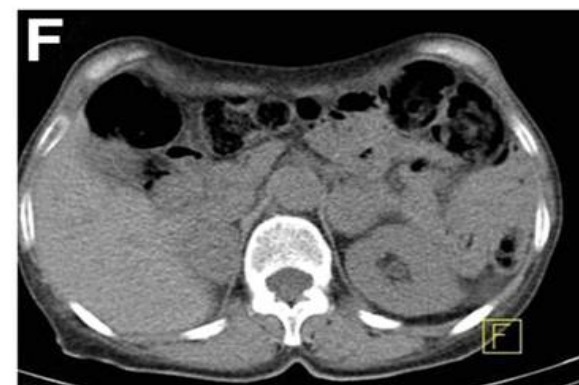
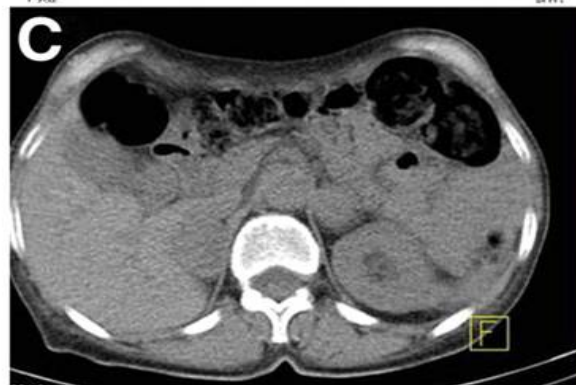
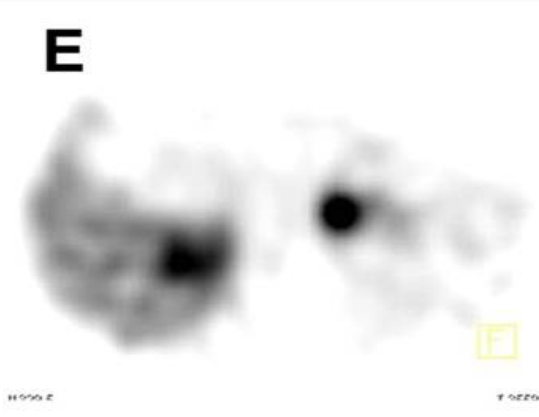


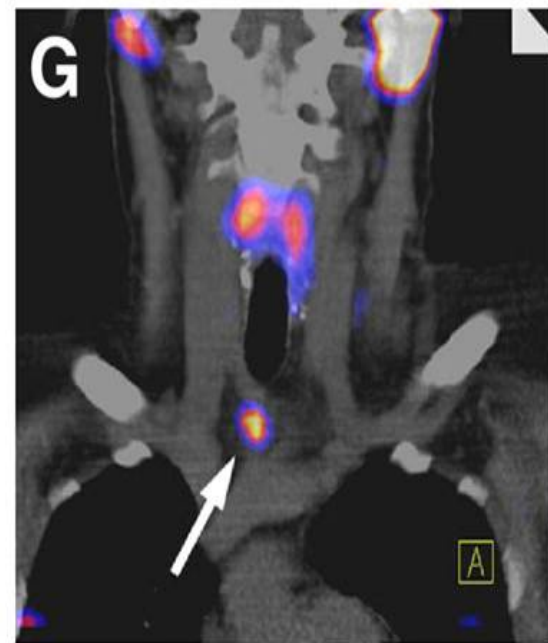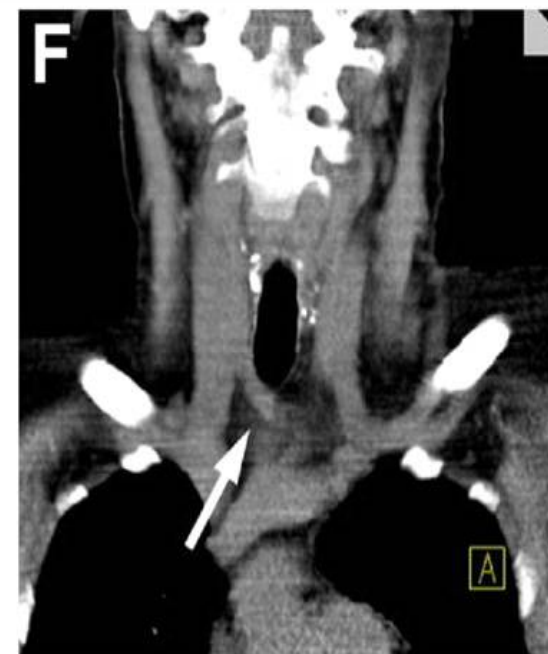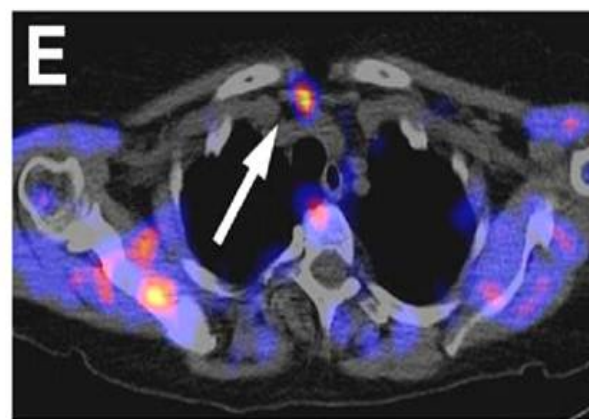
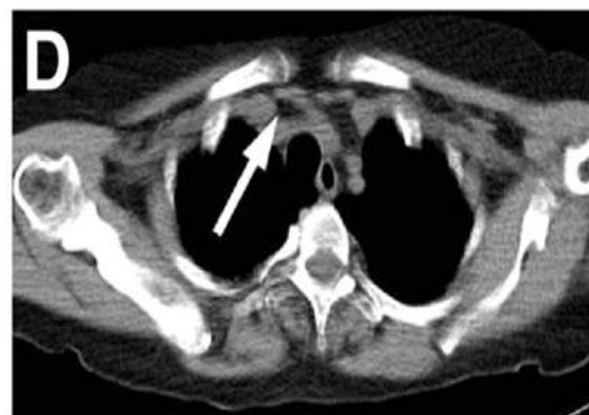
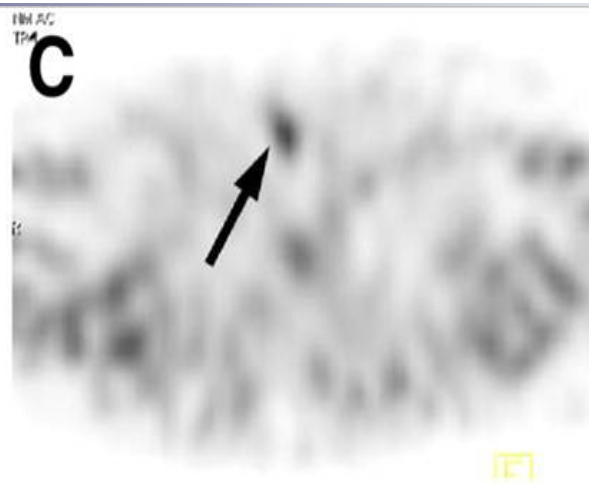
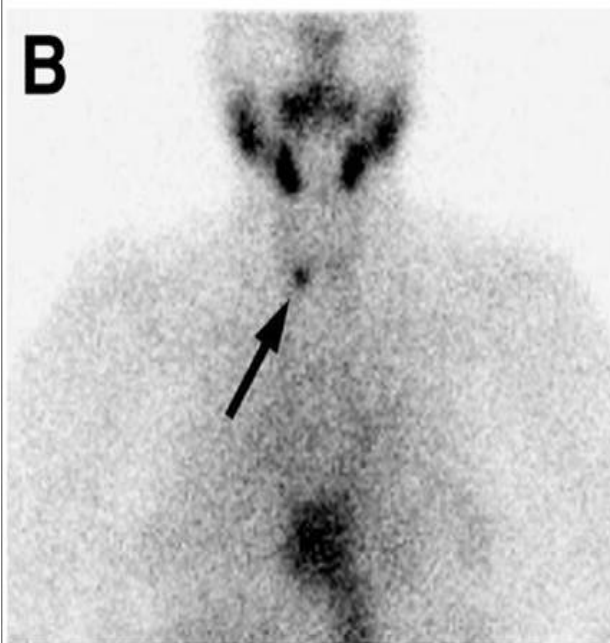
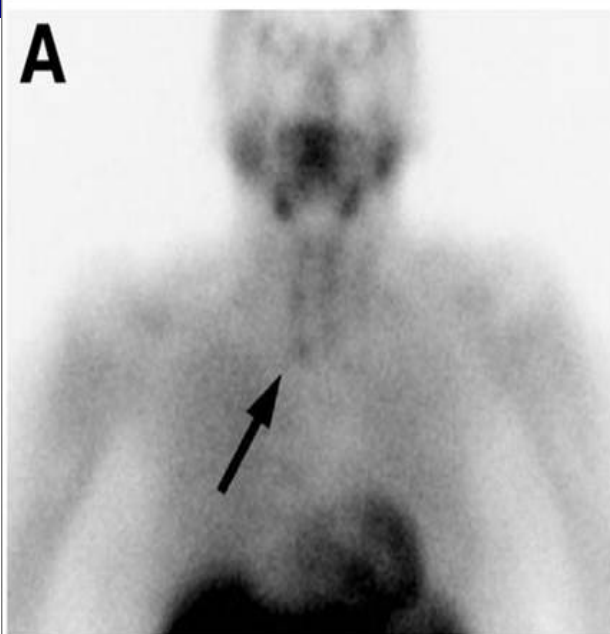
# BONE SCANS

- Highly sensitive, but not often specific
- Benign processes can simulate malignancy
- Neoplastic lesions may occur in distribution suggestive of arthritic change
- Soft tissue abnormalities are usually not detected on routine bone scanning

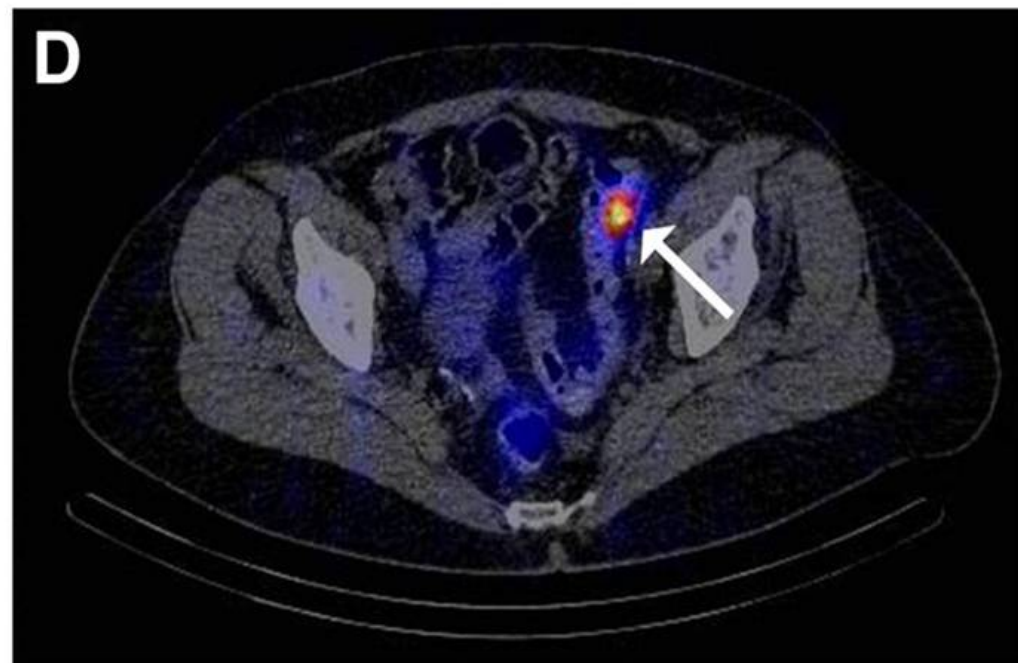
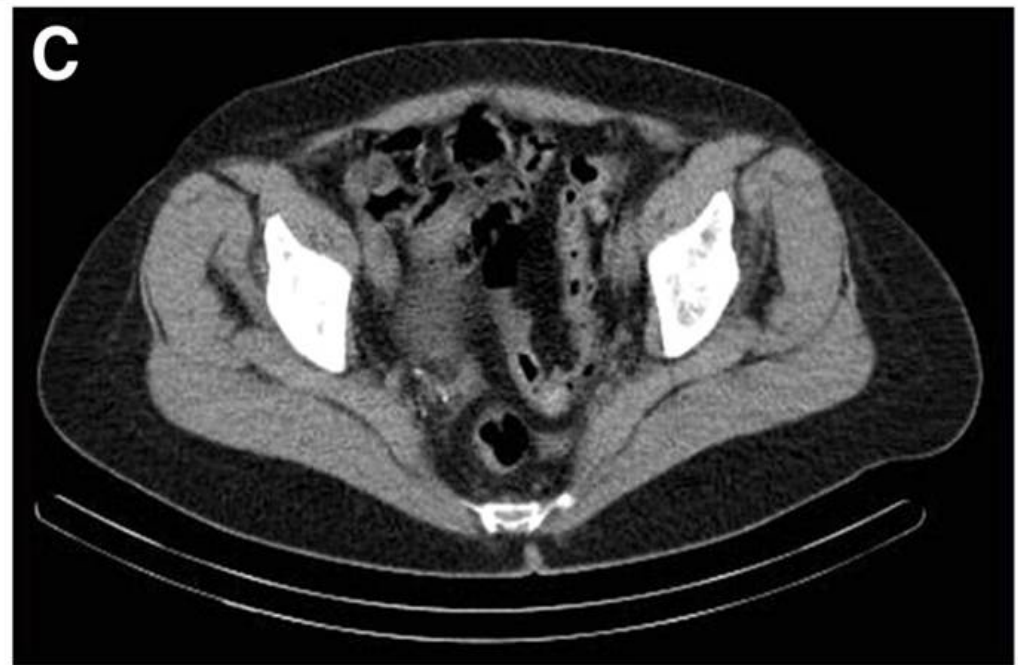
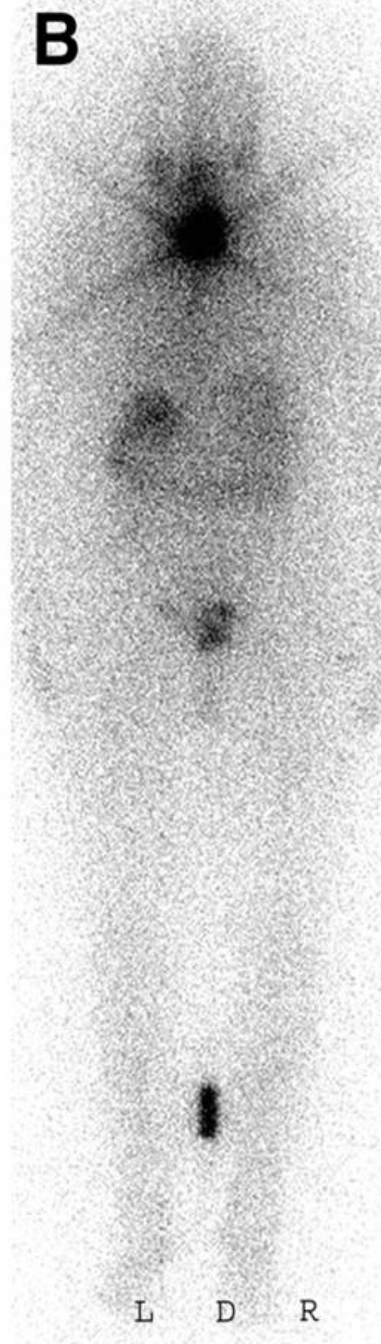
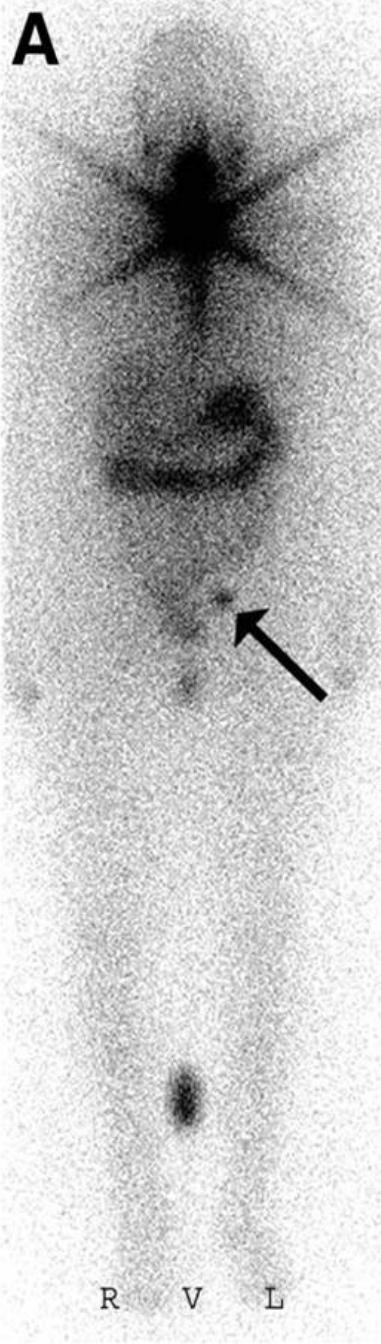




**A****B****E**











Sarajevo Mai 2012

La physique des particules élémentaires,  
au LHC, l'expérience CMS,  
les recherches en cours.

D. Denegri  
CE Saclay, IRFU/SPP, France











THANK YOU. ENJOY THE CONFERENCE!

