



***RADIATION ONCOLOGY:
BIOLOGY & PHYSICS;
CLINICAL APPLICATIONS***

Raymond Miralbell

Radiation Oncology


University Hospital, Geneva &

Instituto Oncológico Teknon, Barcelona

INTRODUCTION

Radiation Oncology is Based on...

- **Clinical Oncology**
- **Medical Physics**
- **Imaging/Technology**
- **Radiobiology**



Treatment

Present Status of Radiotherapy

- After surgery, radiotherapy (RT) is the most effective cancer treatment.
- Around 40% of the population will develop cancer and 60% will require RT.
- Of patients having RT, 60-70% are treated with curative intent.

Trends in 5-Year Survival for Adult Cancer Patients in the US (1975-2010)

Tumor site	1975-77	2004-2010
Prostate (male)	68%	>99%
Breast (female)	75%	91%
Rectum	48%	68%
Lung	12%	18%

(Cancer Statistics. American Cancer Society 2015)

Trends in 5-Year Survival for Pediatric Cancer Patients (<15 yr-old males) in the US (1975-2010)

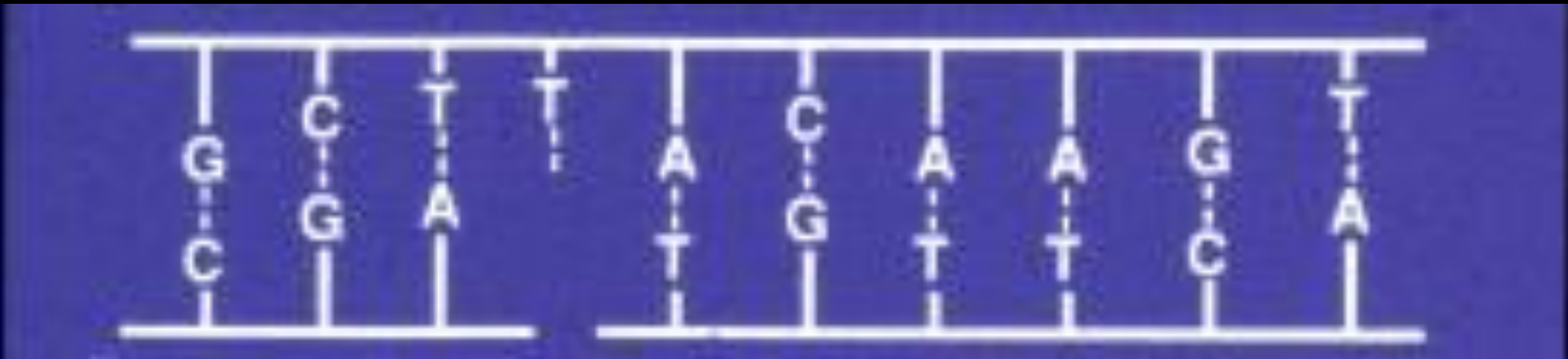

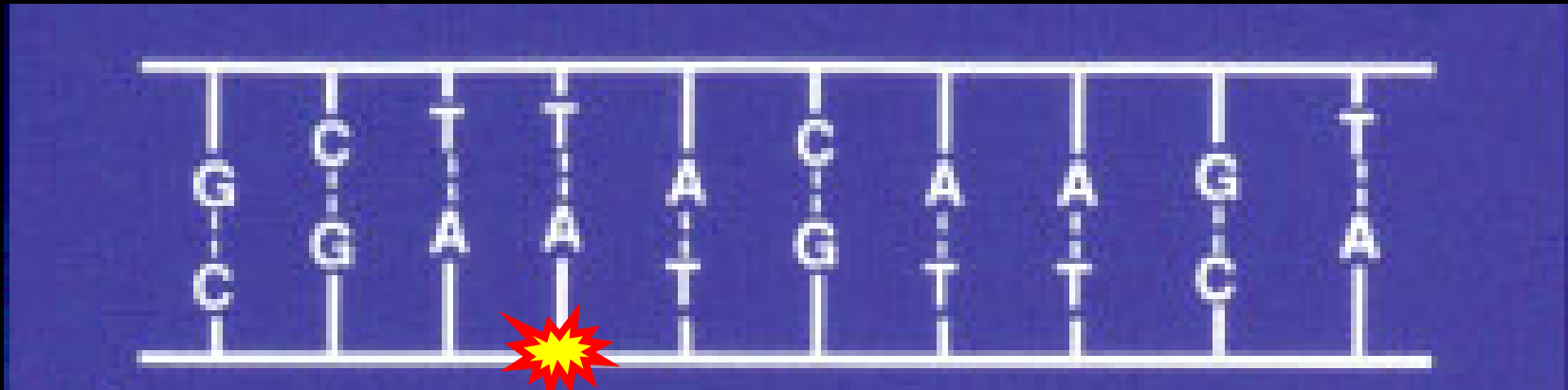
Tumor site	1975-77	2004-2010
CNS	57%	74%
Soft tiss. sarcoma	61%	81%
Hodgkin	81%	98%
All sites	58%	83%

(Cancer Statistics. American Cancer Society 2015)

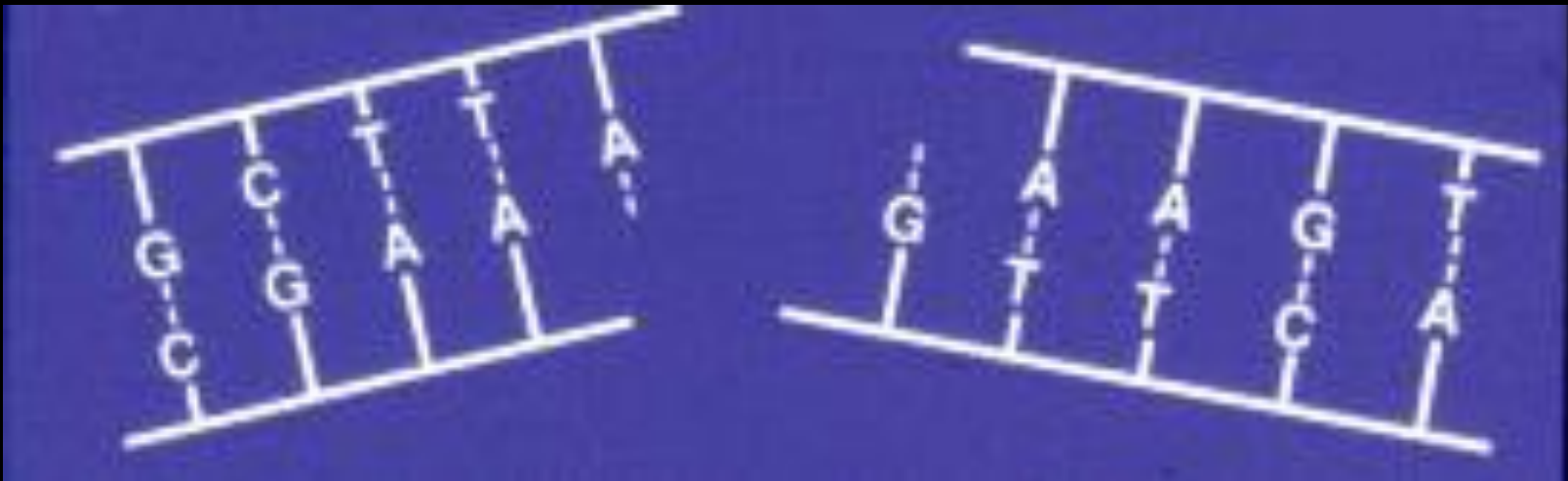


BIOLOGY

Cell killing effect

- Radiation interacts with DNA: DNA breaks.
- DNA breaks trigger cellular repair actions.
- DNA double strand breaks may lead to cell-kill.



Single strand break



Double strand break

PHYSICS

RT Modalities

- External RT:
Radiation source outside the patient
(radiation beams: *X-rays, e^- , H^+ ,...*)
- Brachytherapy:
Radiation source inside the patient (*Ir, Cs, I, Au, Pd,...*)

Standard Dose Parameters

- *Standard fractionation:*
1.8-2 Gy/fraction; 1x day; 5 days/week.
- *Total dose:*

low	(20-30 Gy):	seminoma, Hodgkin,...
medium	(45-55 Gy):	subclinical disease,...
high	(65-80 Gy):	prostate, sarcoma,...


Present Limitation of RT

$1/3$ of patients still fail
locally after curative intent RT

How to overcome post RT Failures?

- State of the art equipment & high quality imaging
- Quality assurance programs
- Biology: altered fractionation, sensitizers,...
- **Improve dose distribution: dose escalation**

**To improve dose distribution in
order to safely escalate the dose**

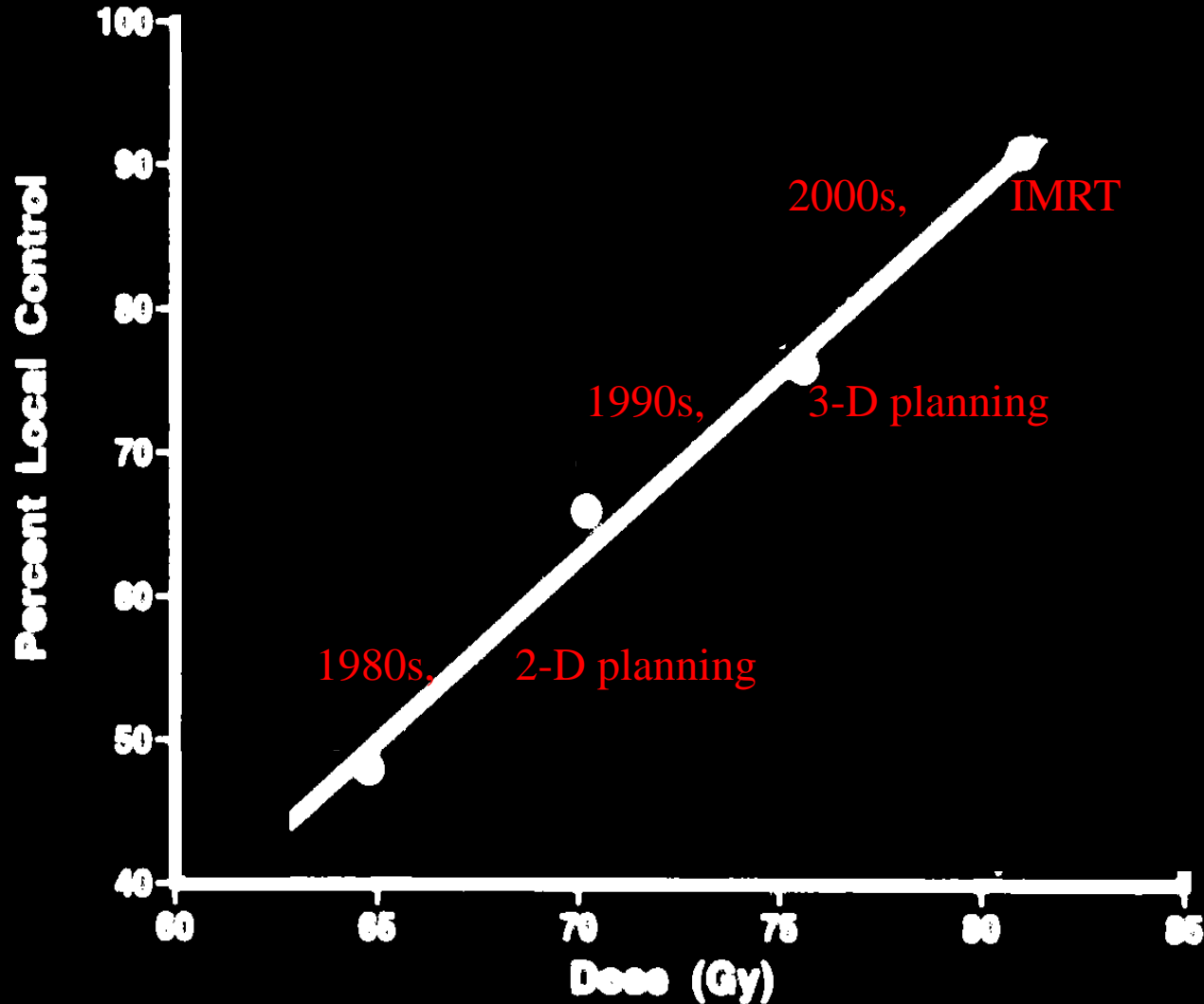


3-D conformal RT

Dose escalation studies

- **Prostate**
- **CNS**
- **Base of skull & paranasal sinus**
- **Non-extremity soft tissue sarcomas**

Local control vs. dose: the influence of «physics, technology, and imaging»

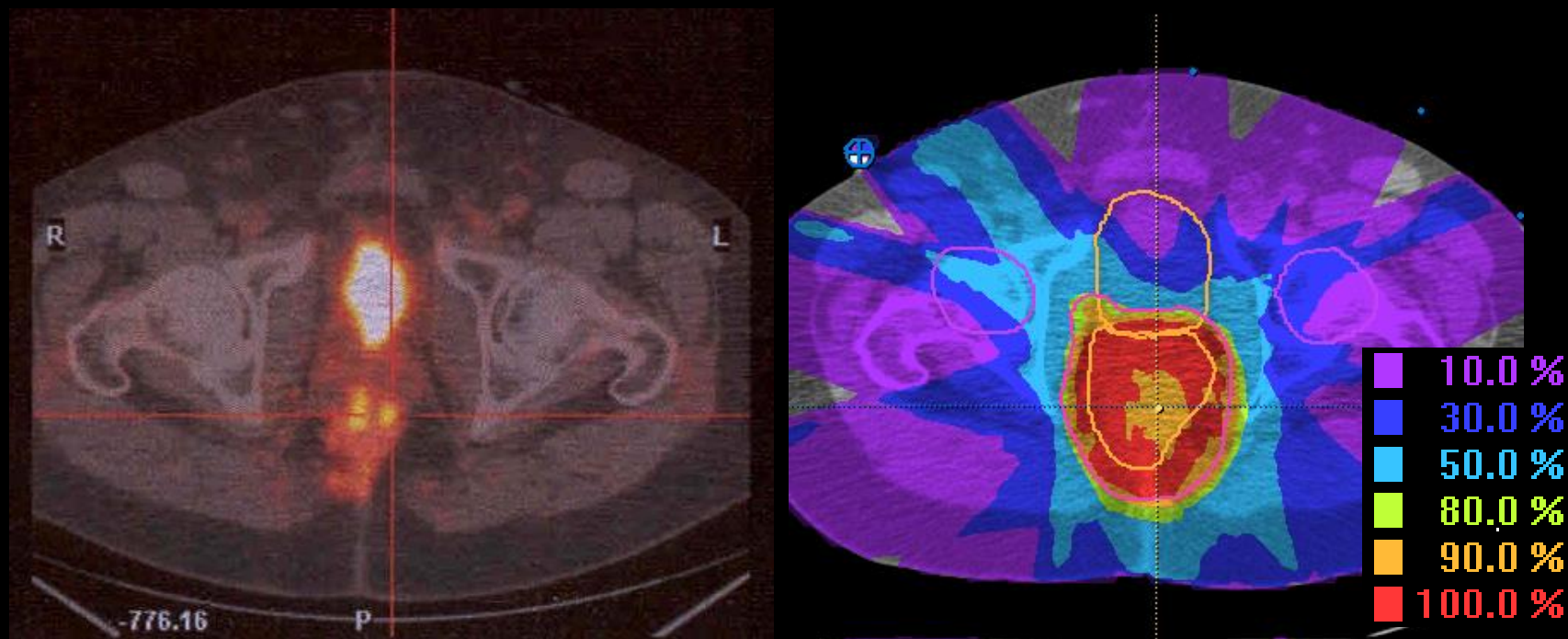


Treatment optimization

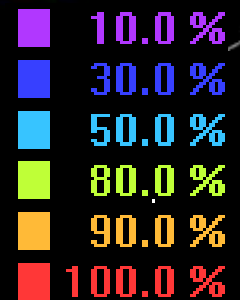
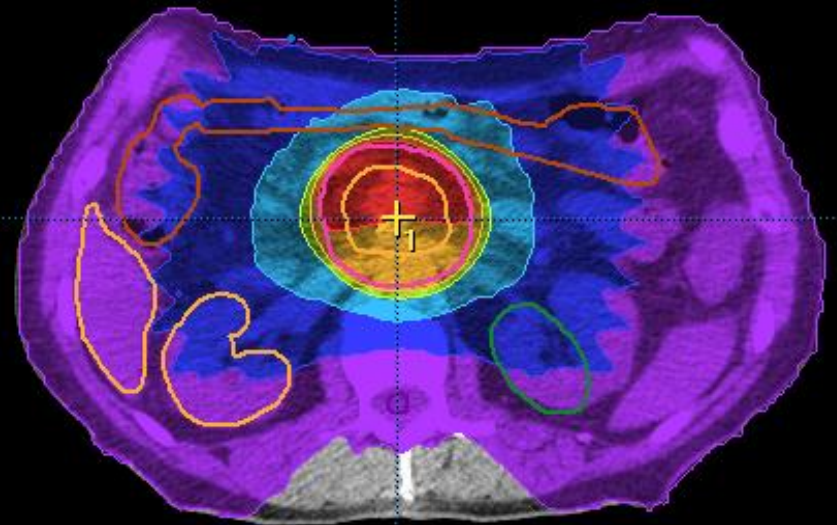
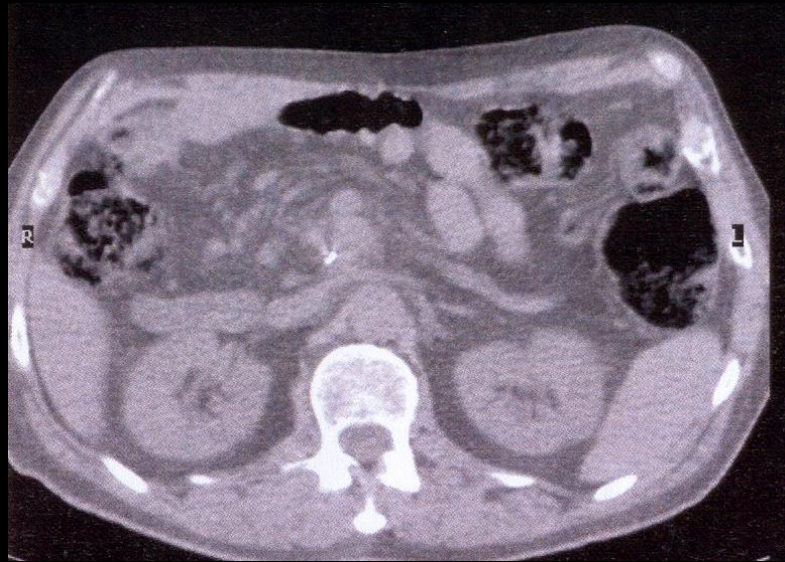- Imaging (CT, MRI, PET) and IGRT (image guided RT)
- Treatment planning systems: 3-D dosimetry
- Intensity Modulated RT (& inverse planning)
- Protons: in depth conformation

**Convergence of imaging
&
accuracy in treatment planning**

^{18}F -deoxyglucose PET for rectal cancer: postsurgical local relapse

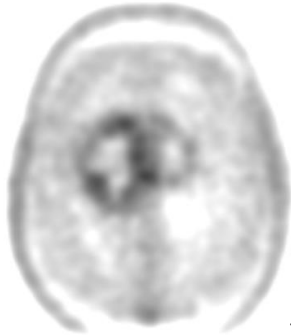


^{18}F -deoxyglucose PET for pancreatic cancer: postsurgical residual disease

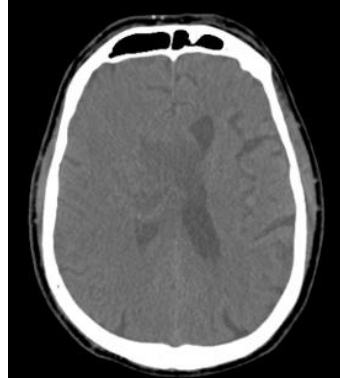


PET imaging

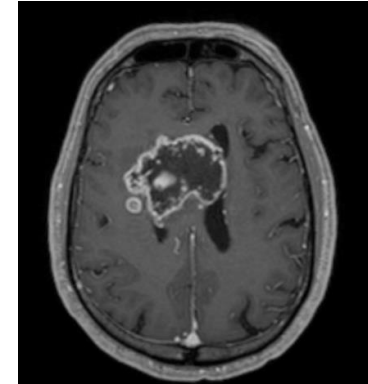
F18 - Tyrosine (FET)



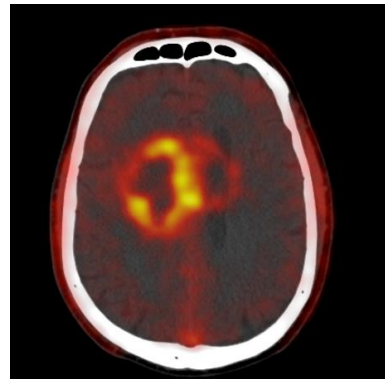
PET




CT



MRI



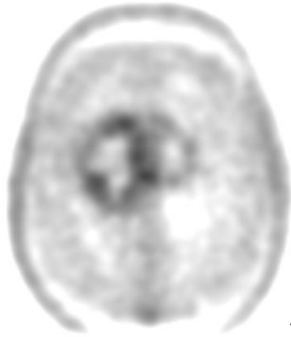
PET-CT



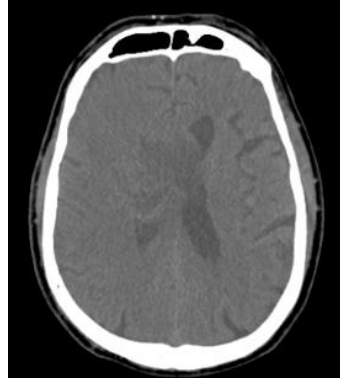
Applications: - Brain tumours (glioblastoma)

PET imaging

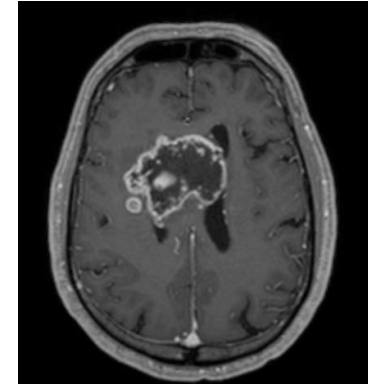
F18 - Tyrosine (FET)



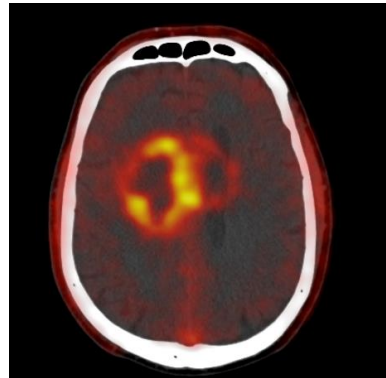
PET



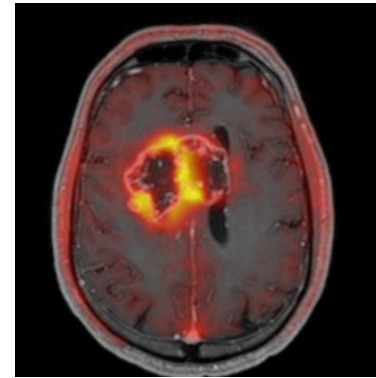
CT



MRI



PET-CT



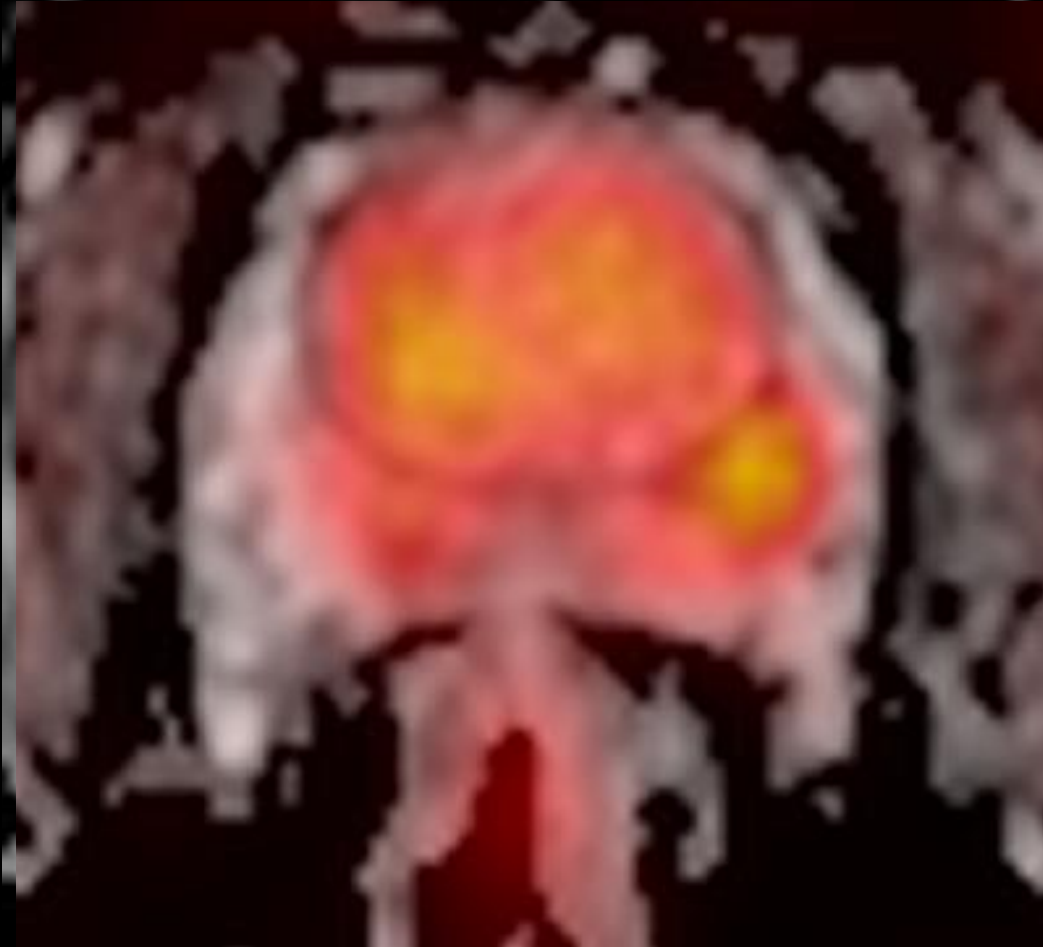
PET-MRI

Applications: - Brain tumours (glioblastoma)

PET-MRI in Geneva

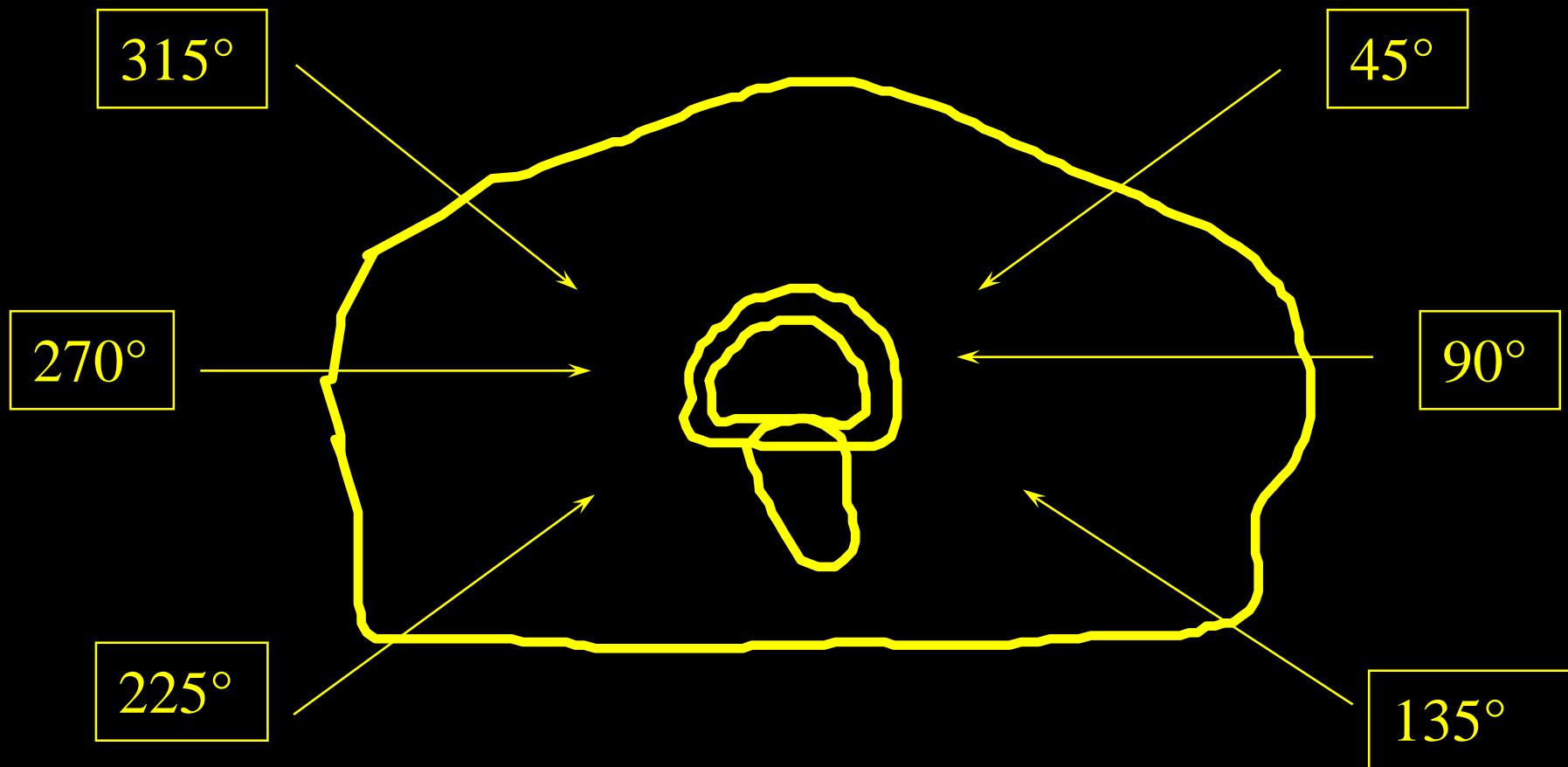


PET-IRM (water diffusion/choline)



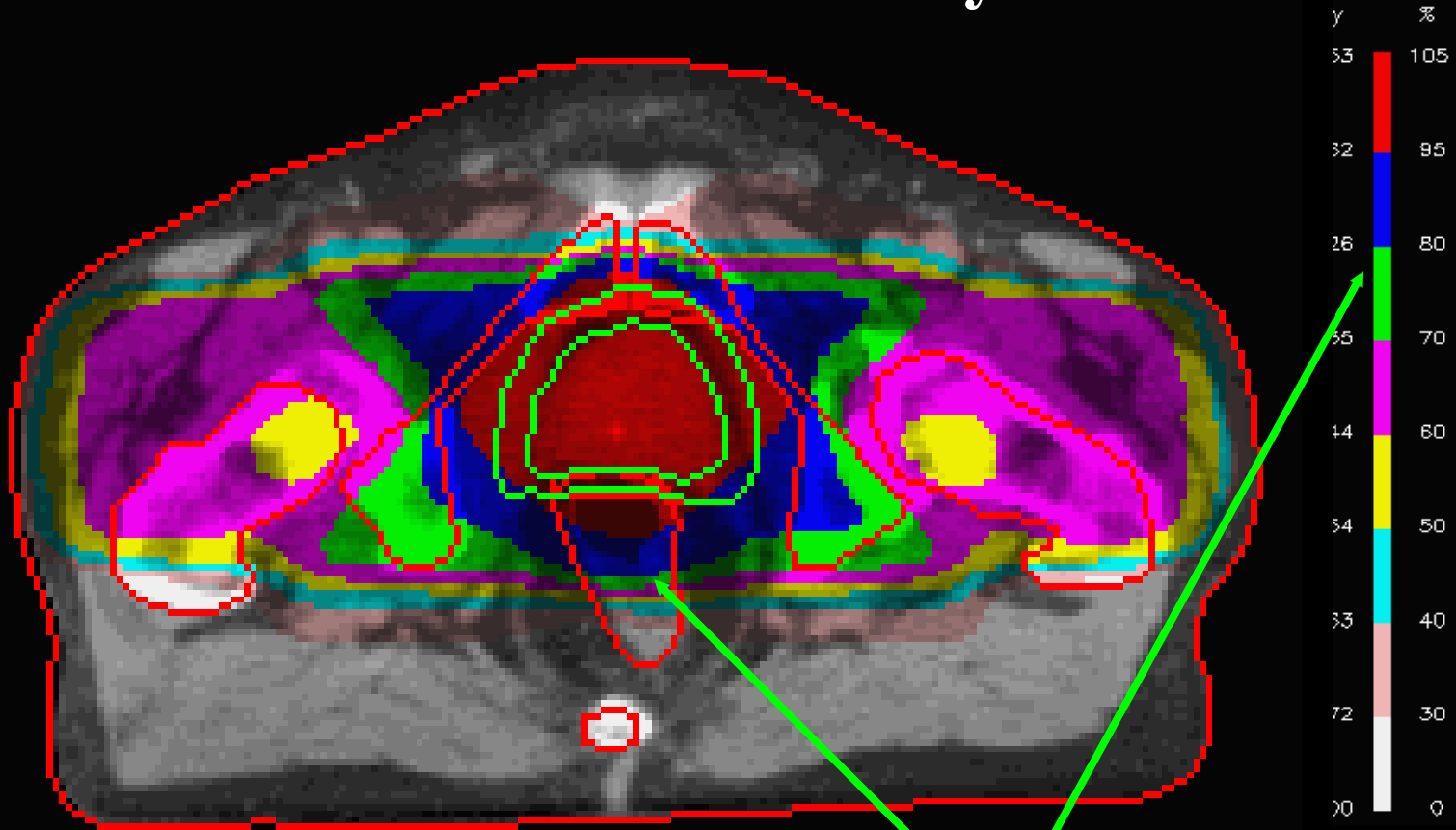
3-D conformal radiotherapy (forward planned)

X-rays



Prostate (100%: 81 Gy)

3-D conformal X-rays



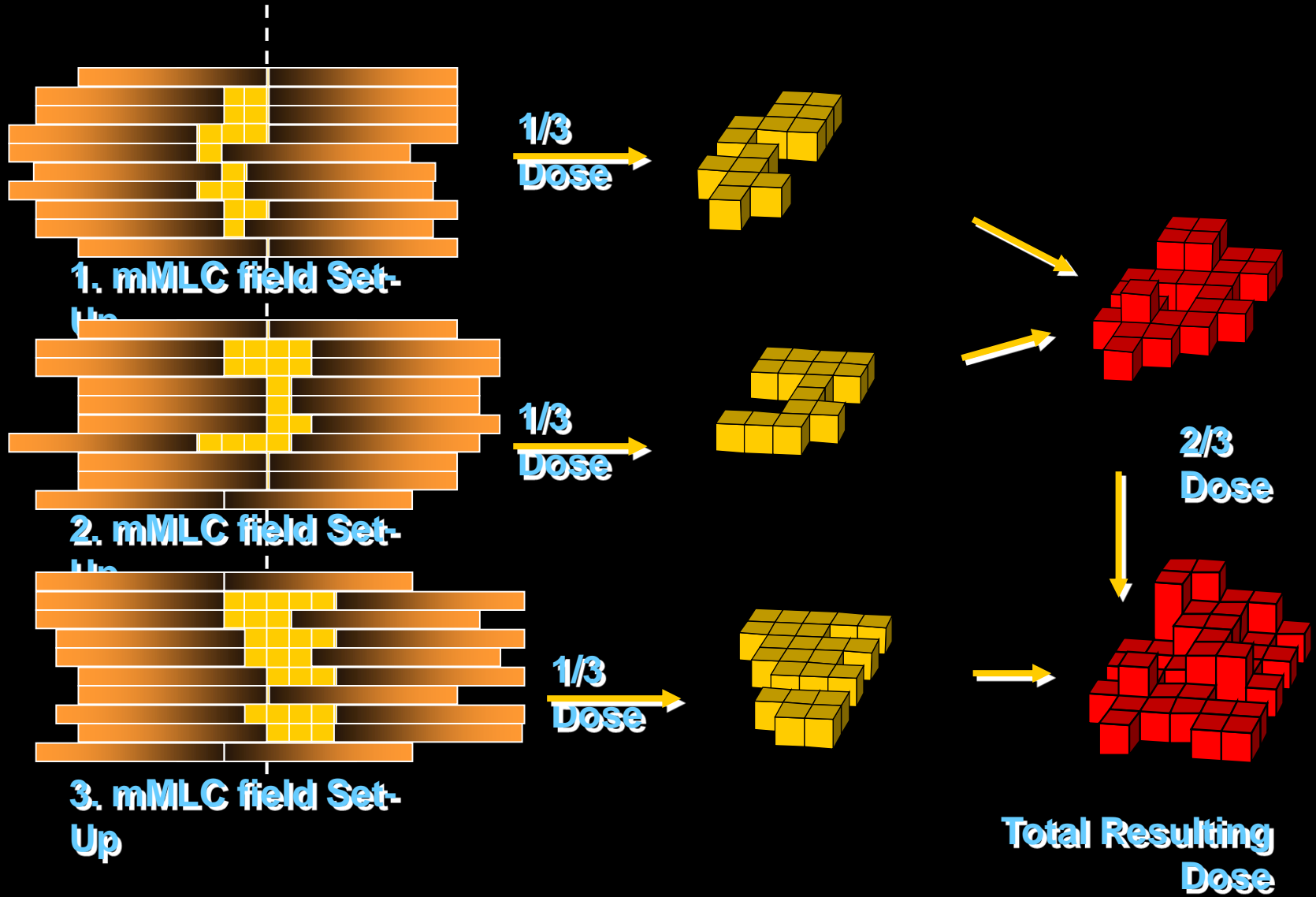
Isodose 80%

...is further optimization possible?

Intensity modulated X-ray beams and **proton beams** can provide an even superior dose distribution compared to conventional 3-D conformal RT

Intensity Modulated X-ray Beams (IMRT)

IMRT

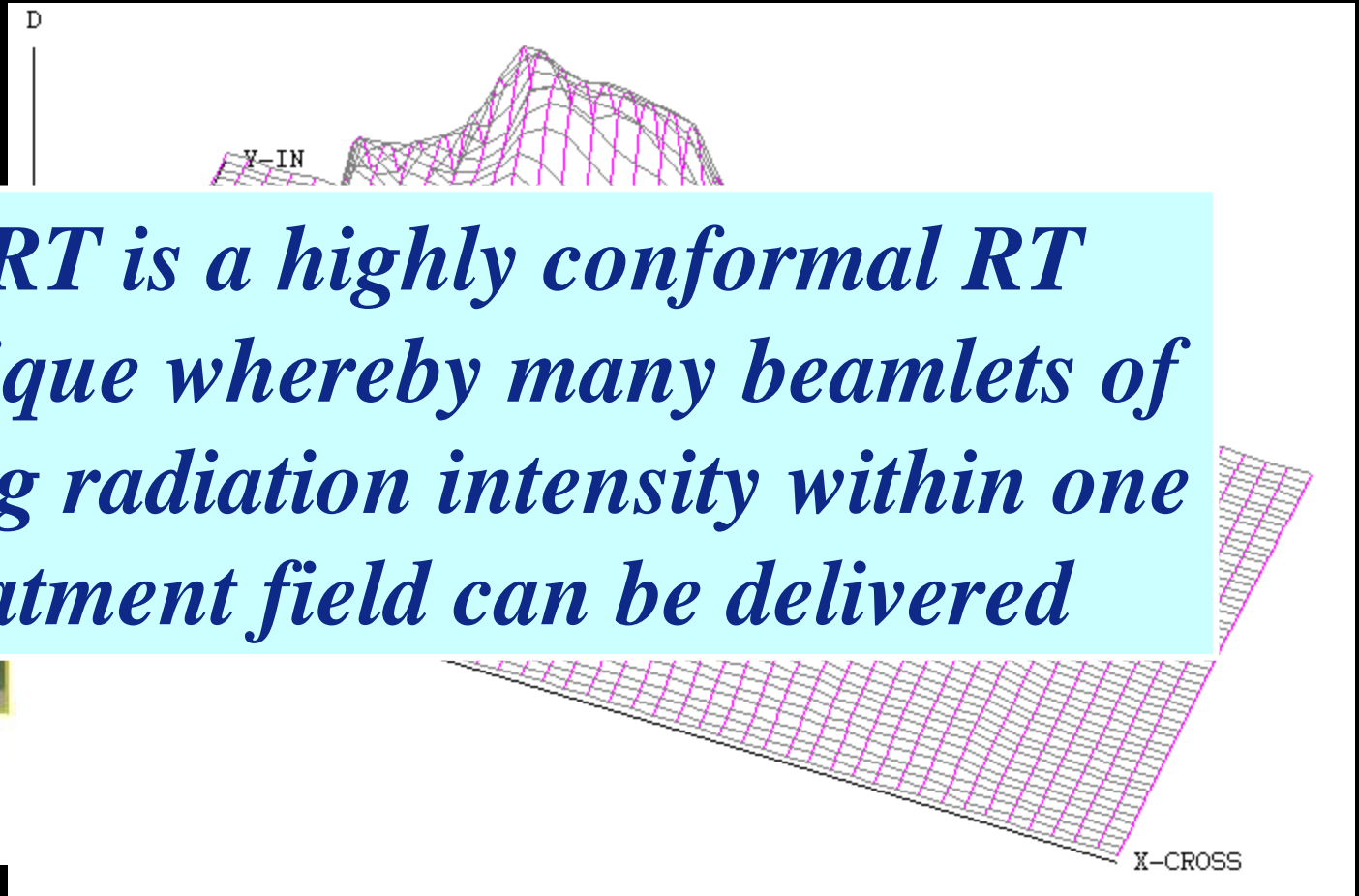


Intensity *M*odulated *R*adiation *T*herapy

IMRT is a highly conformal RT technique whereby many beamlets of varying radiation intensity within one treatment field can be delivered

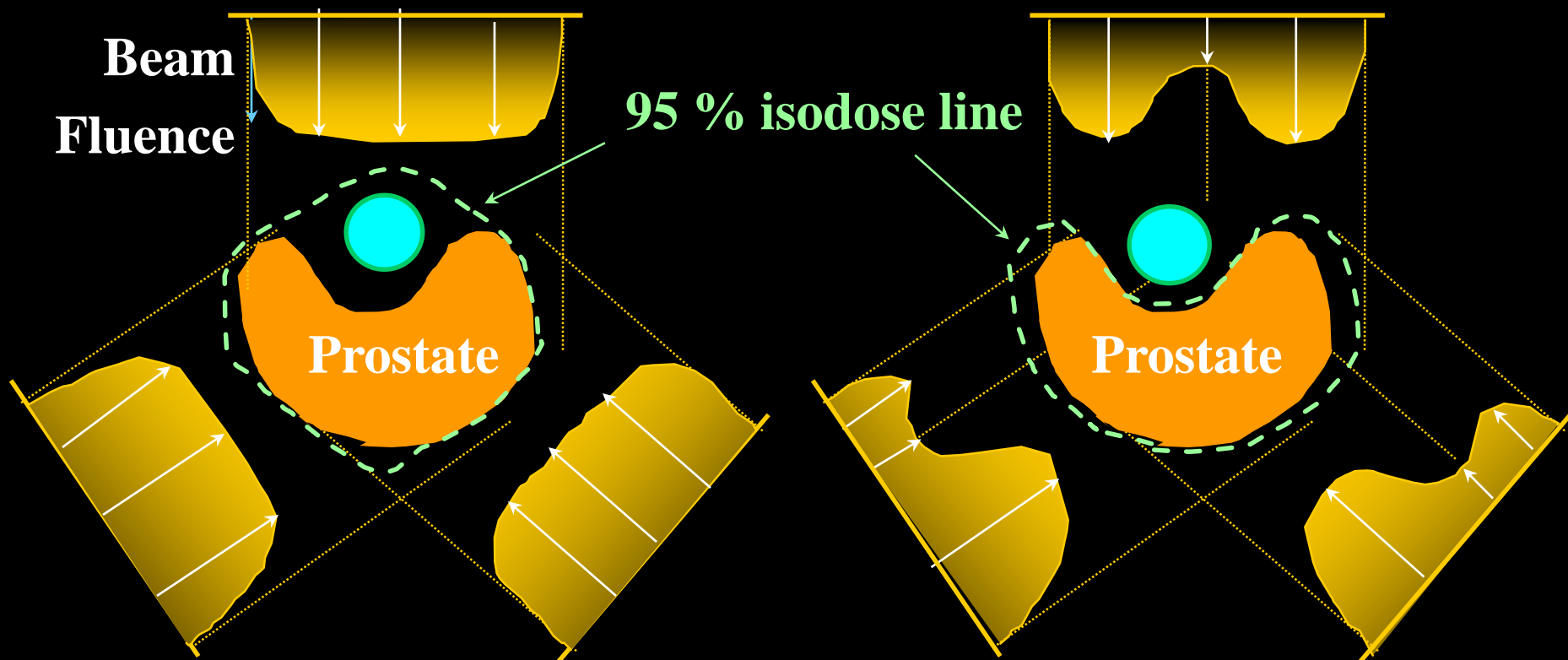


Fluence or Intensity Map



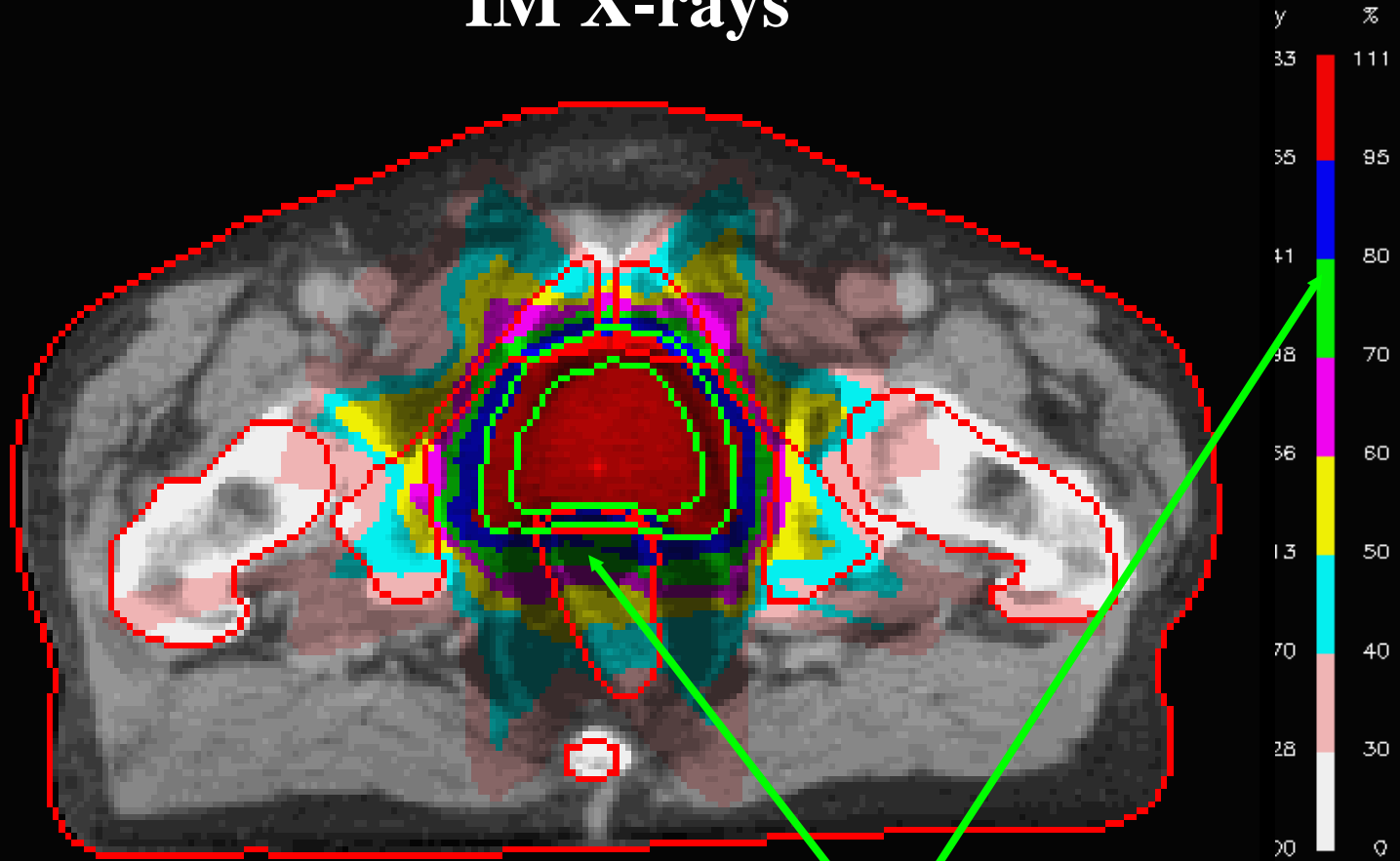
3D Dose Distribution

3D CRT vs. IMXT



Prostate (100%: 81 Gy)

IM X-rays



Isodose 80%

Optimization of treatment precision...

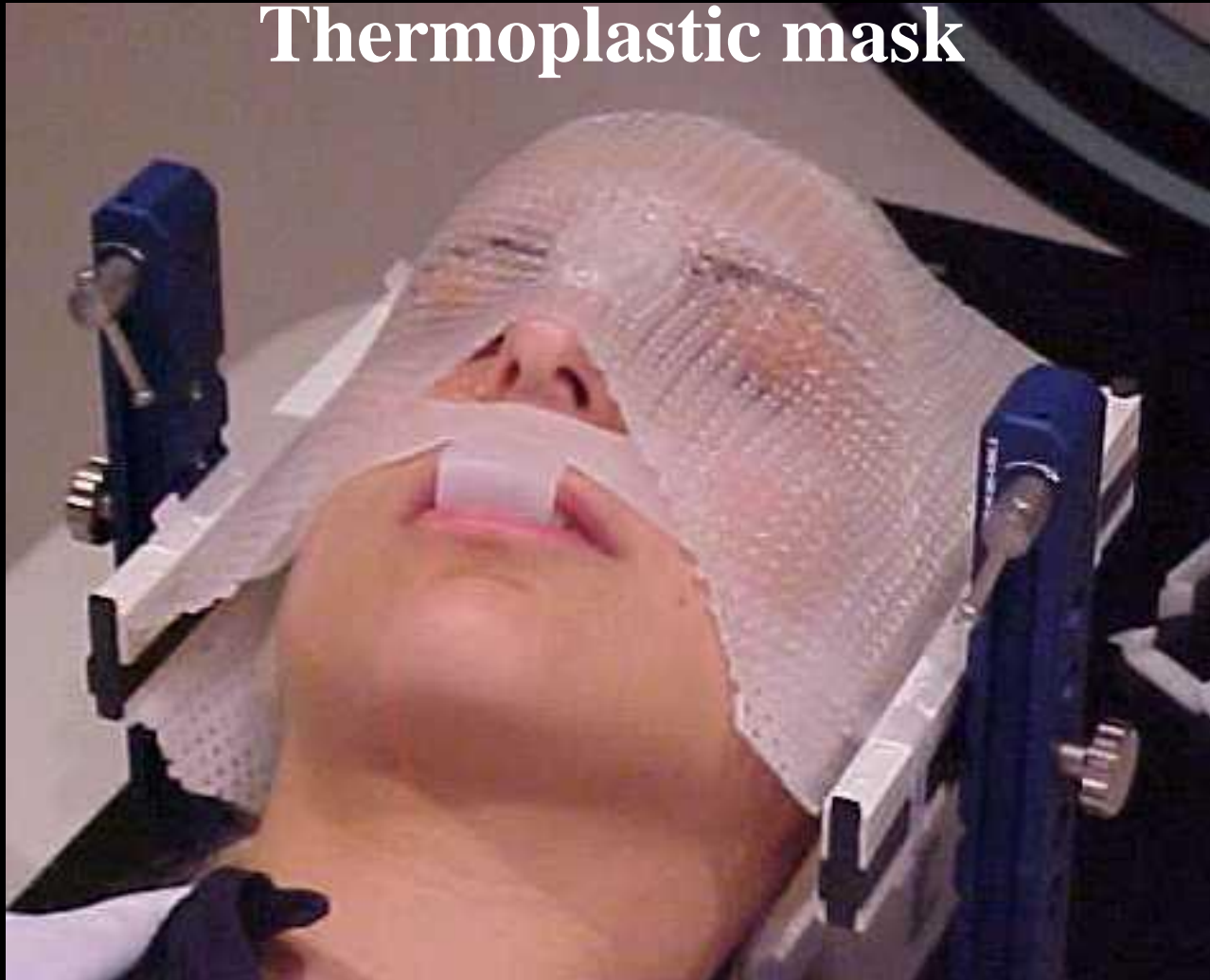- Improvement in patient's repositioning
- Reduction of internal organ motion


External immobilization

- Thermoplastic mask
- Customized vacuum body cast
- Stereotactic extracranial infrared guided repositioning system
- Treatment set-up tune-up: bone registration

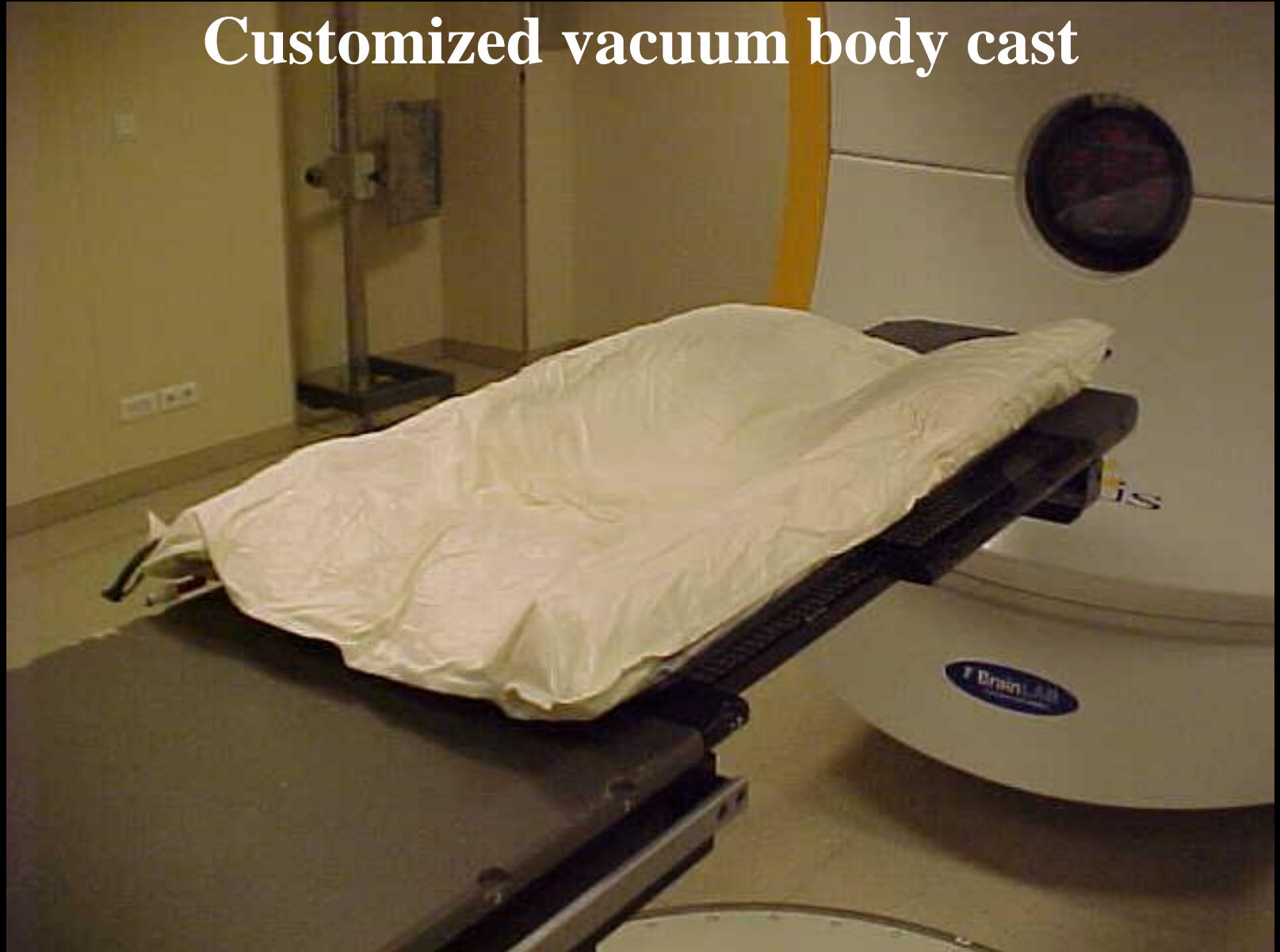Positioning / Patient fixation

Thermoplastic mask

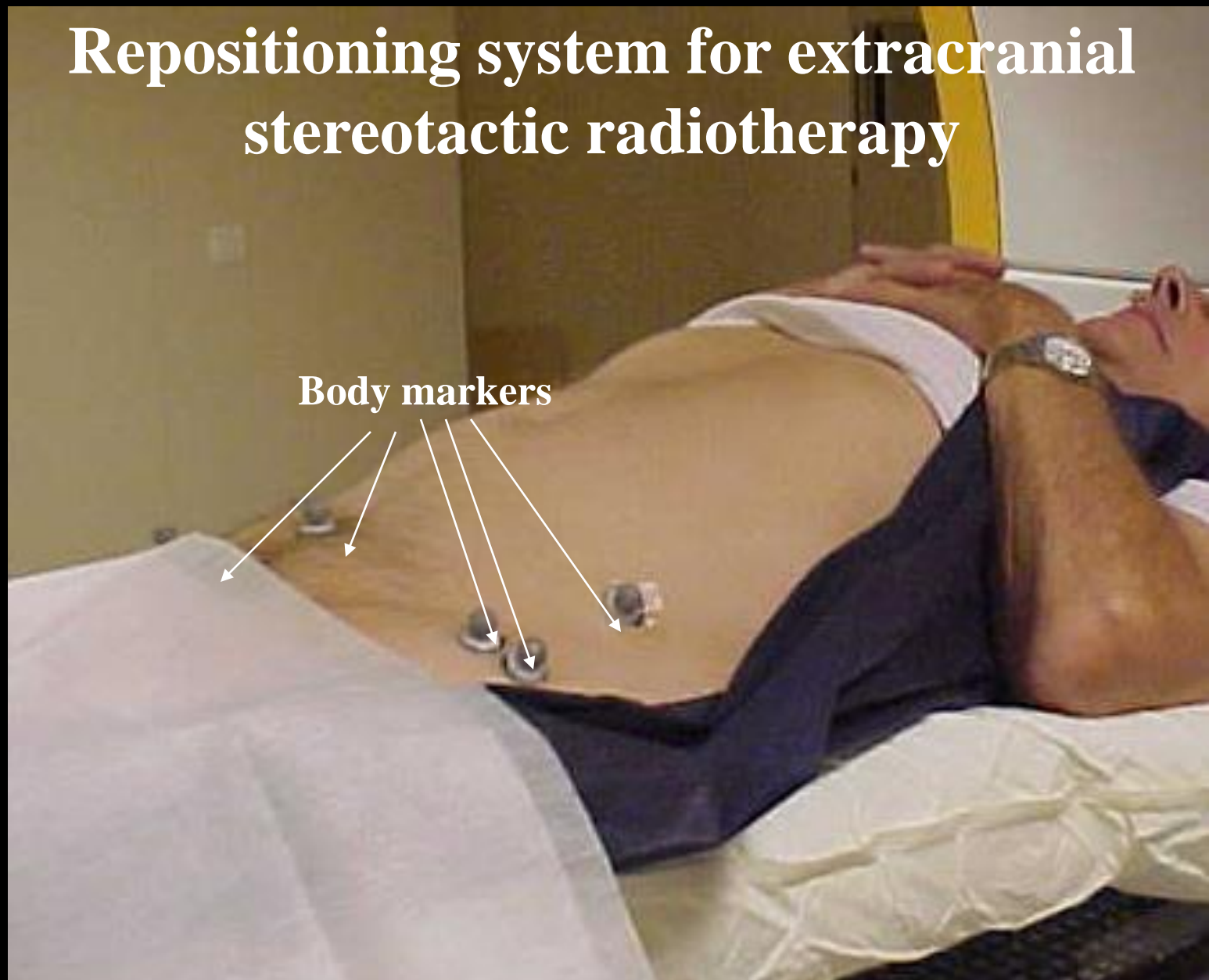



Customized vacuum body cast



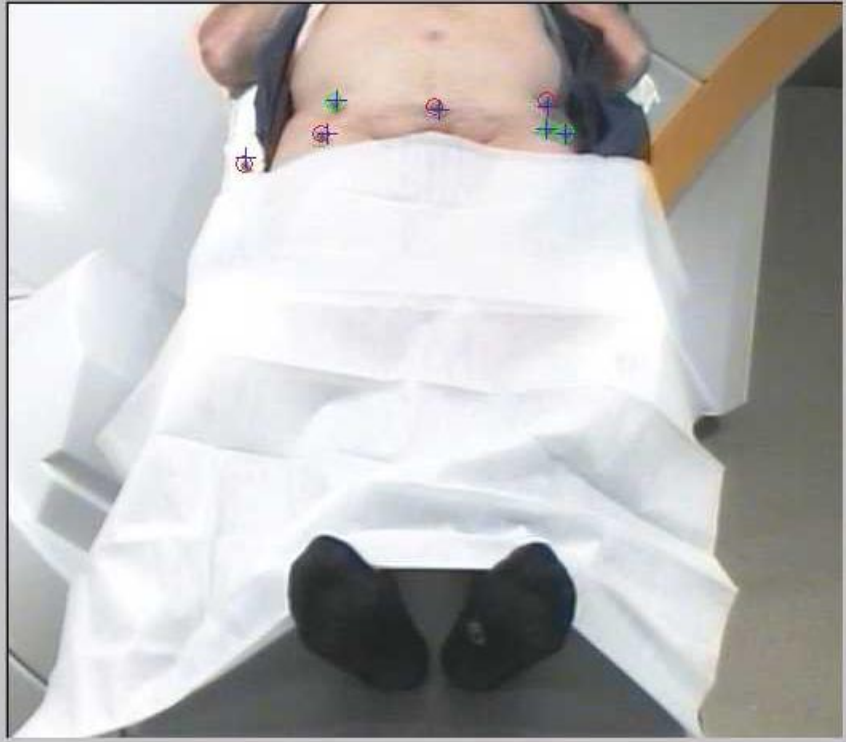Repositioning system for extracranial stereotactic radiotherapy



Body markers



-  Calibration
-  Load Patient
-  Position Patient
-  New Patient
-  Store Position
-  Ultrasound
-  Video
-  Exit



View

- Live
- Ref. Image + Live
- Ref. Image - Live
- Reference Image

Body Shape

- current
- target

Objects

- current

Store Image

Reference Document

Done

Press Enable Button

MATCH

ACCURACY

Vertical **-000.77**

Longitud. **+000.22**

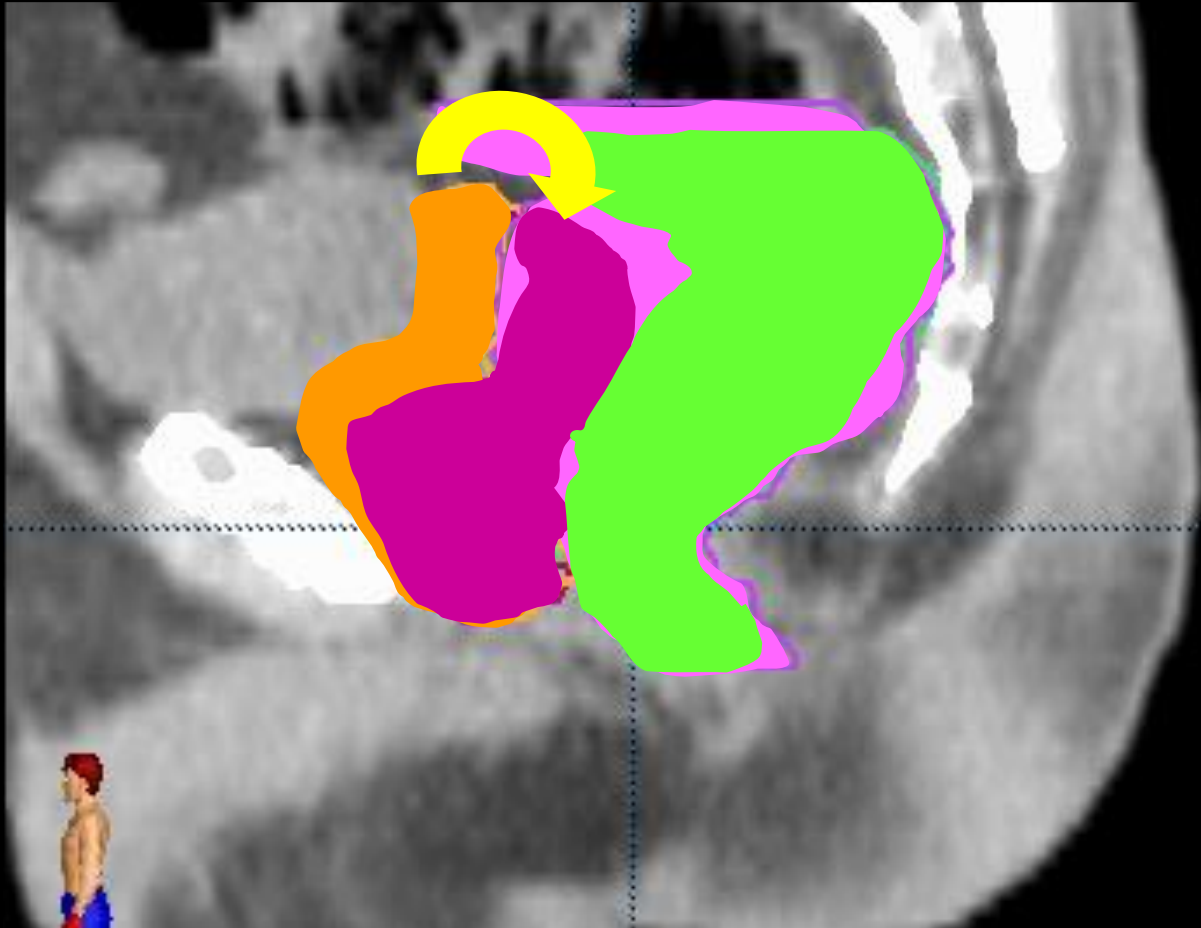
Lateral **-000.38**

Table **+000.32°**

Internal organ immobilization

- Endorectal balloon inflated with 100 cc air
- Fiducial marker registration

Apex centered sagittal rotation



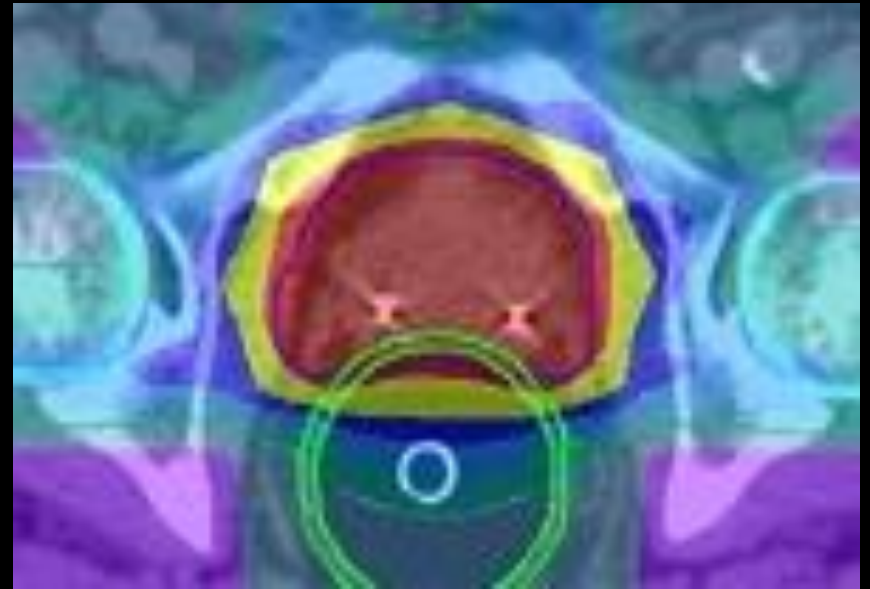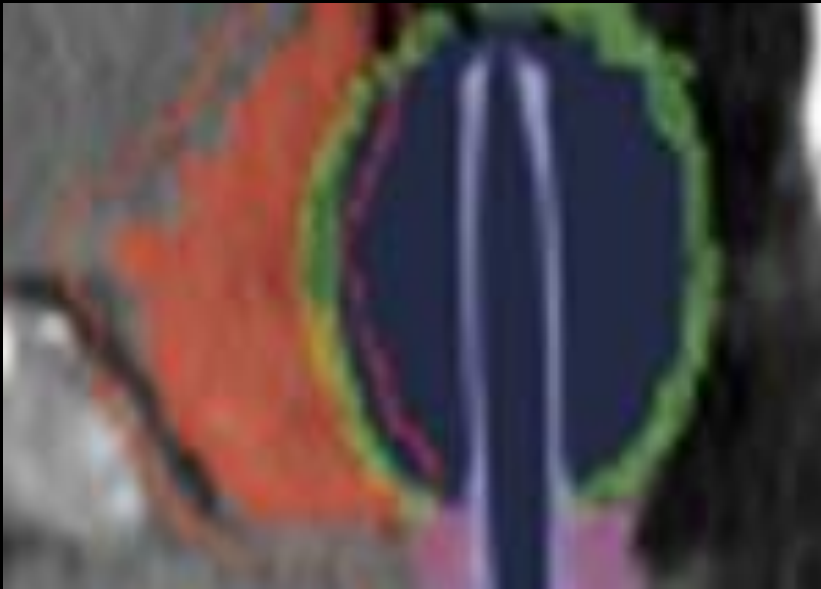
— CTV at planning

— Rectum at planning

— CTV on-treatment

— Rectum on-treatment

Endorectal balloon (QLRAD[®])

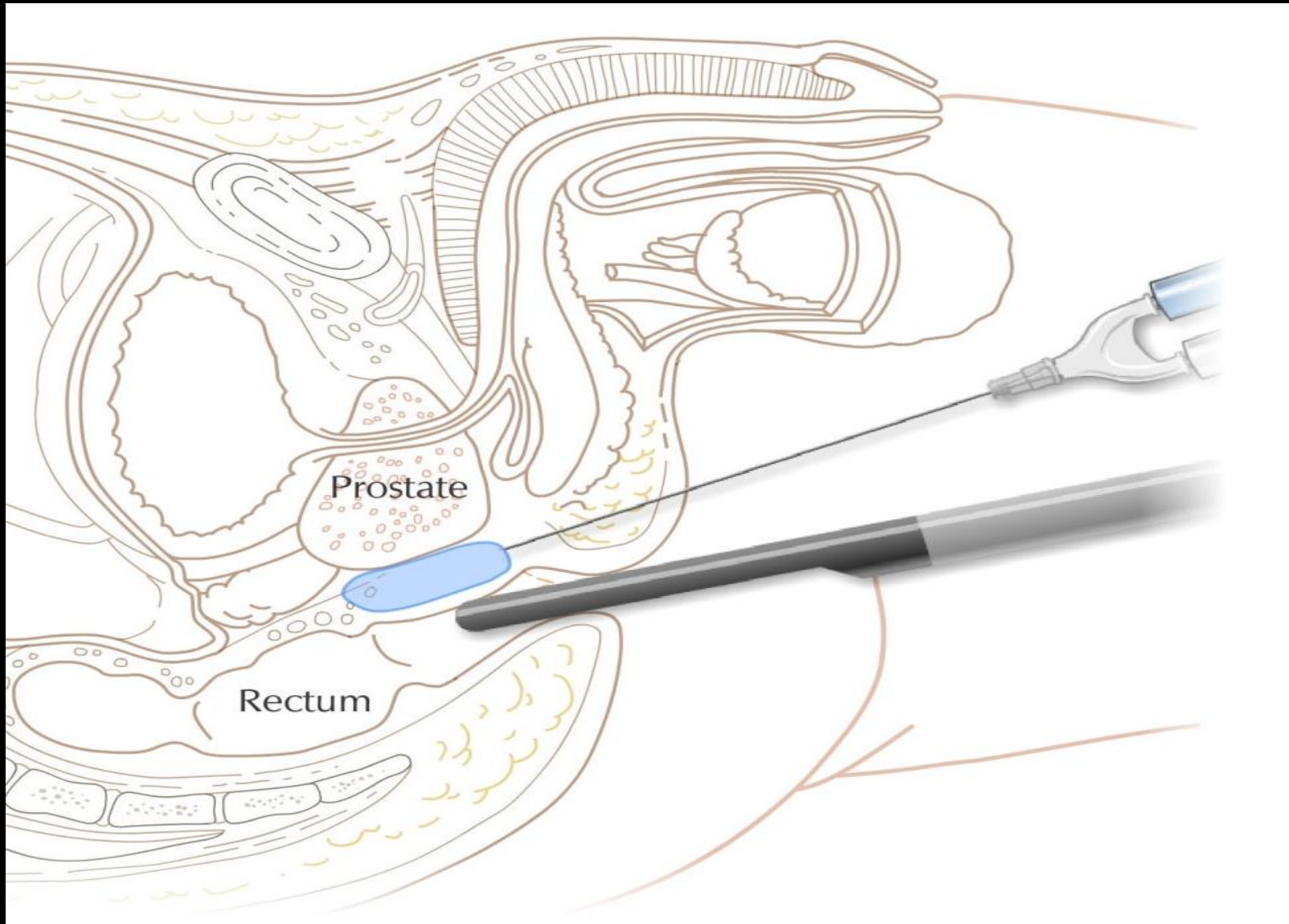


Recto-prostatic spacers

Reabsorbable spacer between the rectum and the prostate

- **Hyaluronic acid (RESTITANE®)**
- **Hydrogel (AUGMENIX®)**
- **Biodegradable balloon (BIOPROTECT®)**

Spacer transperineal implant



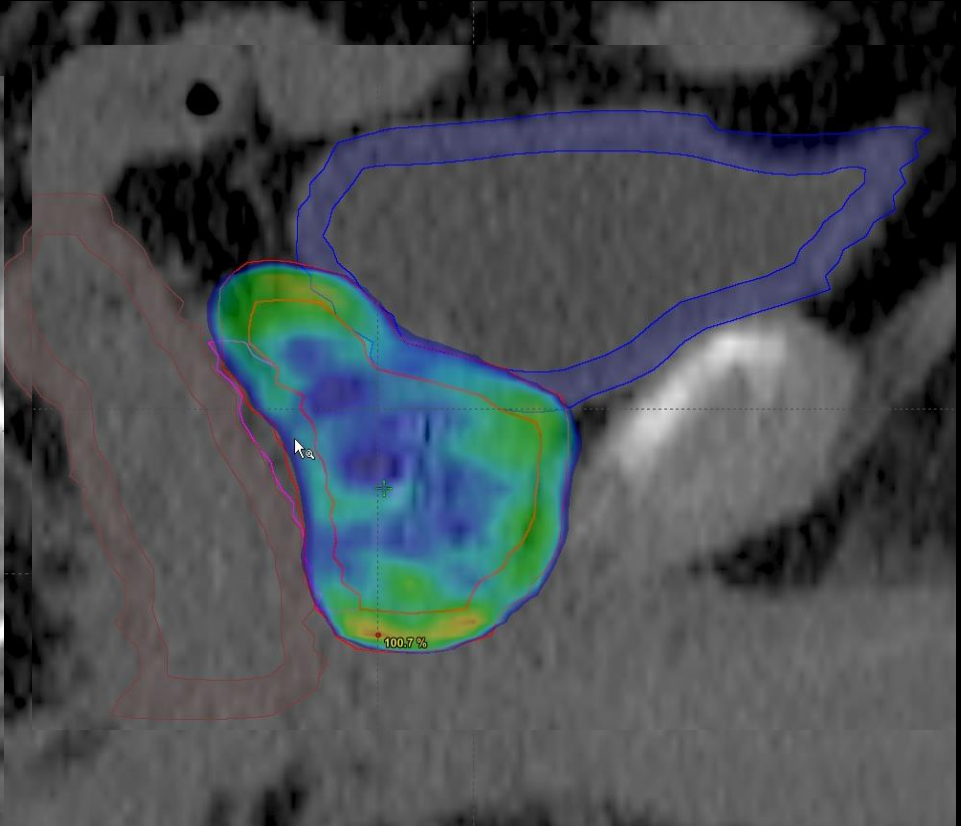
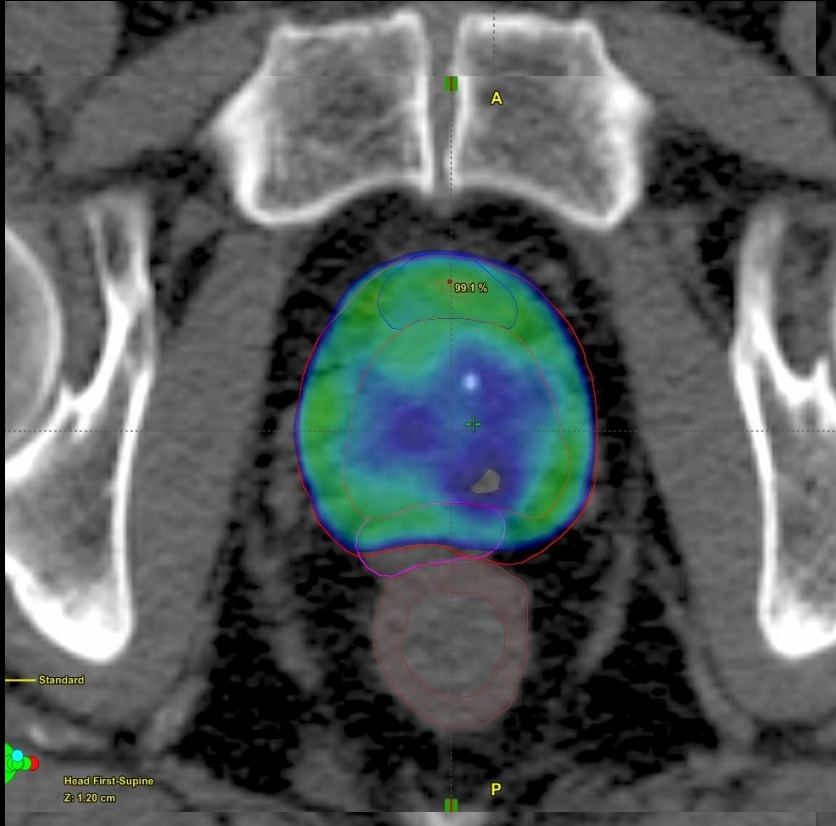


Image Guided Radio Therapy (IGRT)

**On-line treatment verification:
electronic portal imaging devices**


Fiducial marker registration

Gold seed implants

IGRT PREMIUM marked 1.0 mm x 5.8 mm 19G 20 cm 40-1285 QTY: 1
Markador PREMIUM IGRT 1.0 mm x 5.8 mm 19G 20 cm 40-1285

ISO: 9914	SIZE: 19G x 20cm	Lot No: 07770110
REF: 190108-03		UNIQUE ONLY (U)
LOT: 1012-08		TO NOT REUSE (N)
EXP: 2008-07		STABILITY GUARANTEED IF PACKAGE IS UNOPENED & UNHARMED

Manufactured by: Covidien Ltd. CE



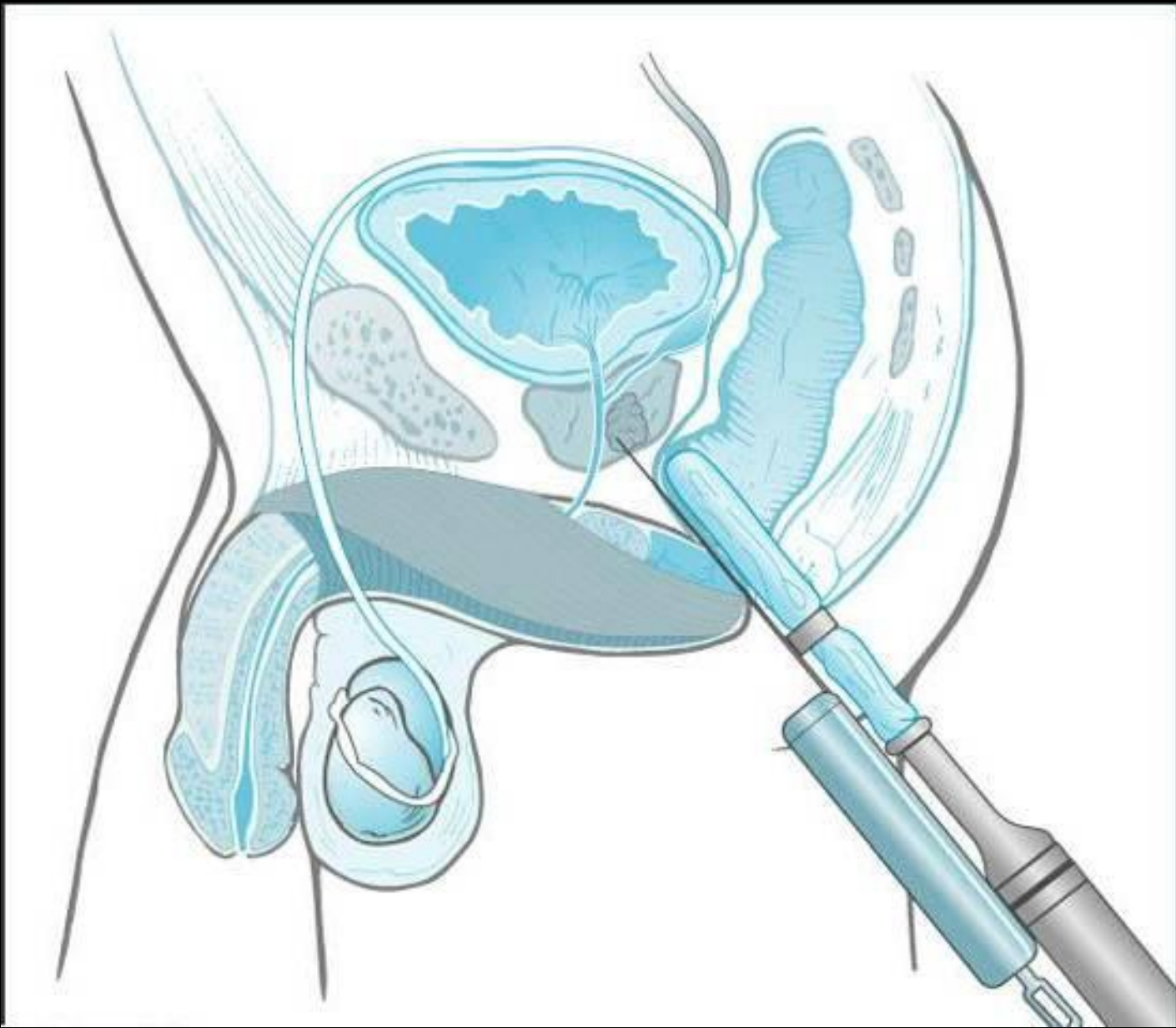
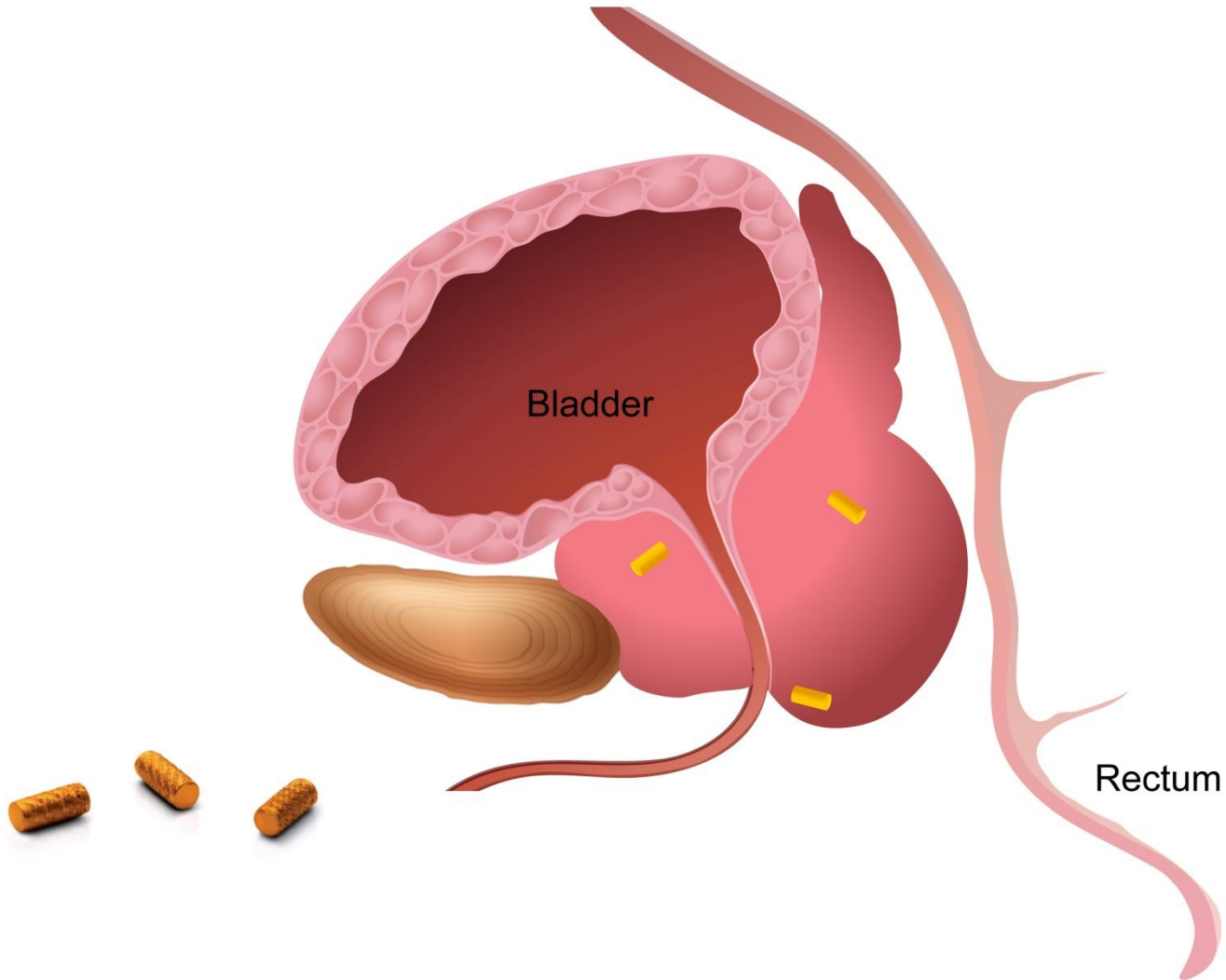
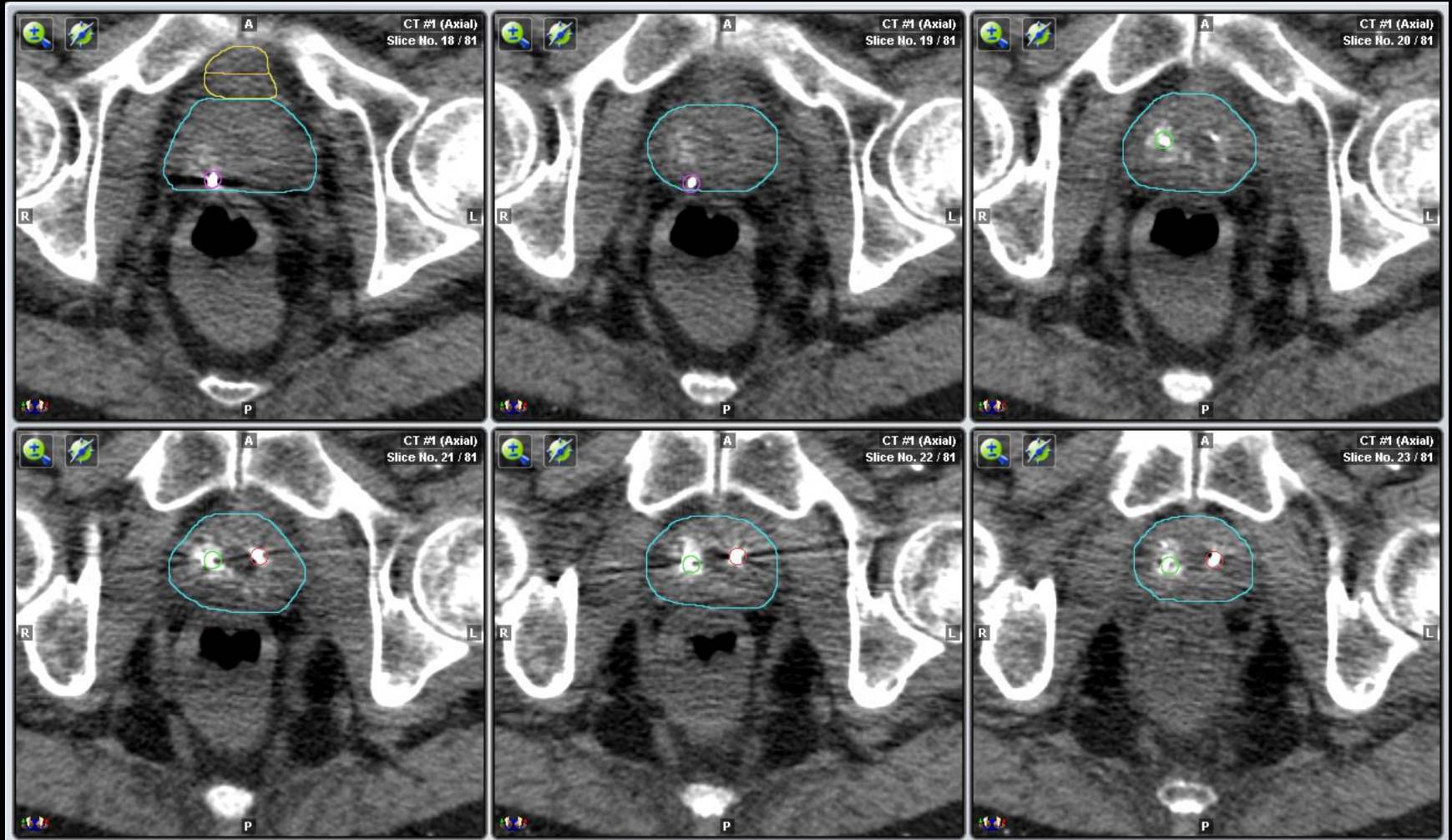


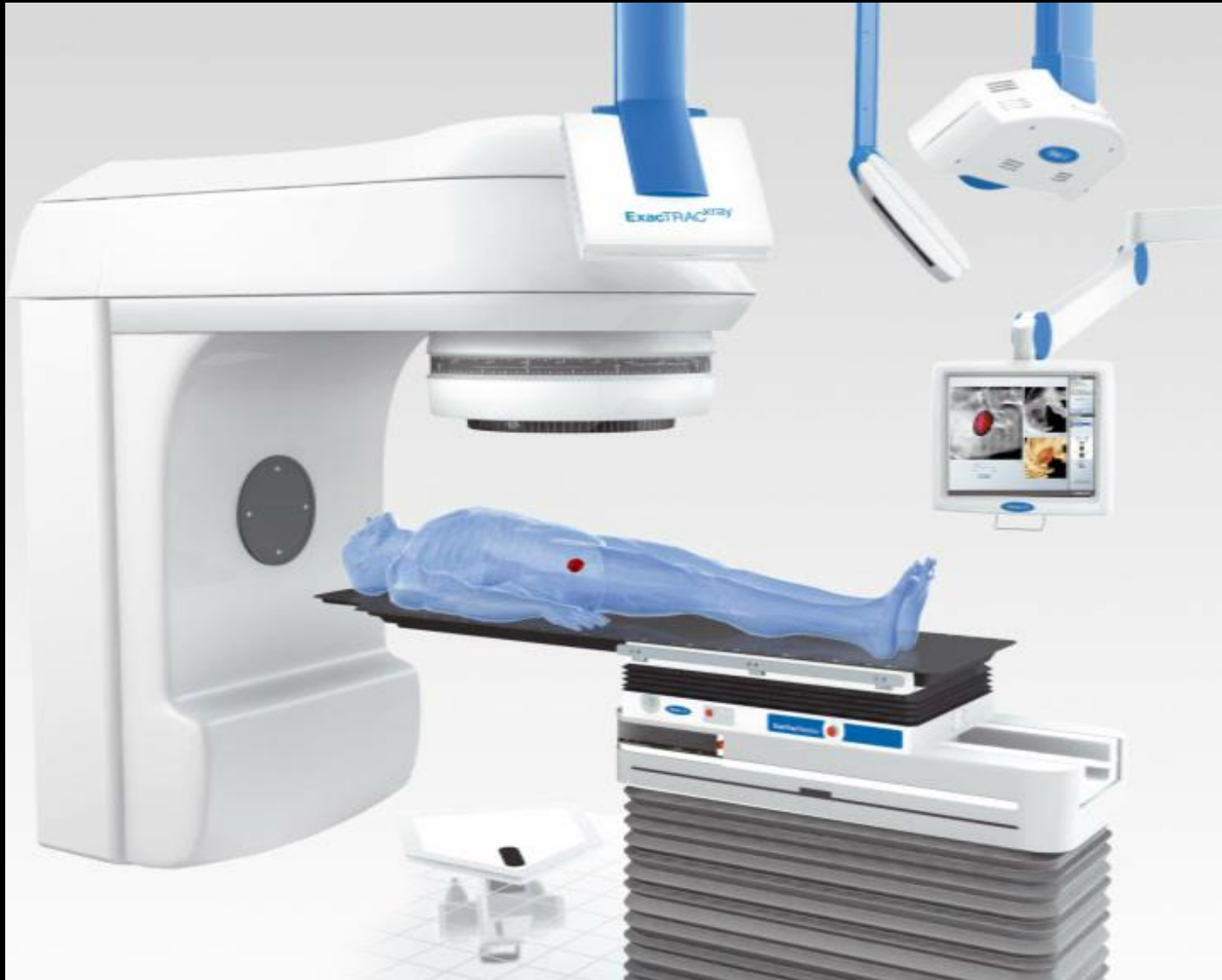Image guided radiotherapy (IGRT)



CT with fiducial markers



IGRT: automatic image verification



CT and X-ray image fusion

Replay: X-Ray Acquisition 1



OK

DRR Preview



Contrast

Low High

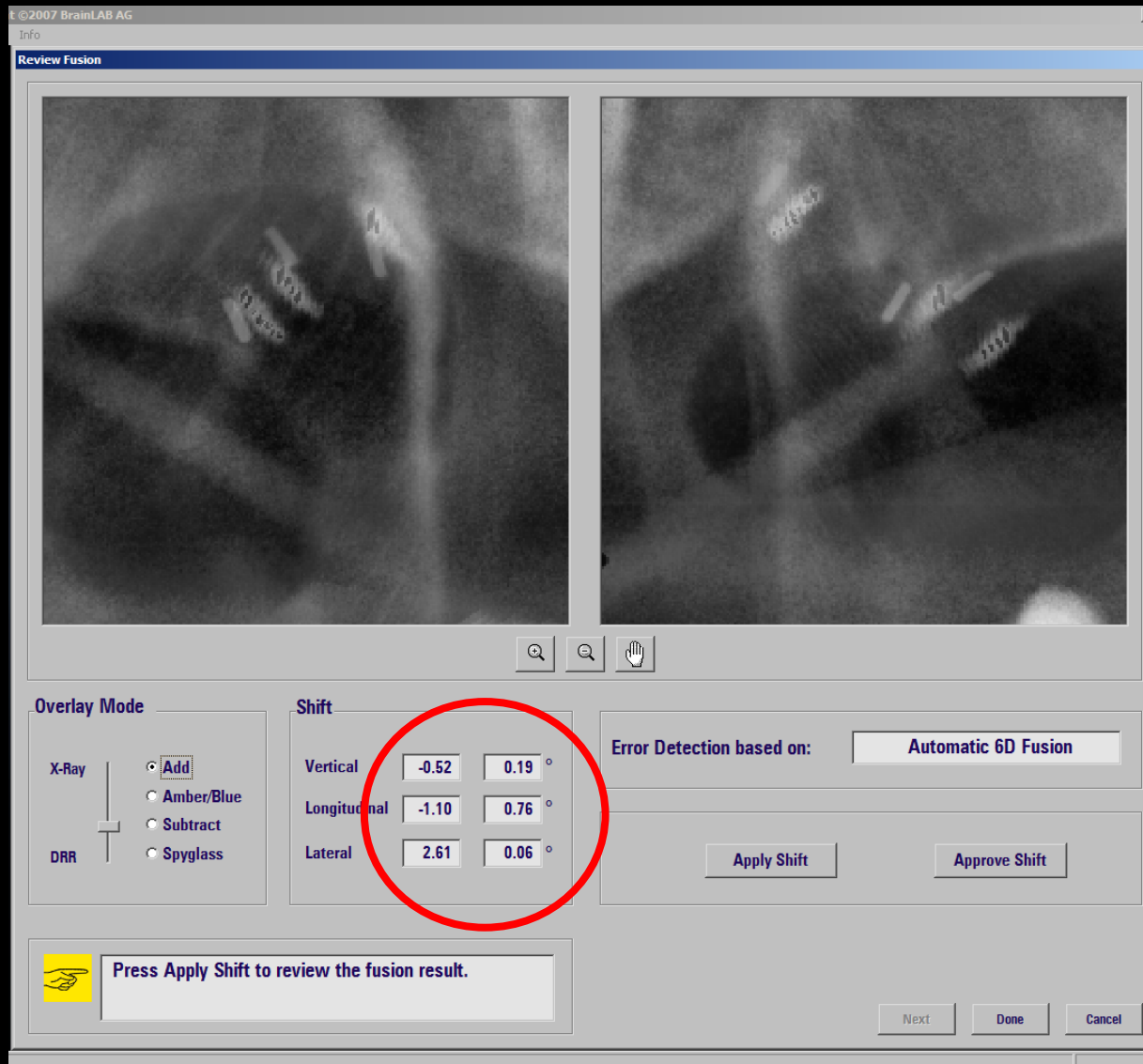
Windowing

Enable

Adjust display parameters and press 'Next' to continue.

Patient Settings < Back Next > Cancel

fusion verification followed by...



...automatic correction

Replay: Fusion & Shift Detection



Overlay Mode

X-Ray Add
 Amber/Blue
 Subtract
DRR Spyglass

Shift

Vertical	0.00	0.00
Longitudinal	0.00	0.00
Lateral	0.00	0.00

Marker Detection

Automatic

Fusion

Fuse Marker

Marker

6 / 6

Delete Define

Shift pattern Reset

Please detect and fuse implanted markers

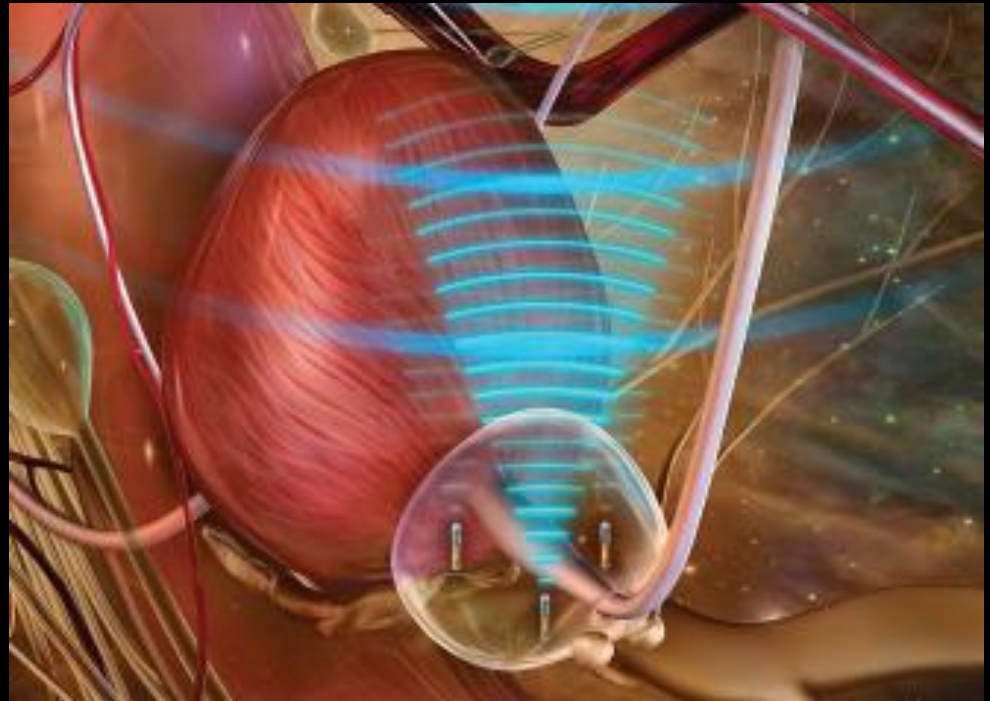
Bony Implants

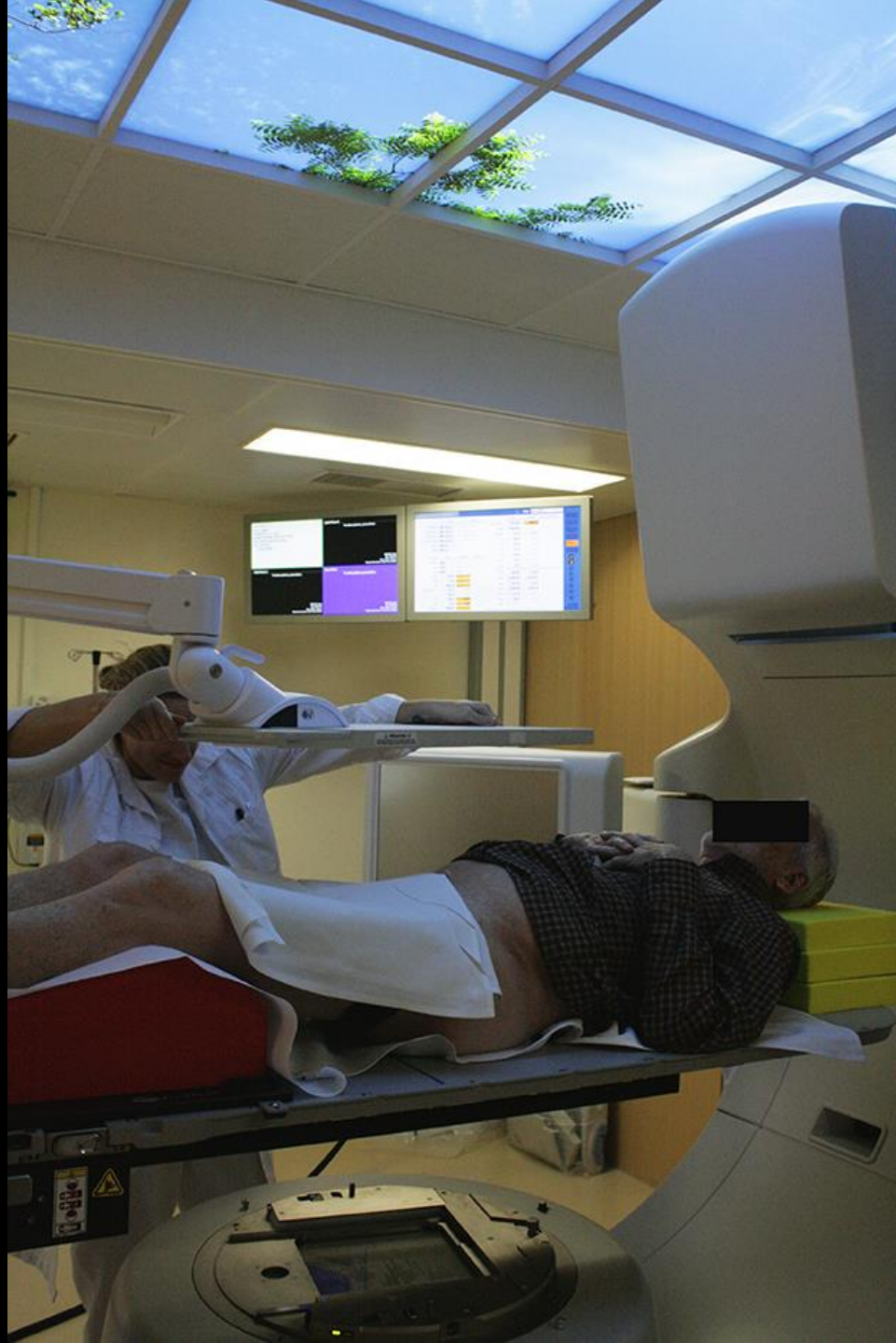Patient Settings

< Back Next > Cancel

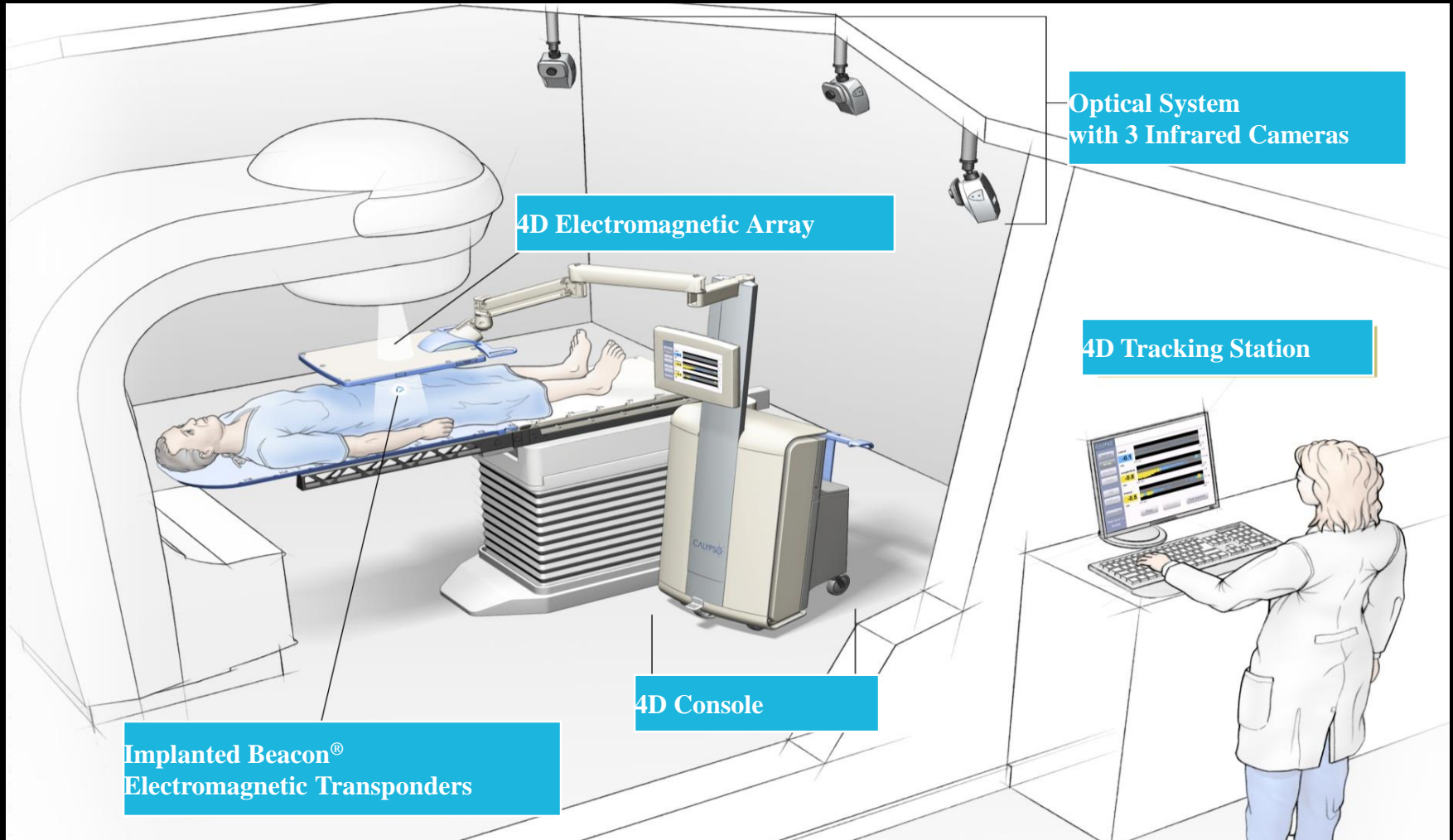
GPS seeds for treatment monitoring & repositioning

CALYPSO®

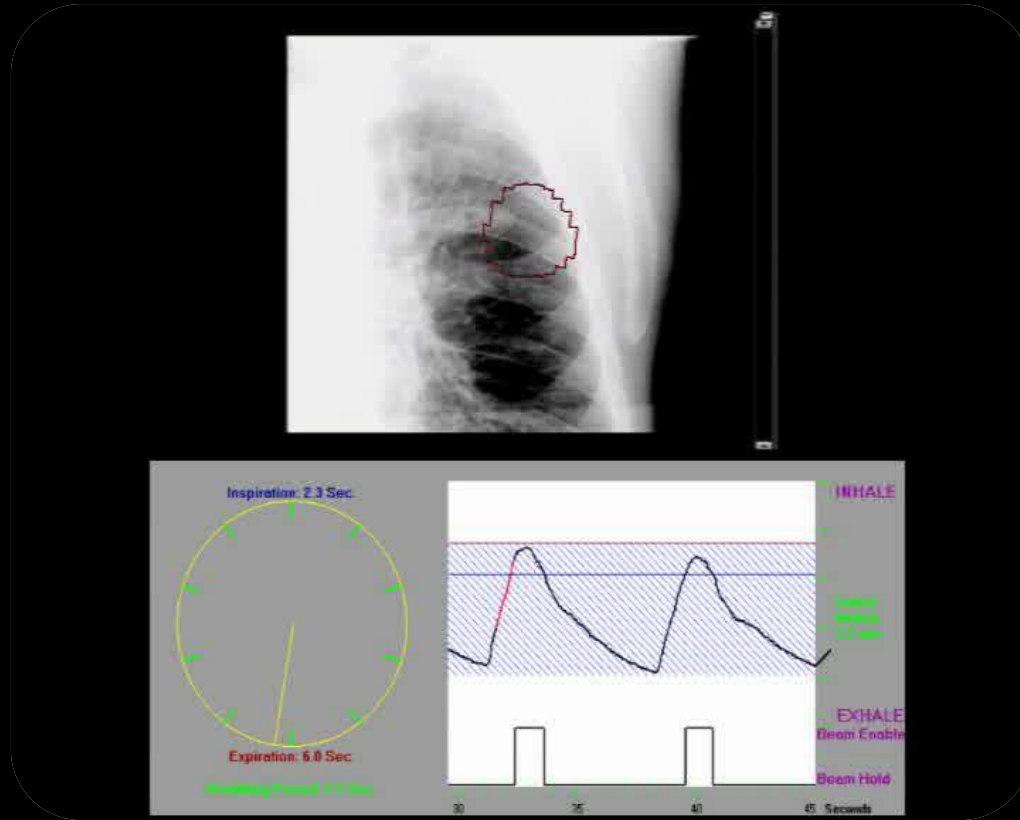




CALYPSO® SYSTEM PLATFORM



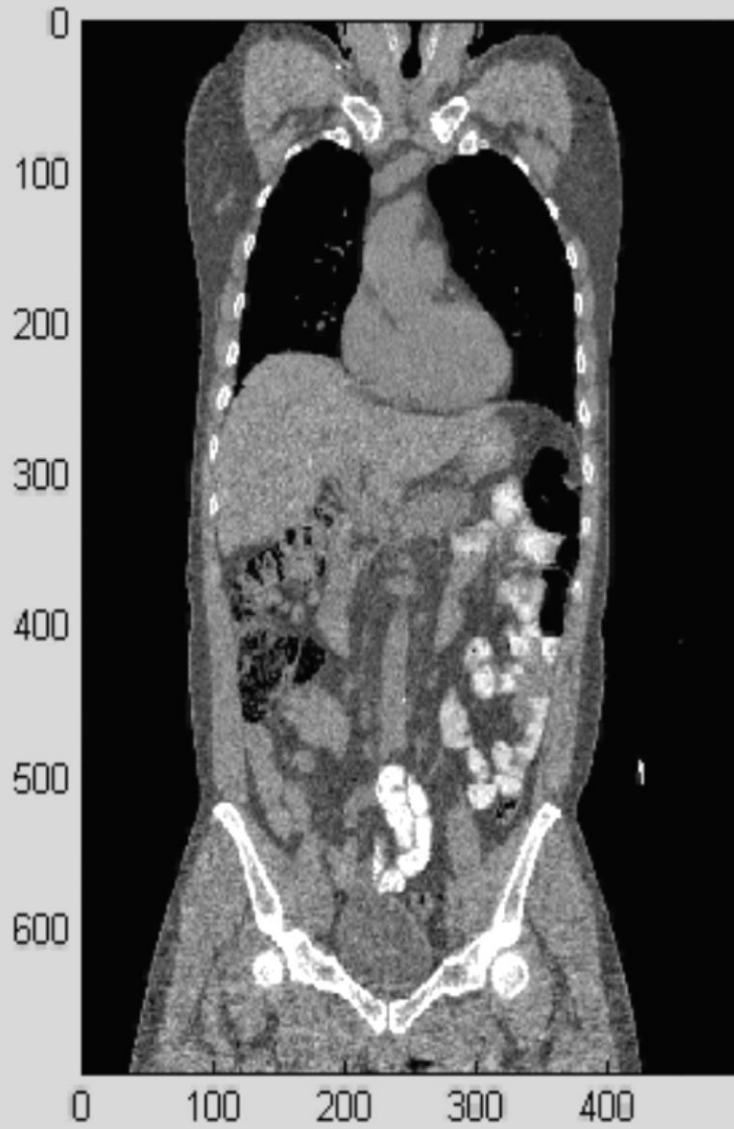Respiratory motion



Respiratory gating:
synchronisation of the «*beam-on*»
with the respiratory motion



Volume -66.2922 Slice: 230



H

R

L

Standard
Head First-Supine



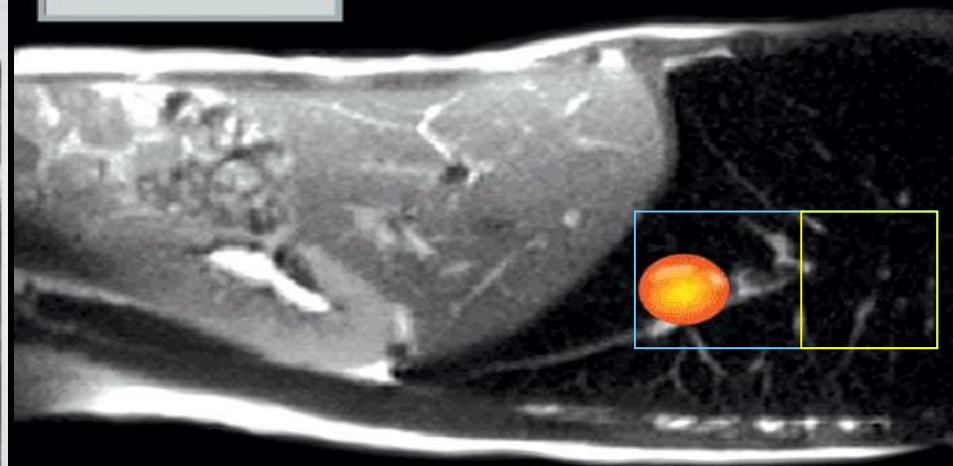
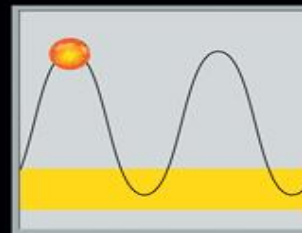
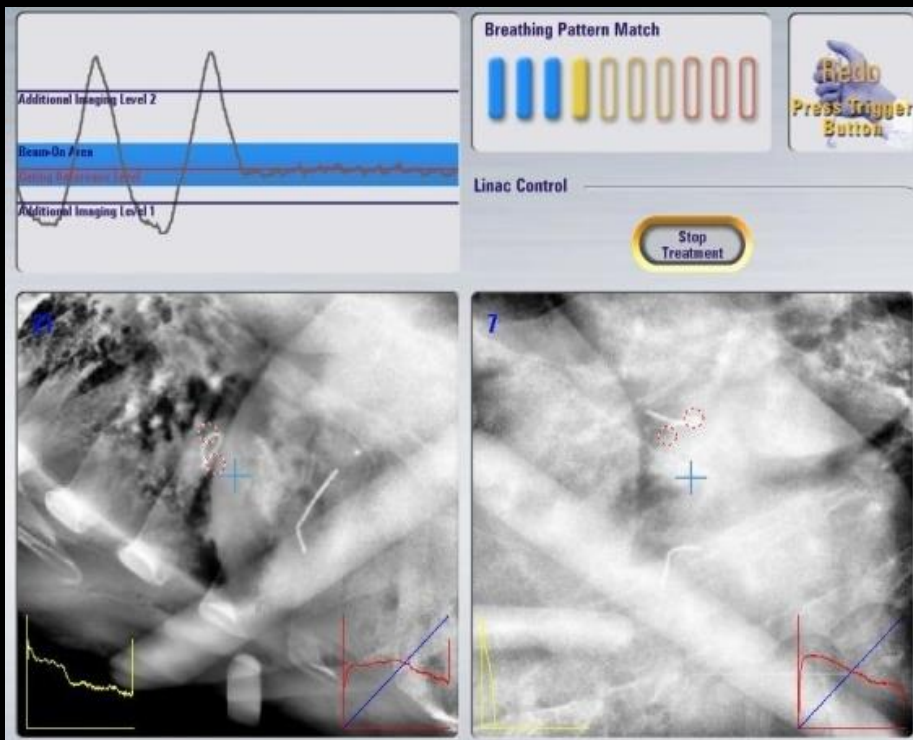
+

F



Novalis Exactrac Adaptive Gating

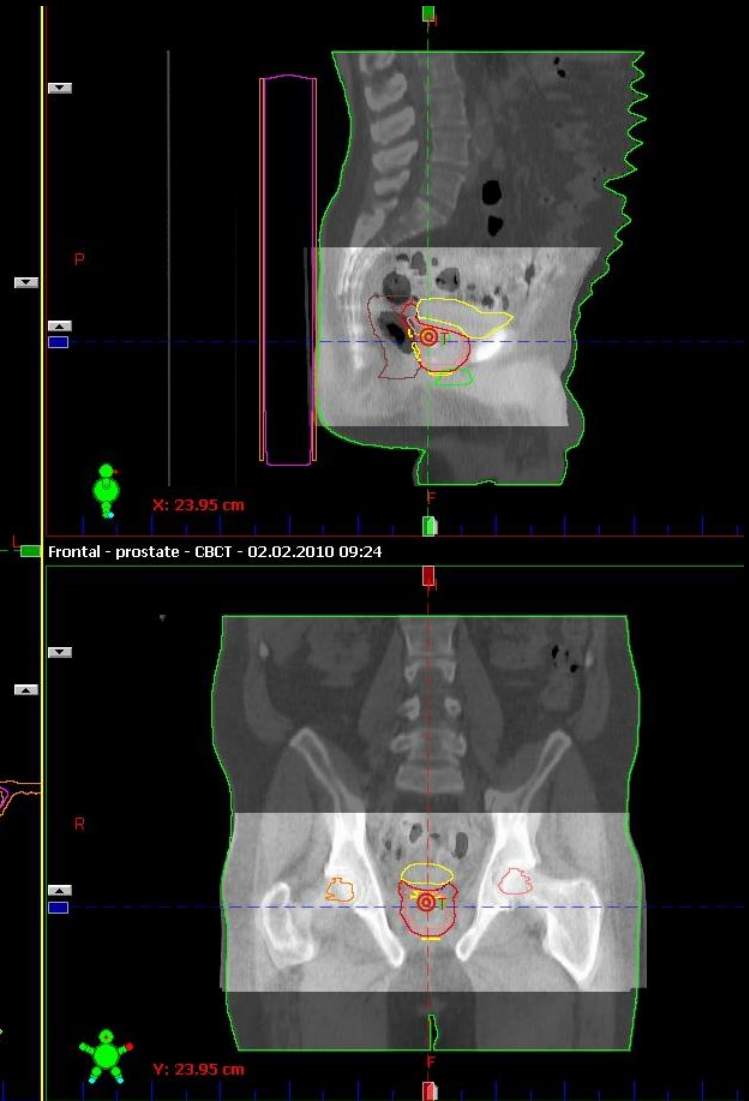
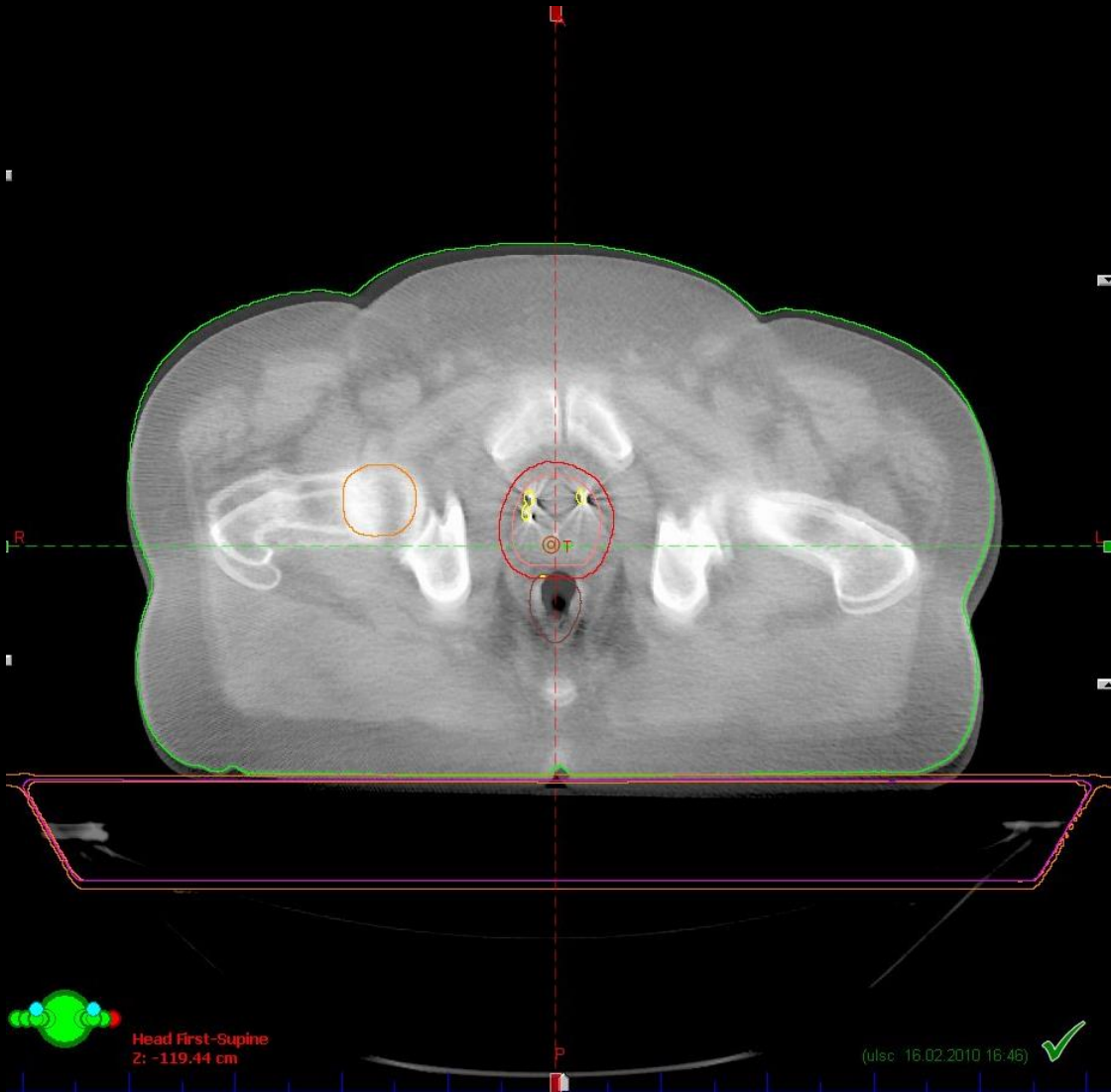
Irradiation during the “beam-on” band



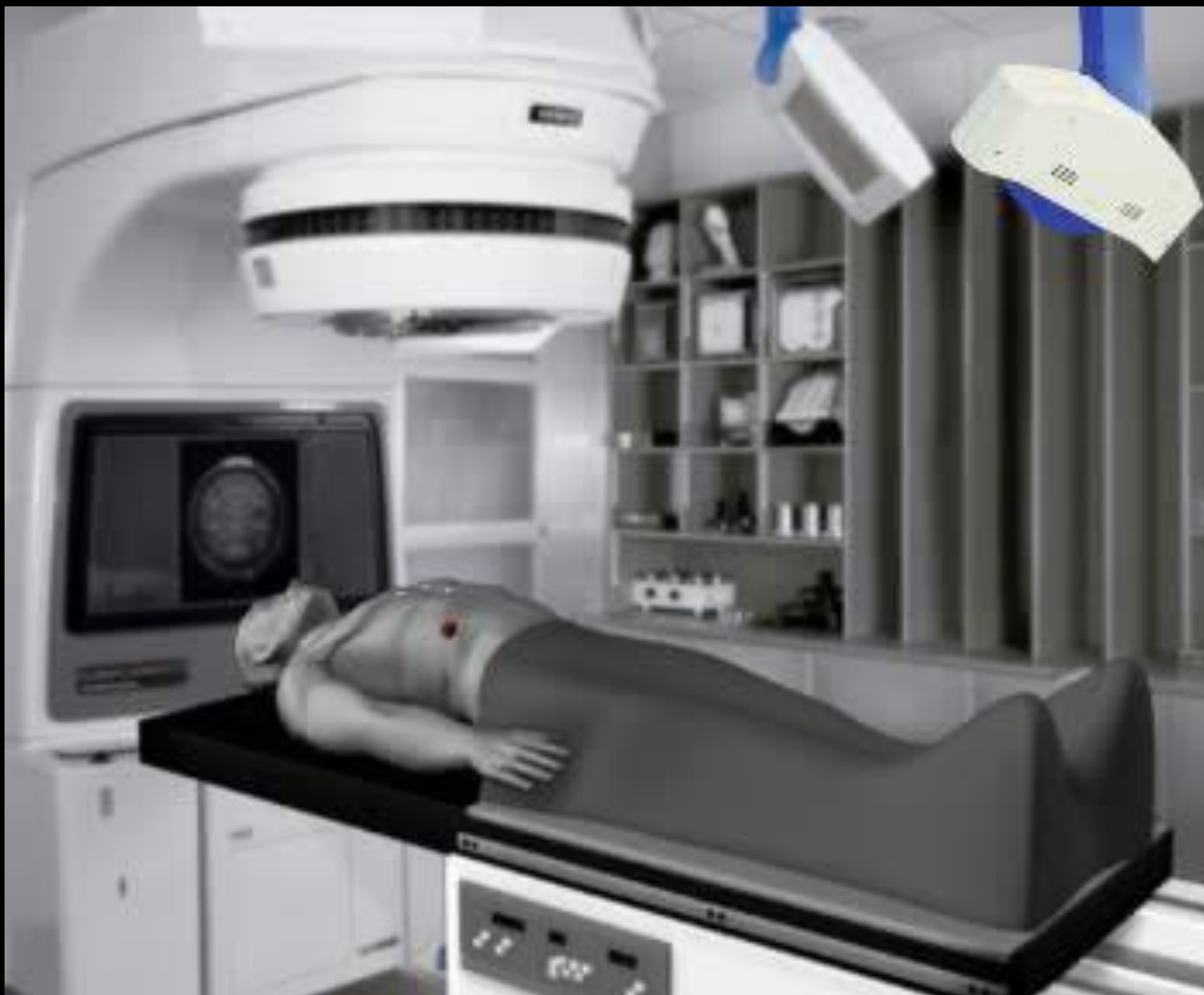X-Ray verification
Intrafraction control of tumor position

(courtesy of R. Wurm,
Frankfurt am Oder)

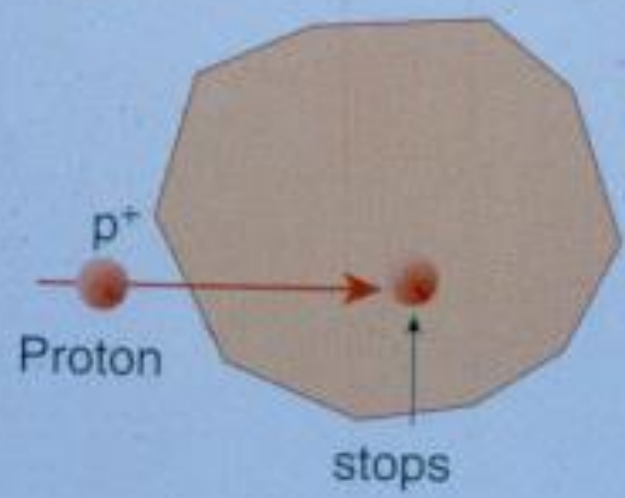
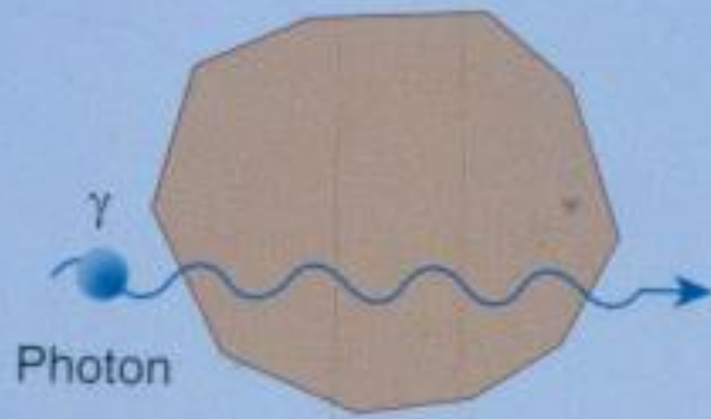
Cone Beam CT (CBCT)



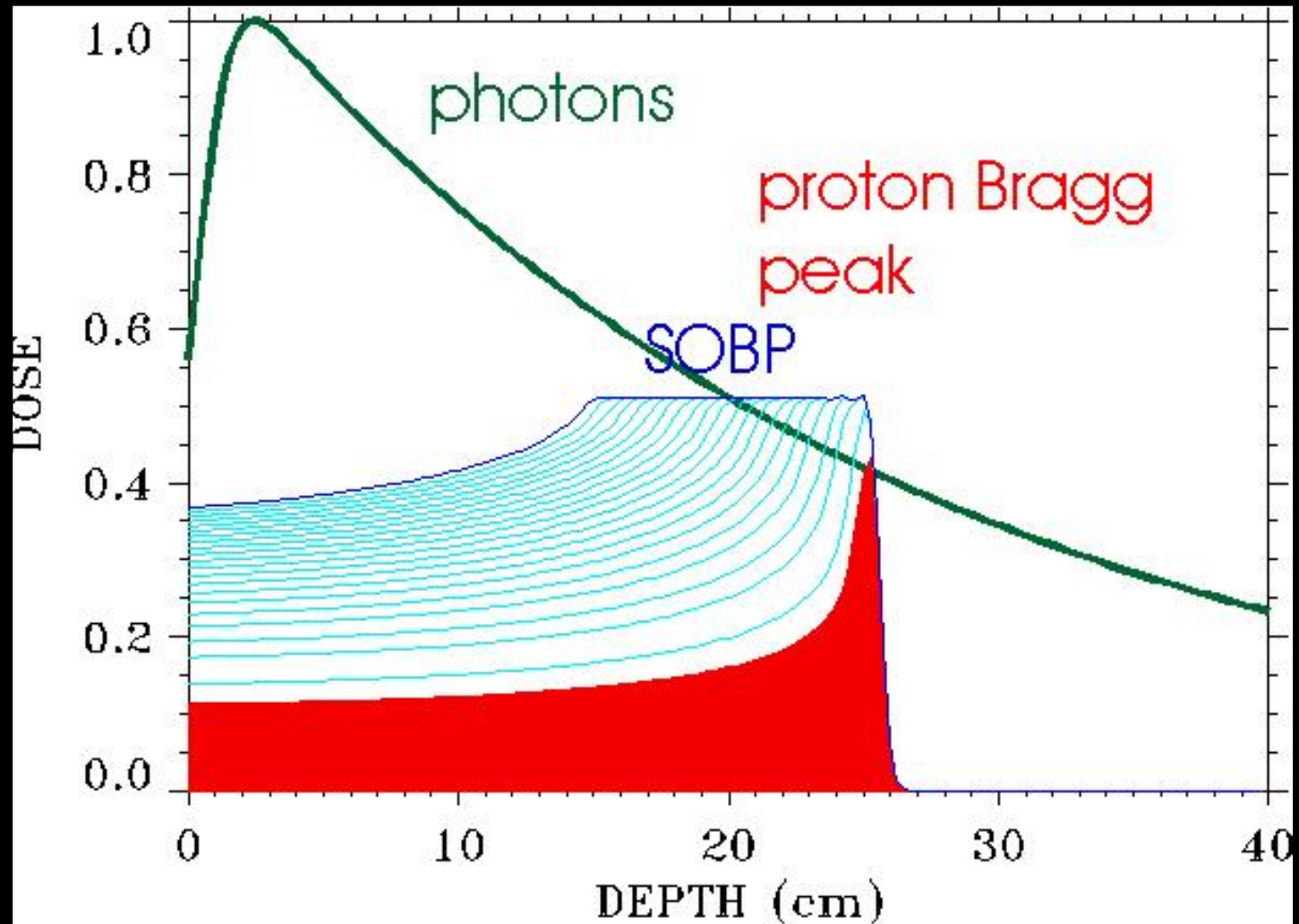
IGRT: respiratory gating

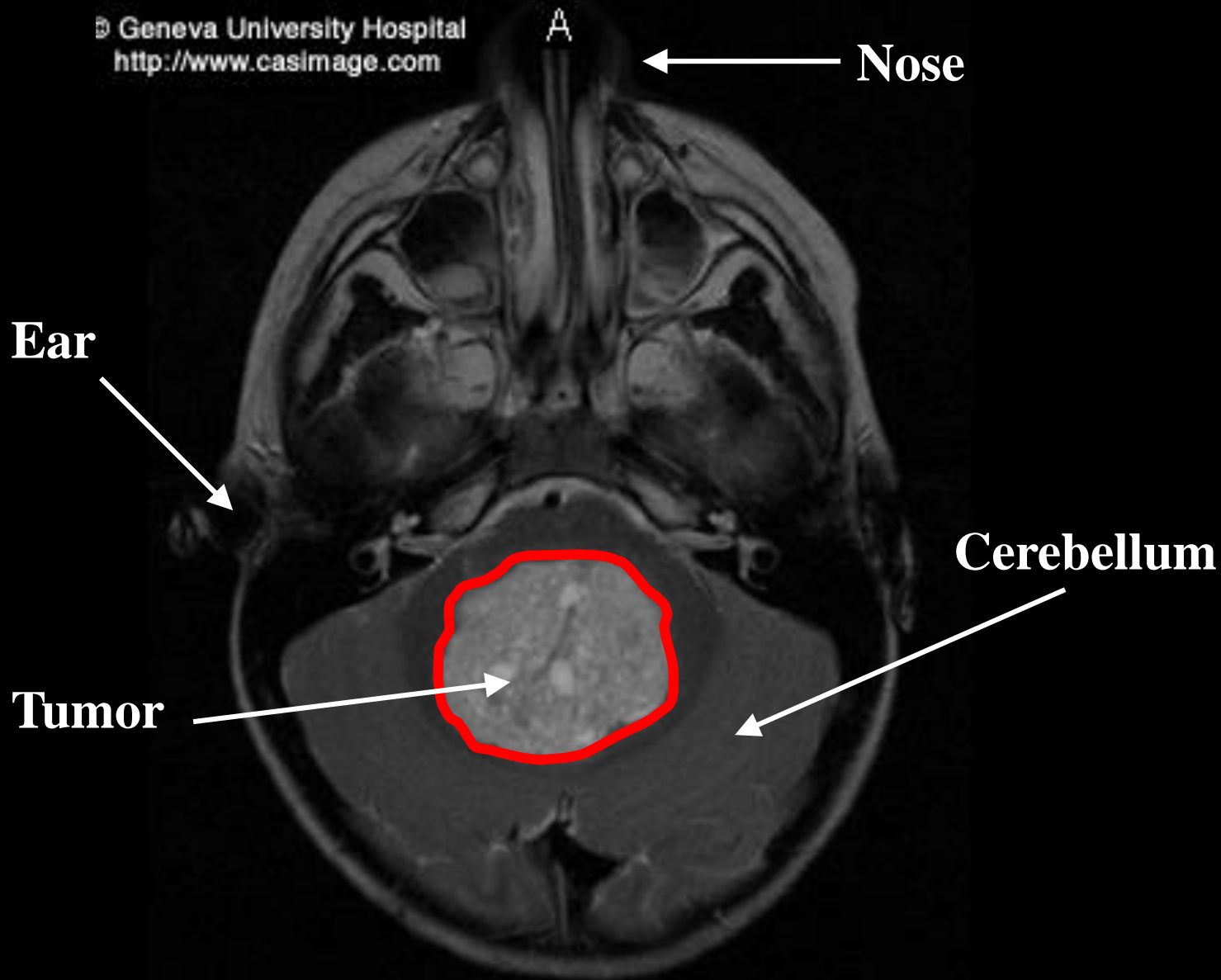


Proton Beams



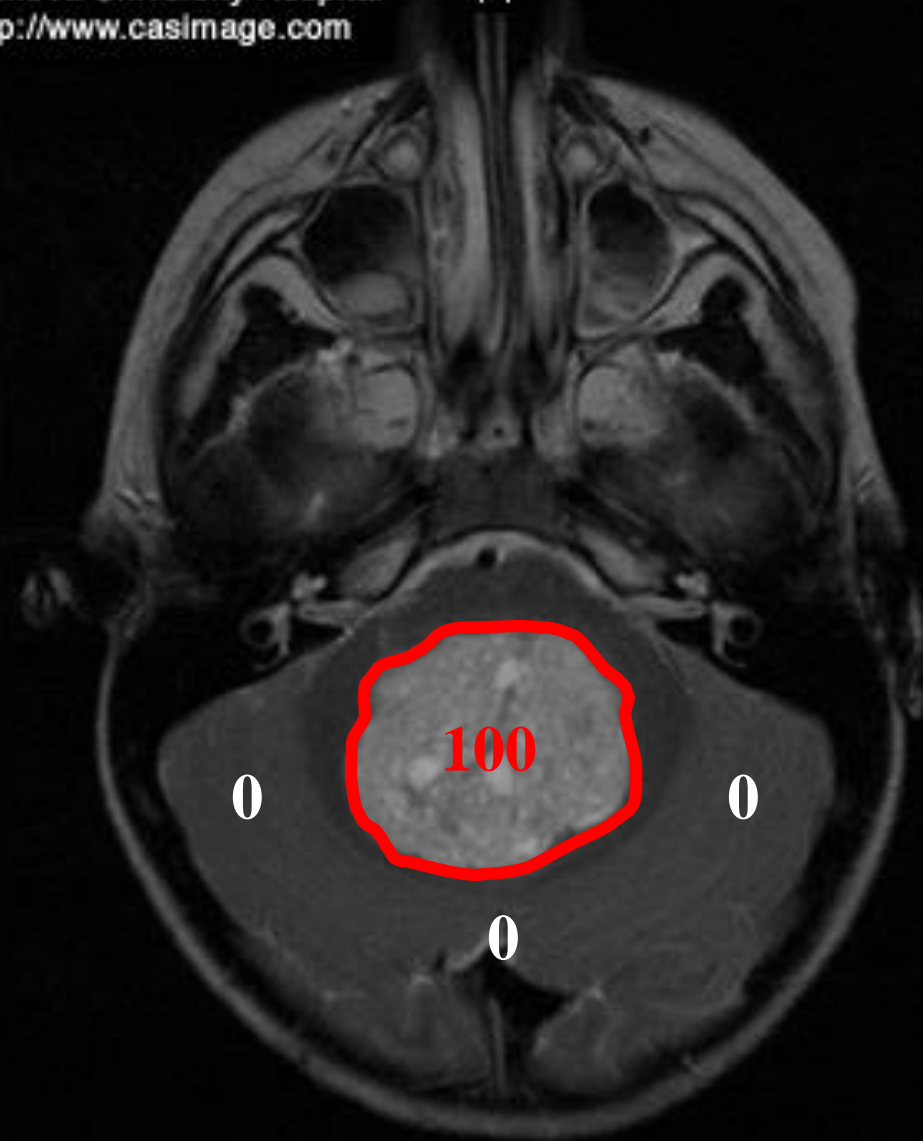
Protons vs Photons



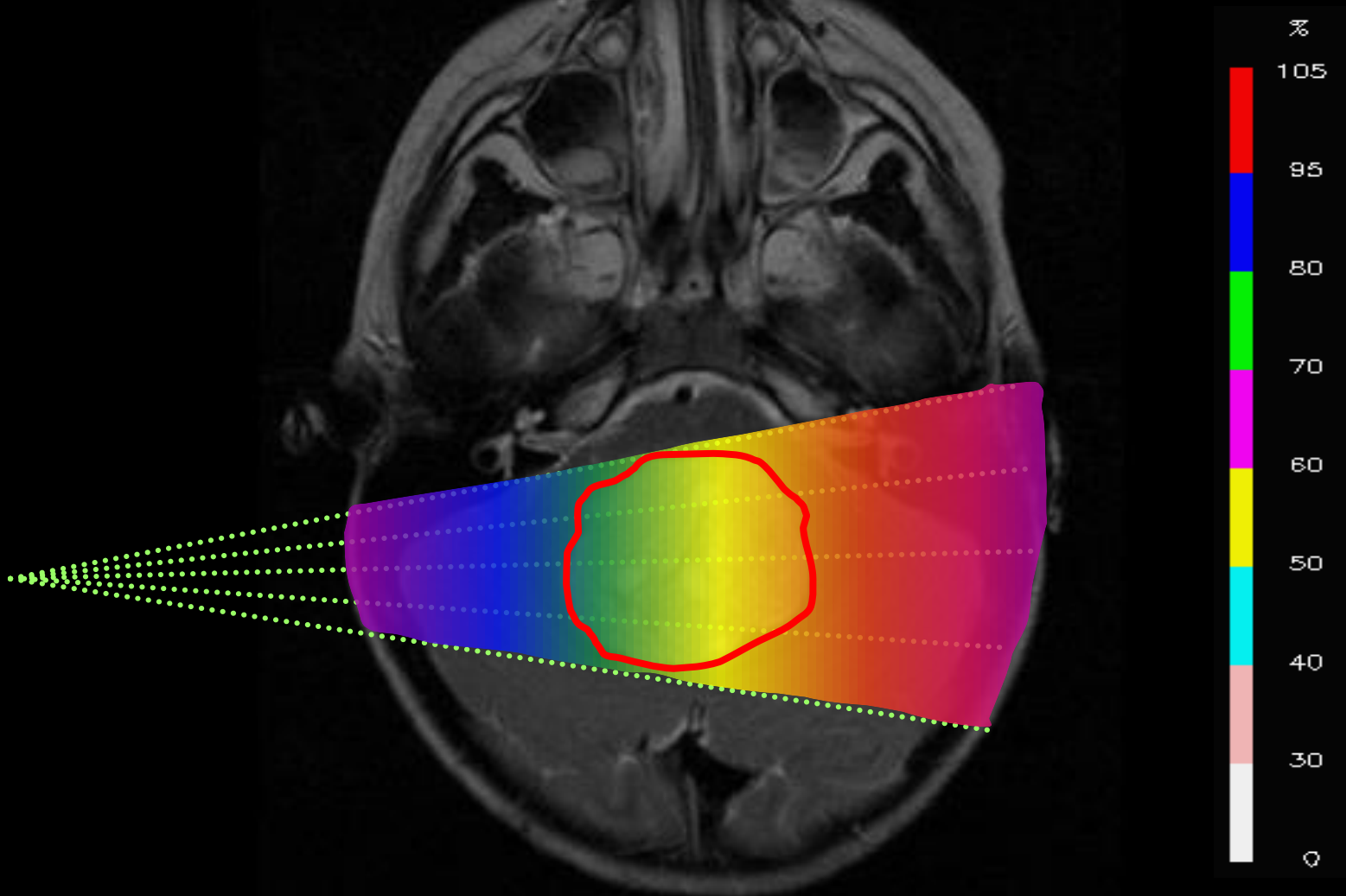


MRI: tumor of the Central Nervous System

A

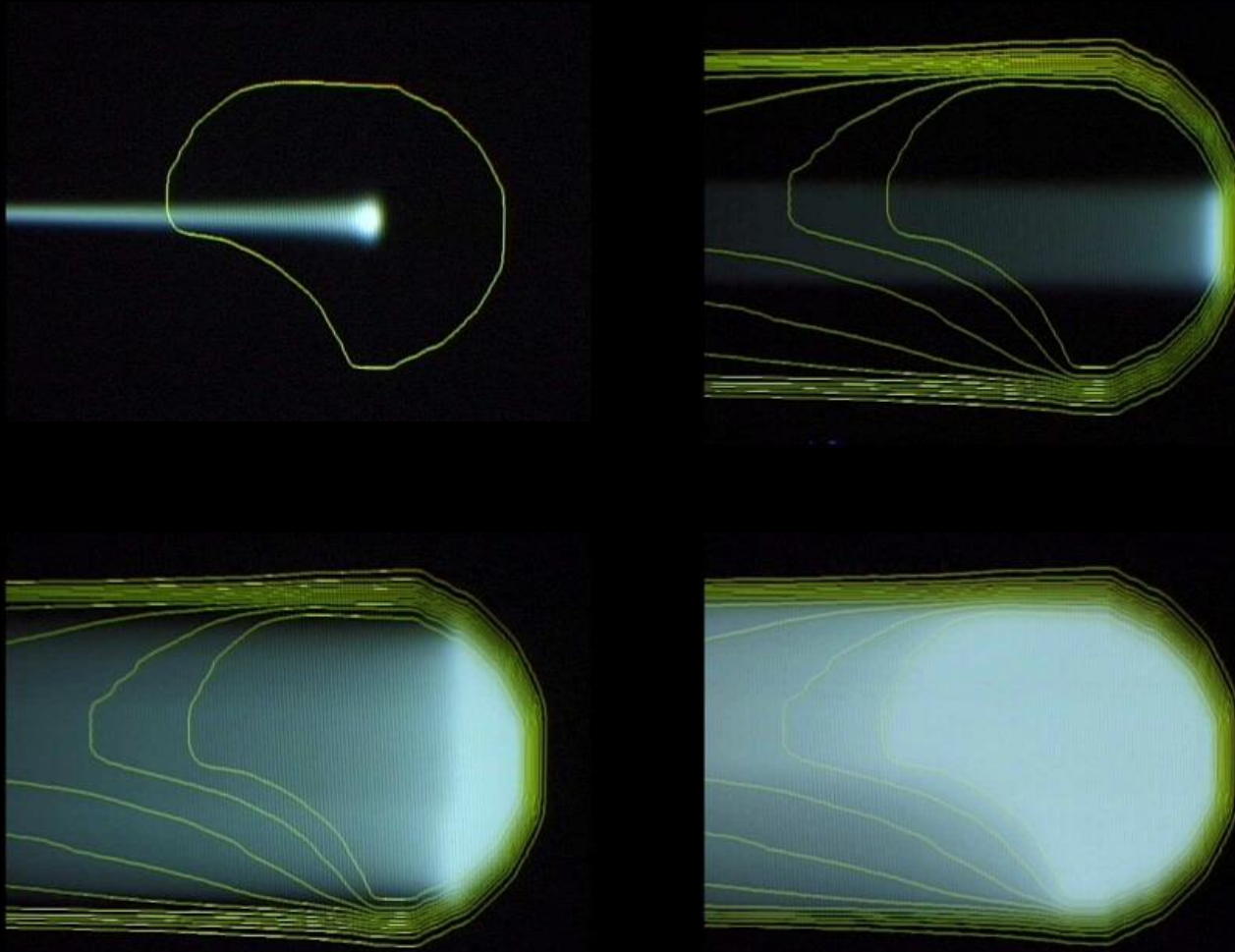


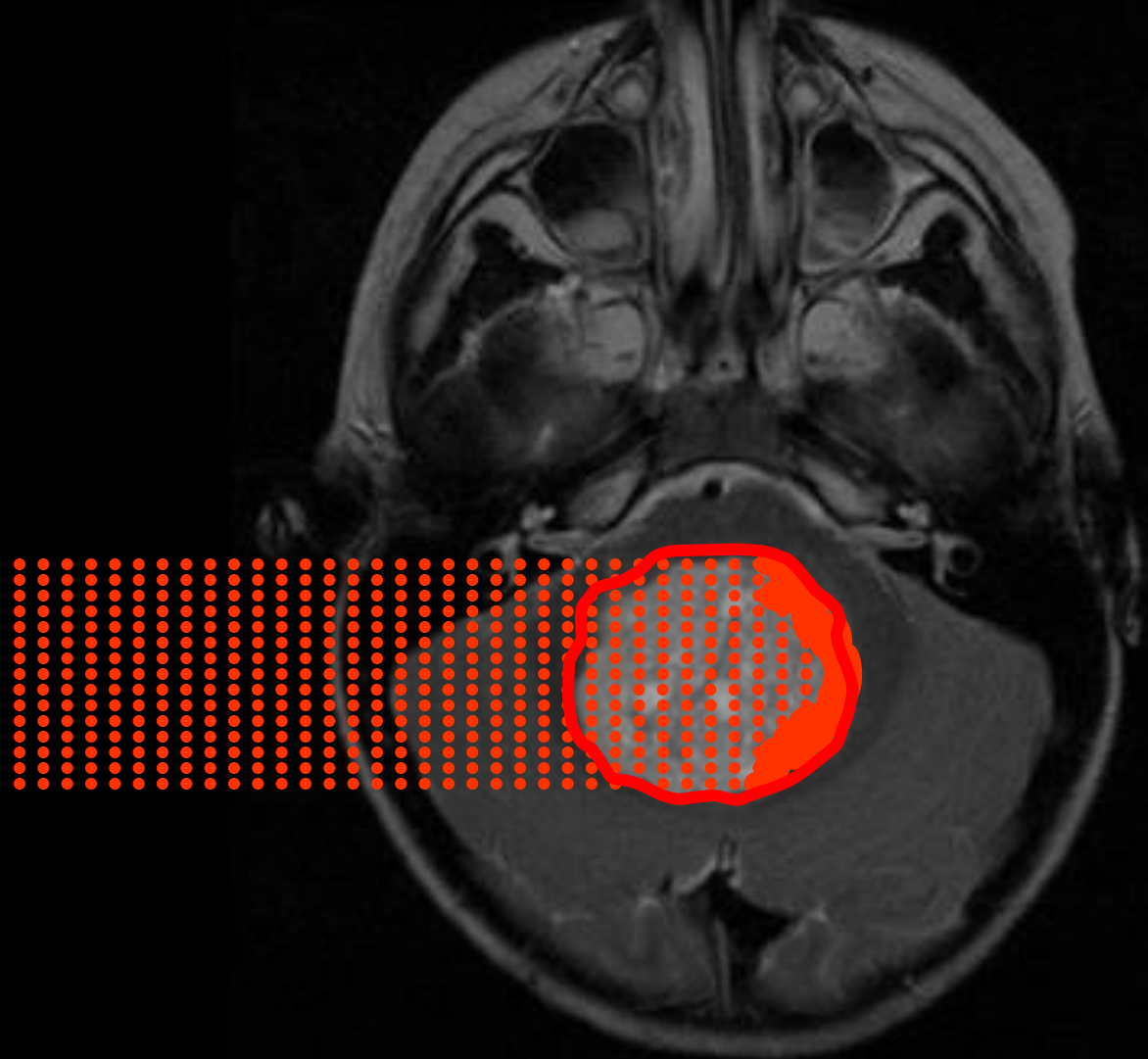
A



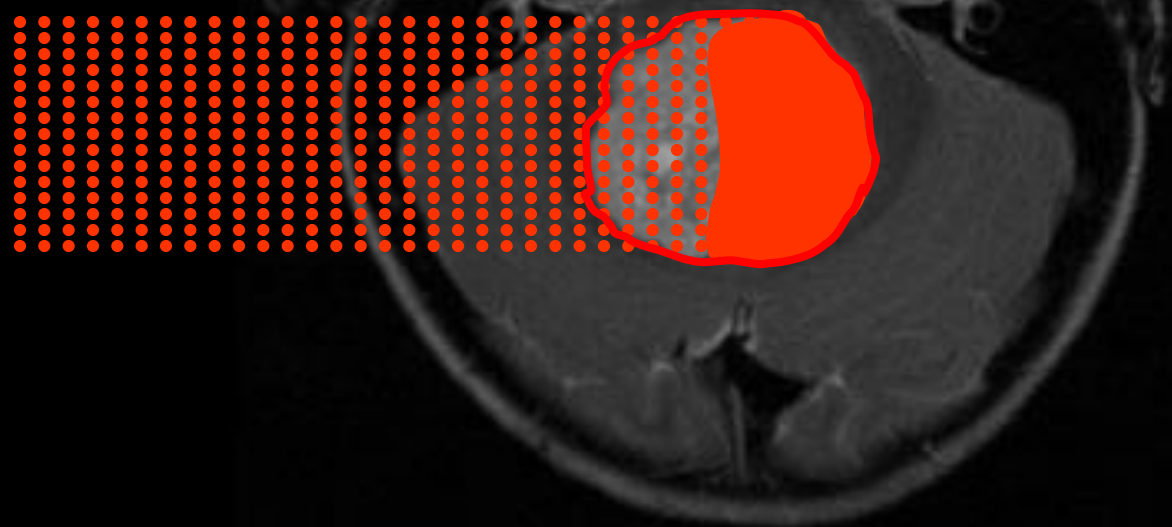
Conventional 3D conformal RT with photons

Protons: scanning the beam

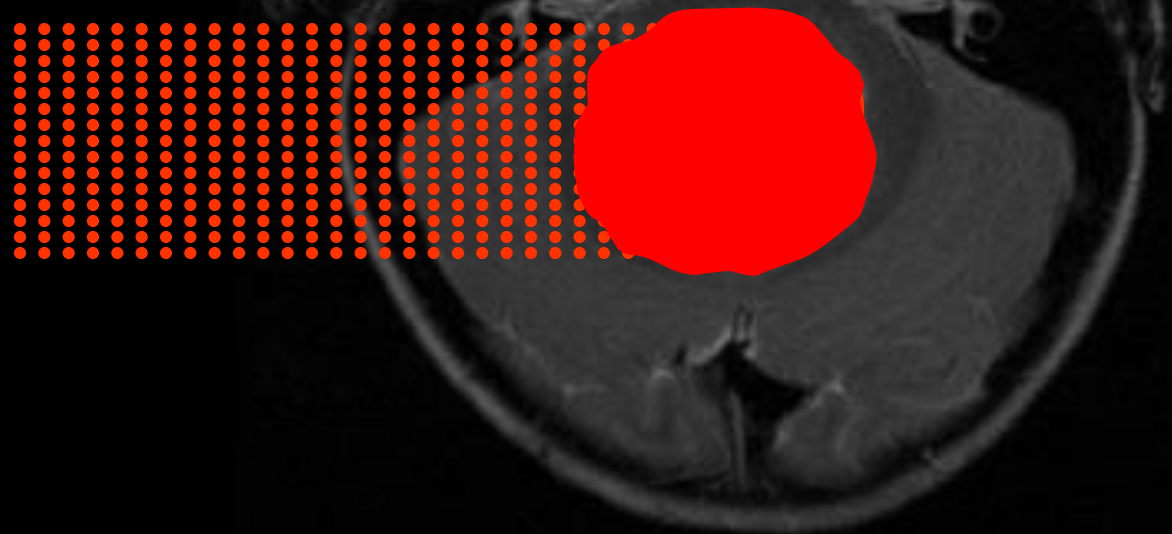




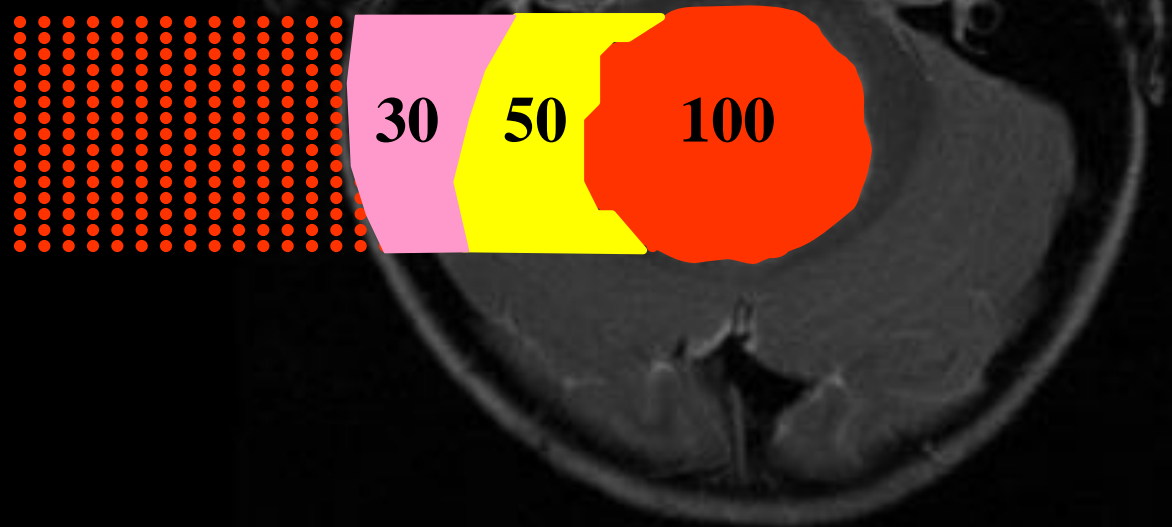
High precision RT with proton beams



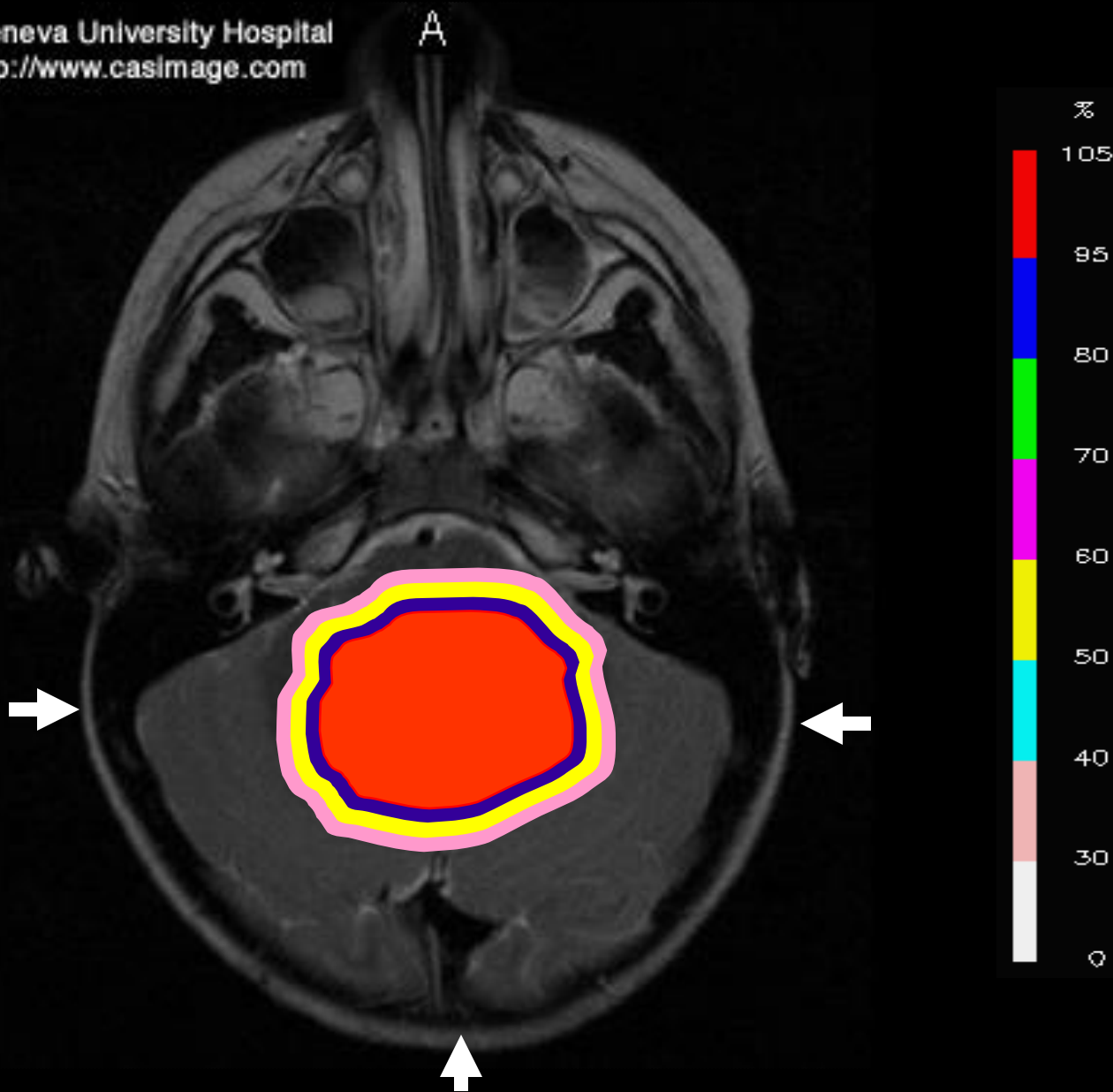
High precision RT with proton beams



High precision RT with proton beams



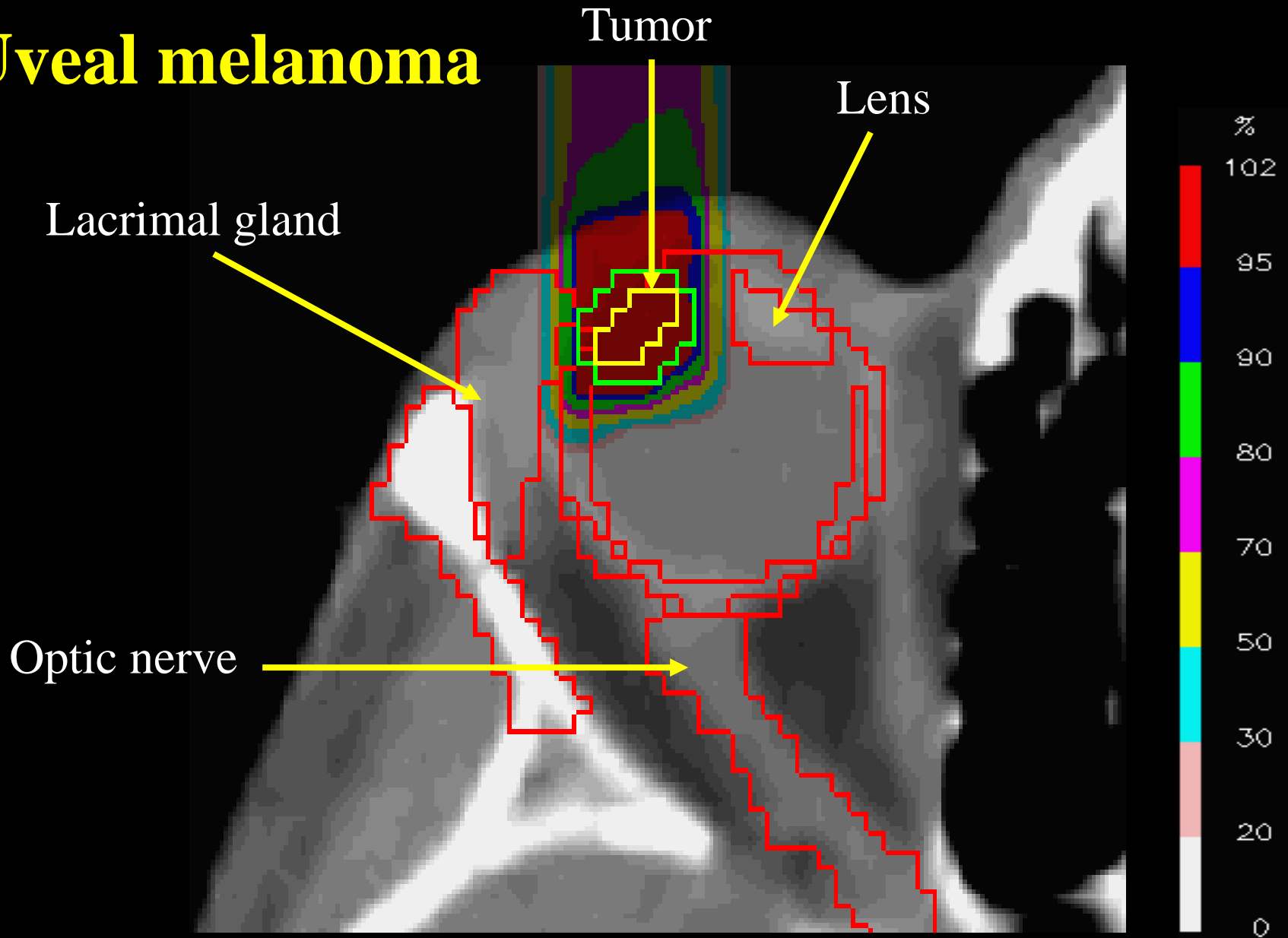
High precision RT with proton beams

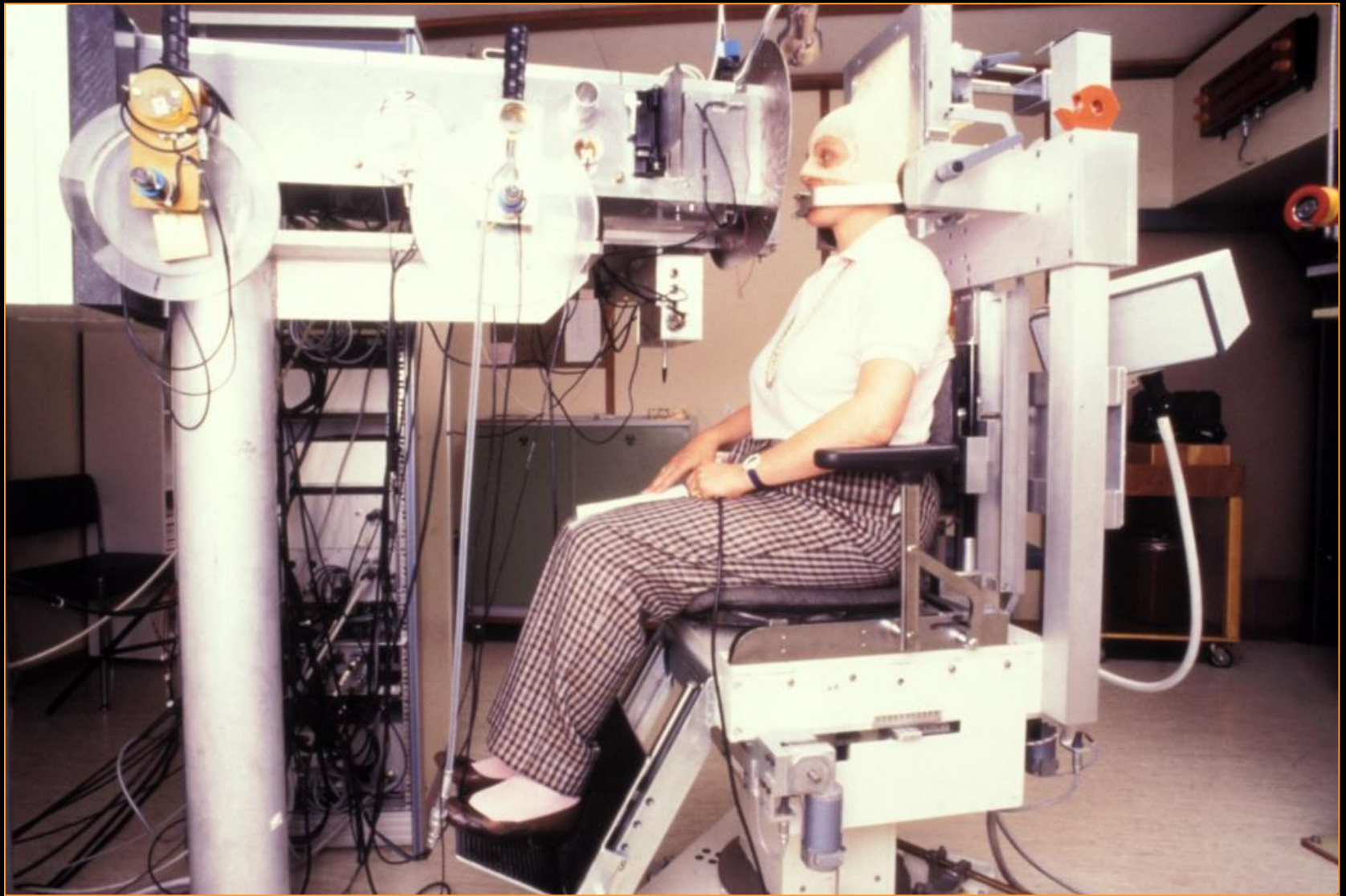


High precision RT with proton beams

Ocular melanomas

Uveal melanoma



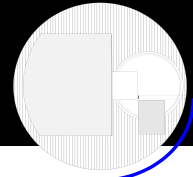


Uveal melanoma

- Since 1974, at *Harvard Cyclotron, Cambridge, Massachusetts*
- Since 1984, at *Paul Scherrer Institut, Villigen, Switzerland*

More than 10000 patients treated so far

Proton Therapy Program



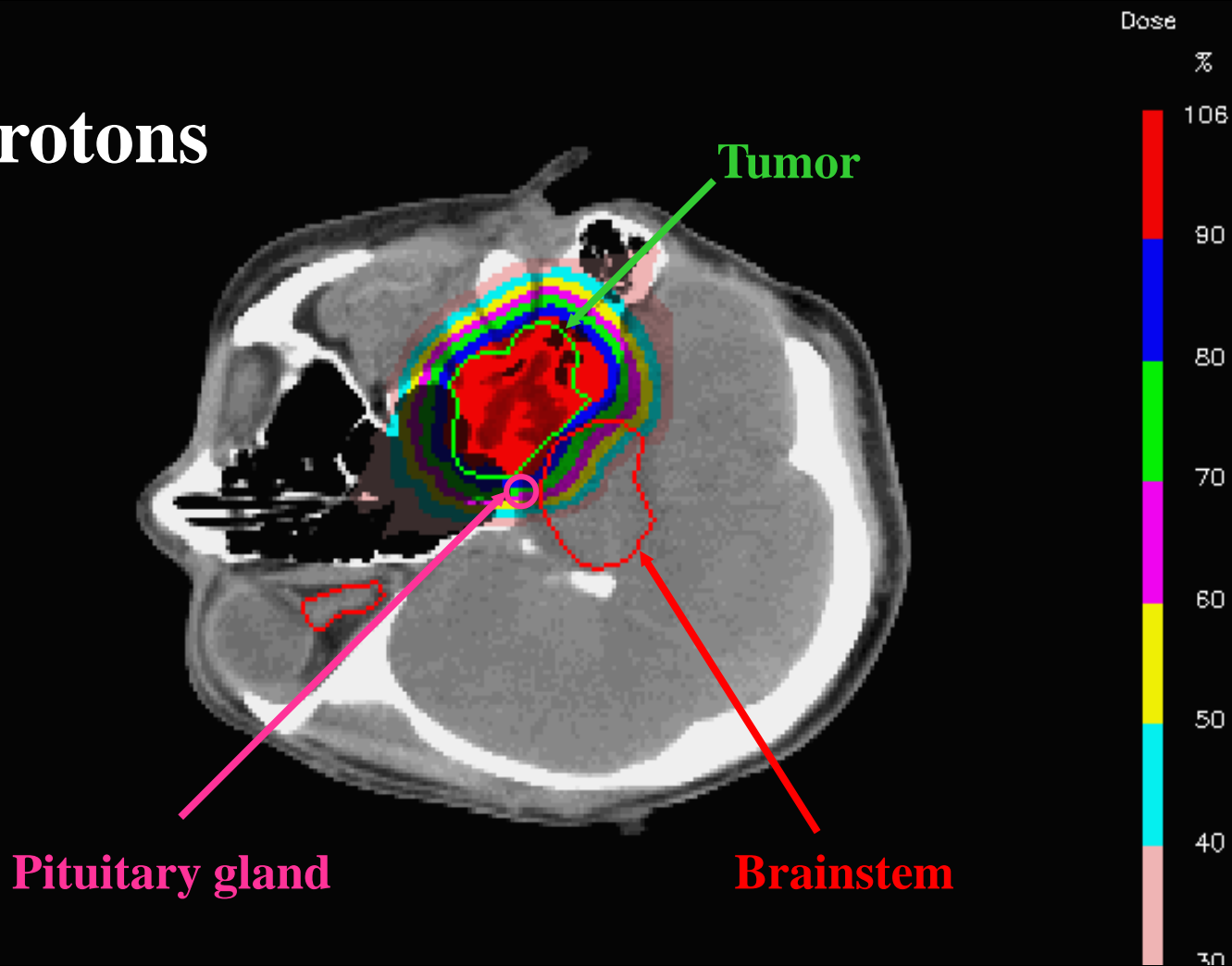
OPTIS – Programa de tractament de tumors oculars al PSI

- 1. Outcome** 98% of overall local control
- 2. Eye retention** 100% for small tumors,
90% for large tumors
- 3. Vision** Preserved in 50% of patients

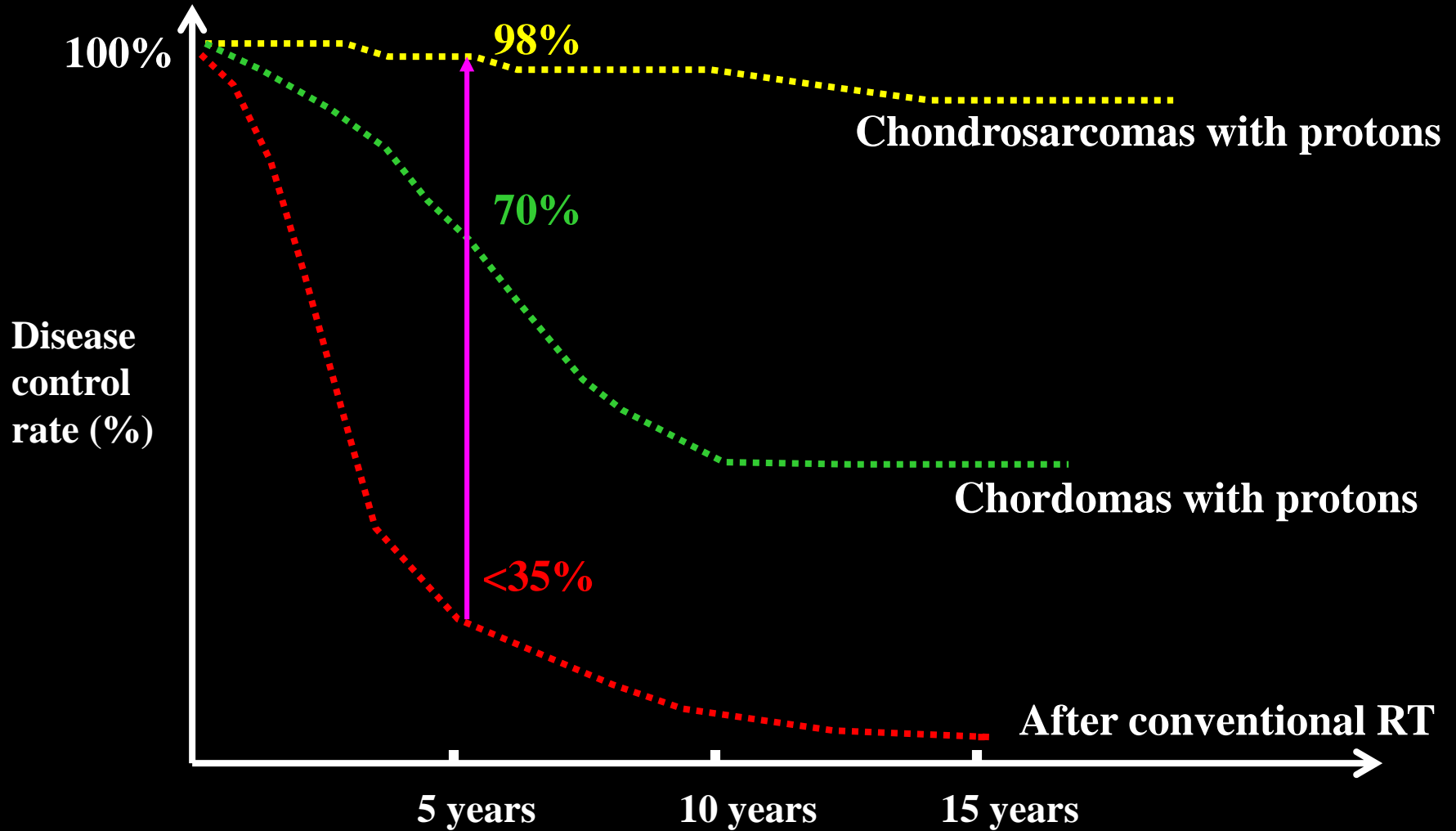
Base of skull tumors

Base of skull chondrosarcoma in a 22 year-old female

Protons



Base of skull tumors



Summary

- High quality RT will likely continue to play an important role in the curative treatment of cancer in years to come.
- Better imaging and 3-D treatment planning have helped to safely escalate the dose to the tumor (by simultaneously reducing the dose to surrounding normal tissues).
- Thus, IM X-ray and proton beams may greatly improve local control rates, simultaneously reducing morbidity.