



*BCNM 2015*


**SPECT/CT**  
**INSTRUMENTATION AND**  
**CLINICAL APPLICATIONS**

**Daniela Miladinova, MD PhD**

**Institute of Pathophysiology and Nuclear Medicine**  
**Academ.Isak S.Tadzer, Faculty of Medicine,**  
**University "Ss Cyril and Methodius"**

Medical Physics Workshop  
PET Development and Applications

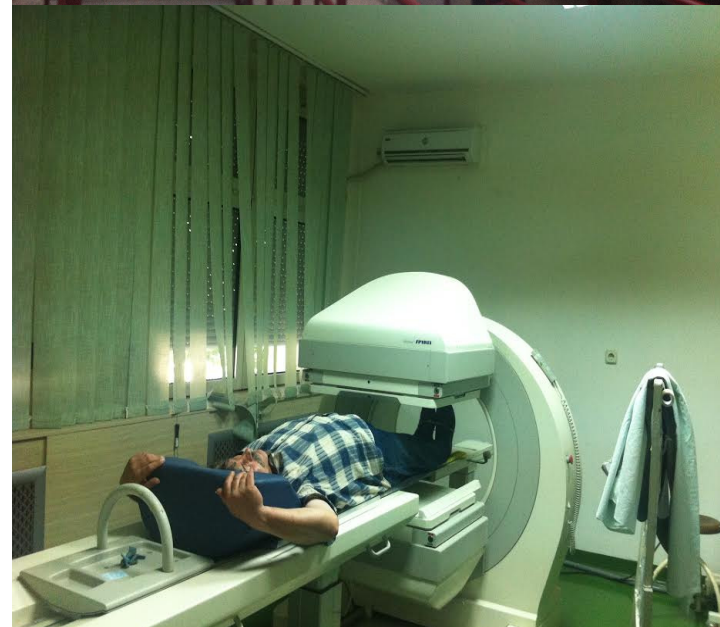Ohrid, 6<sup>th</sup> september 2015




[www.ukim.edu.mk](http://www.ukim.edu.mk)



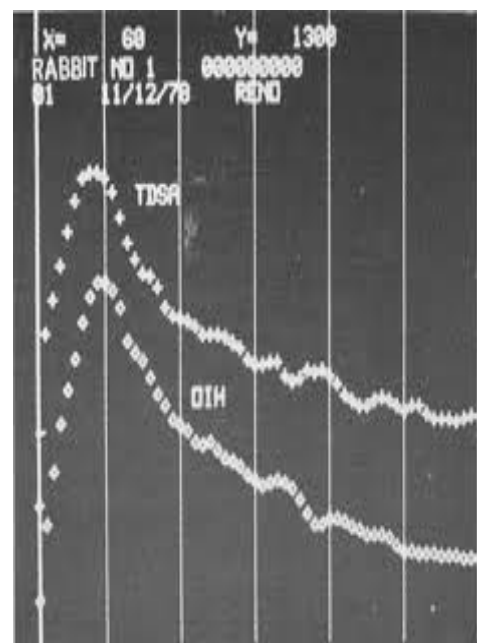
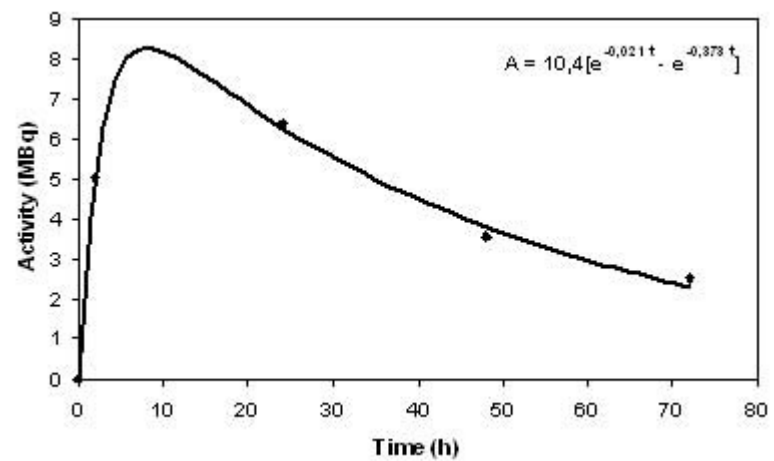
[www.medf.ukim.edu.mk](http://www.medf.ukim.edu.mk)




## SCINTILATION PROBES



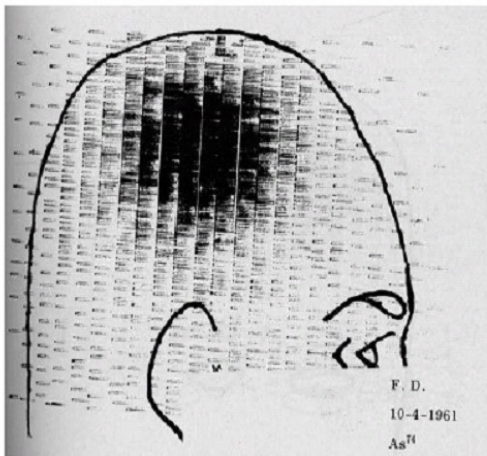
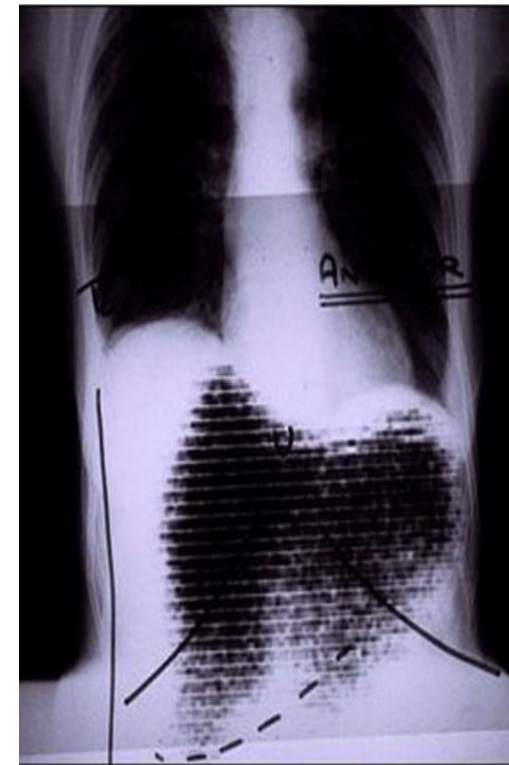

## TIME ACTIVITY CURVES

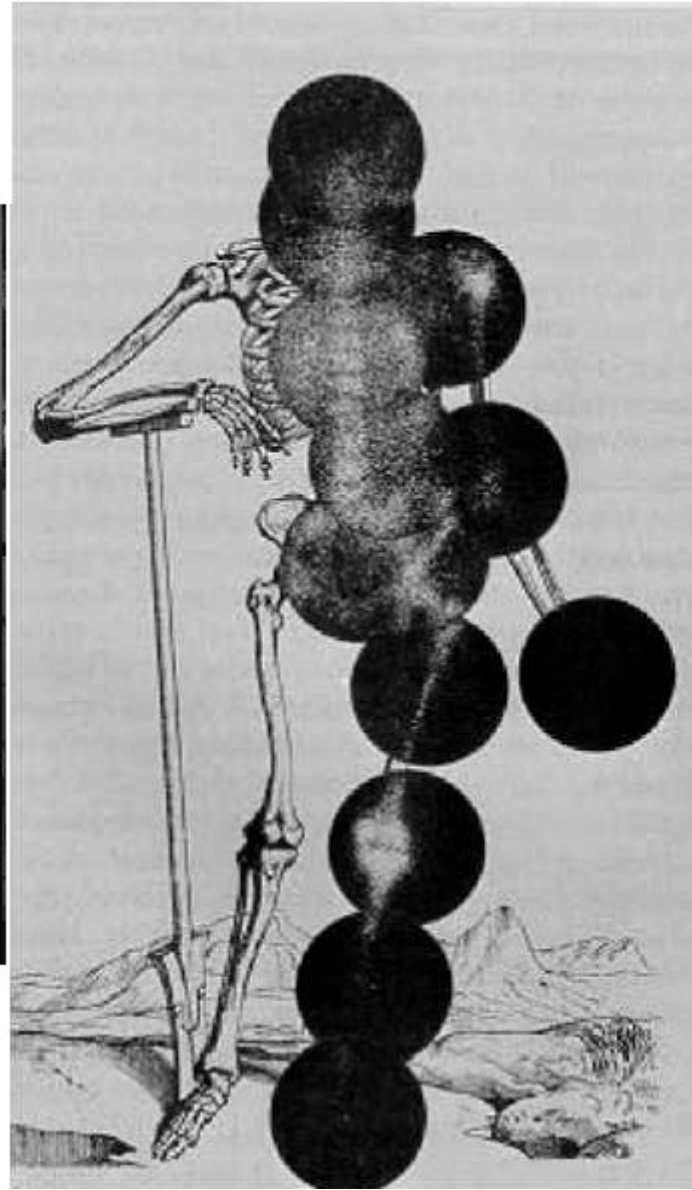



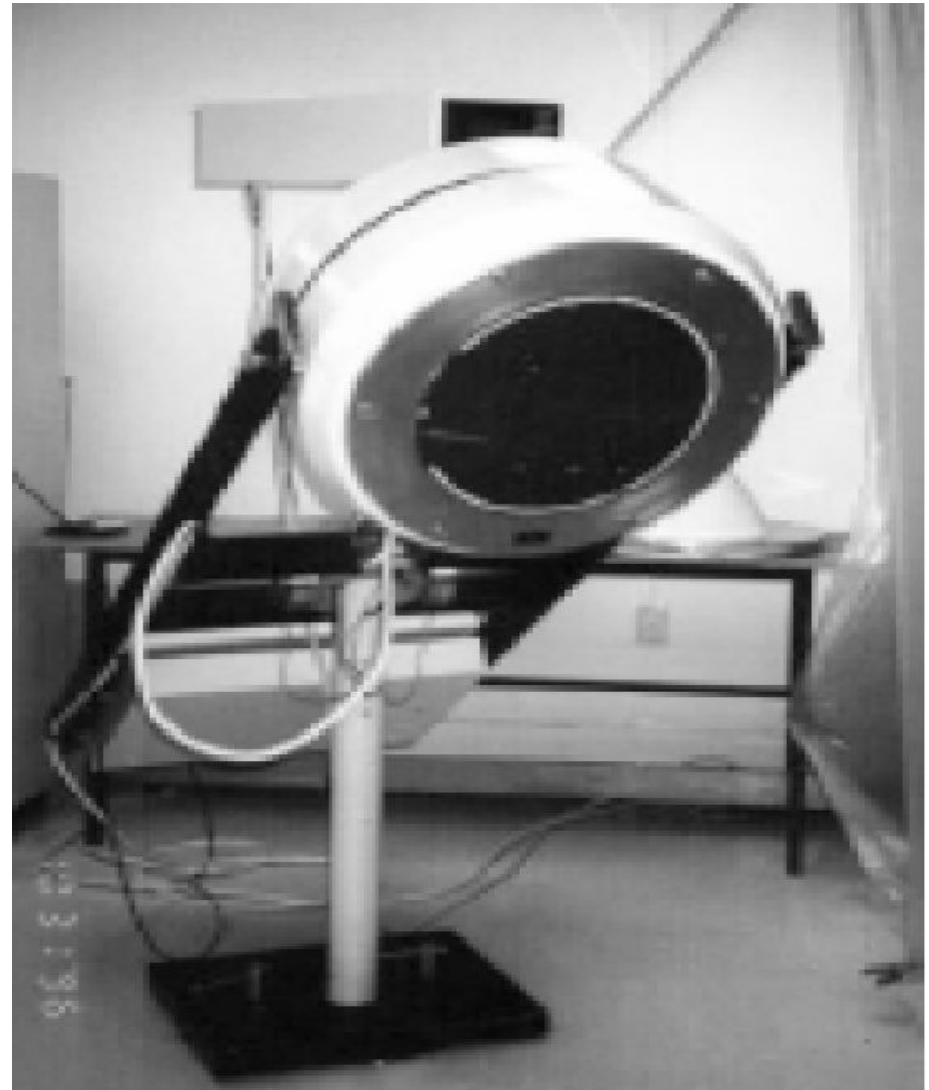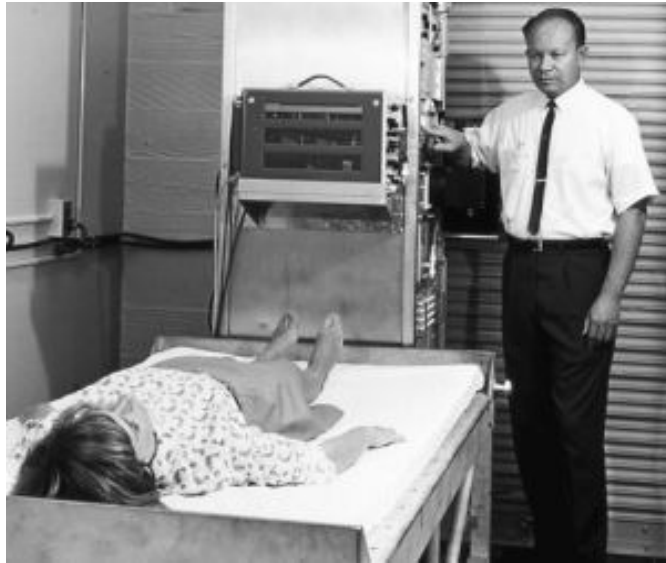





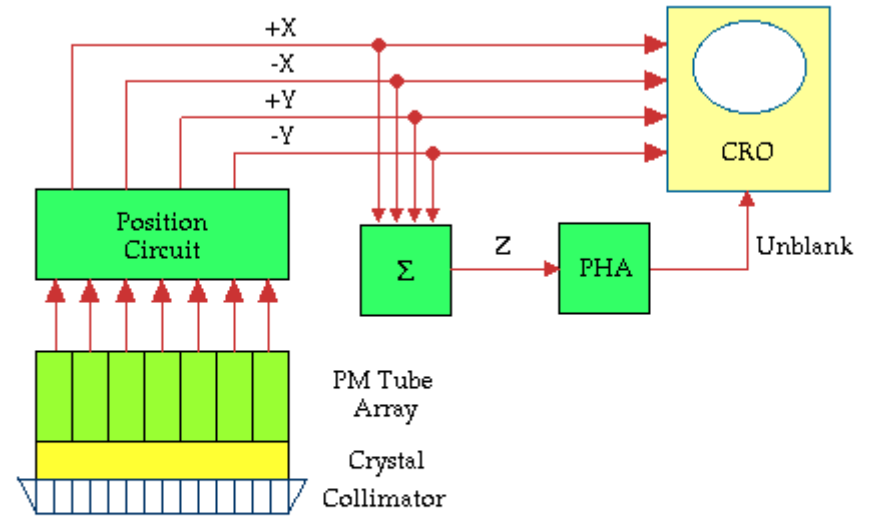
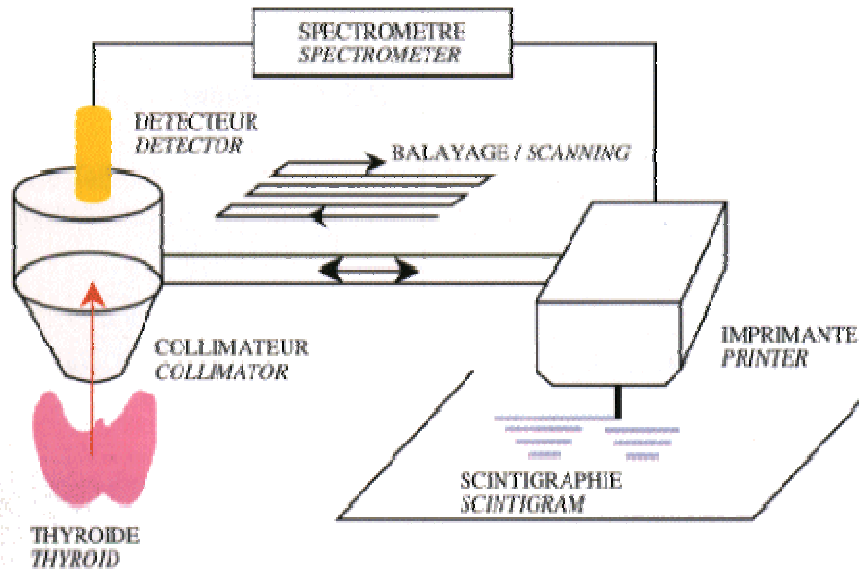

## RECTILINEAR SCANNER

## CORRELATIVE IMAGE




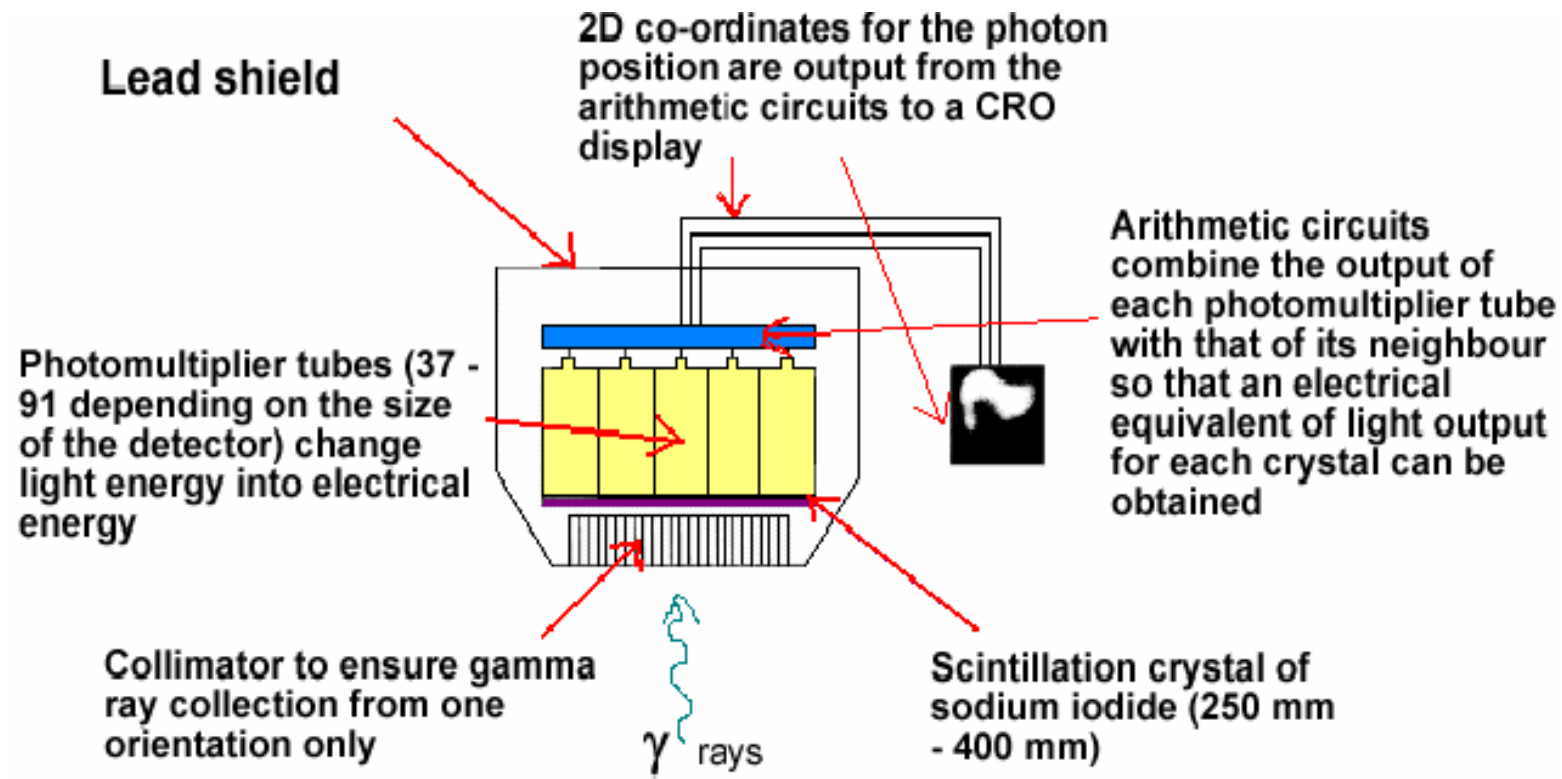


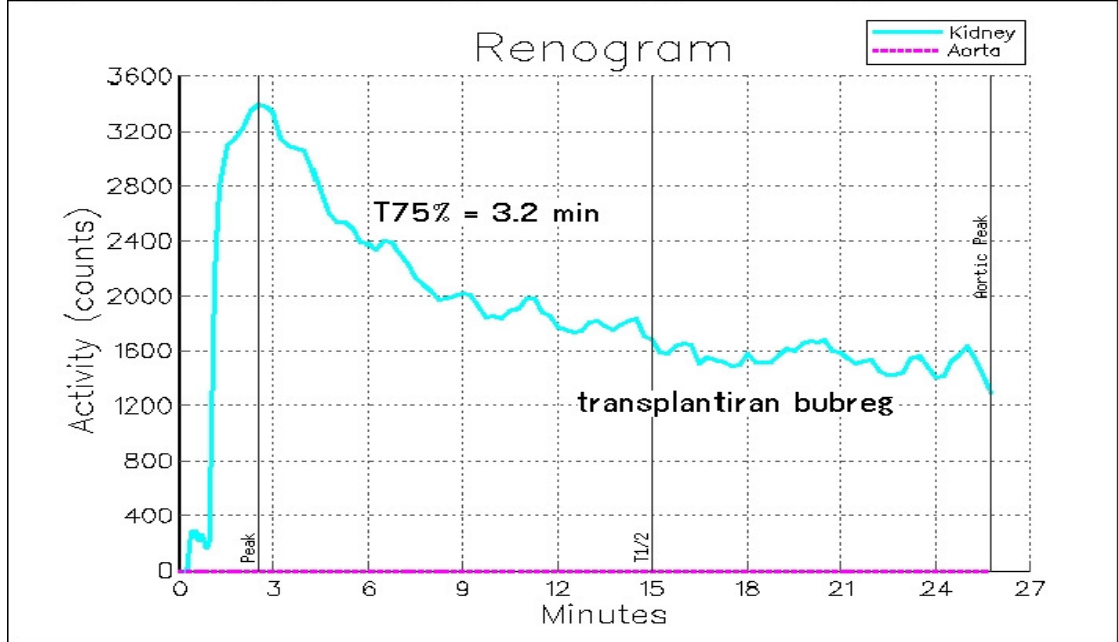
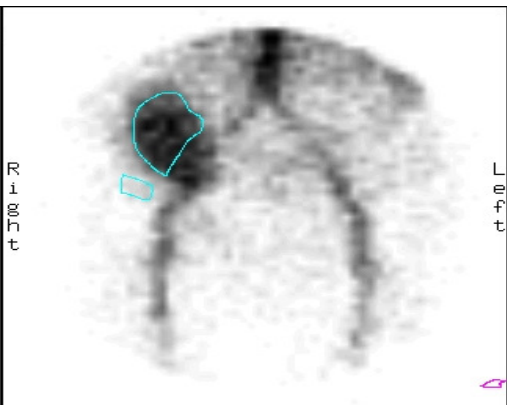
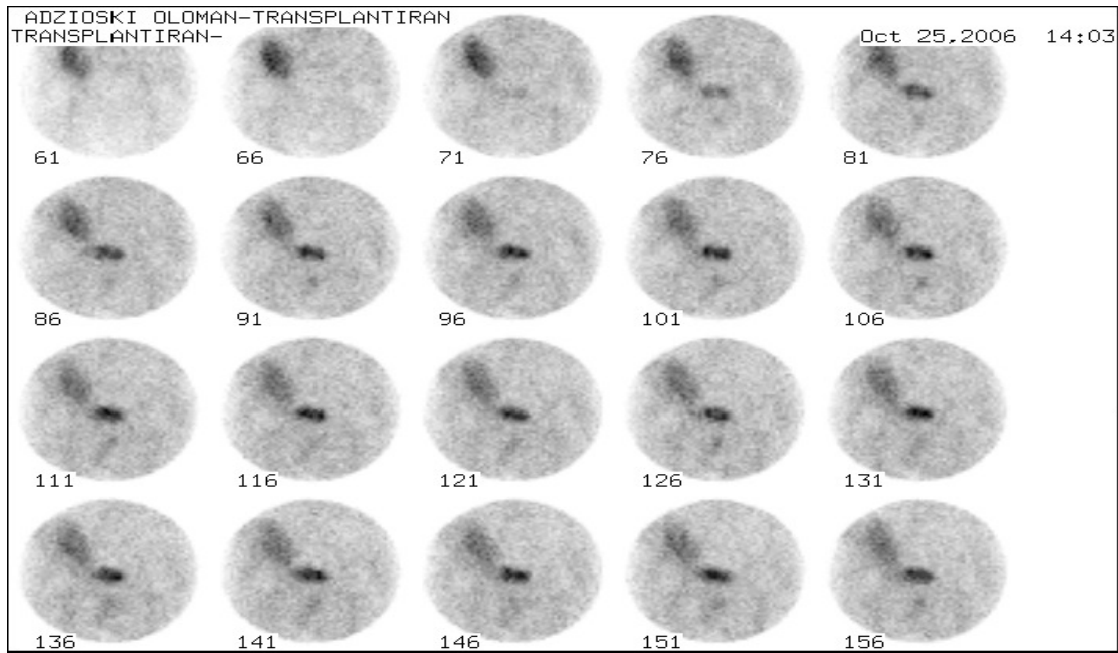





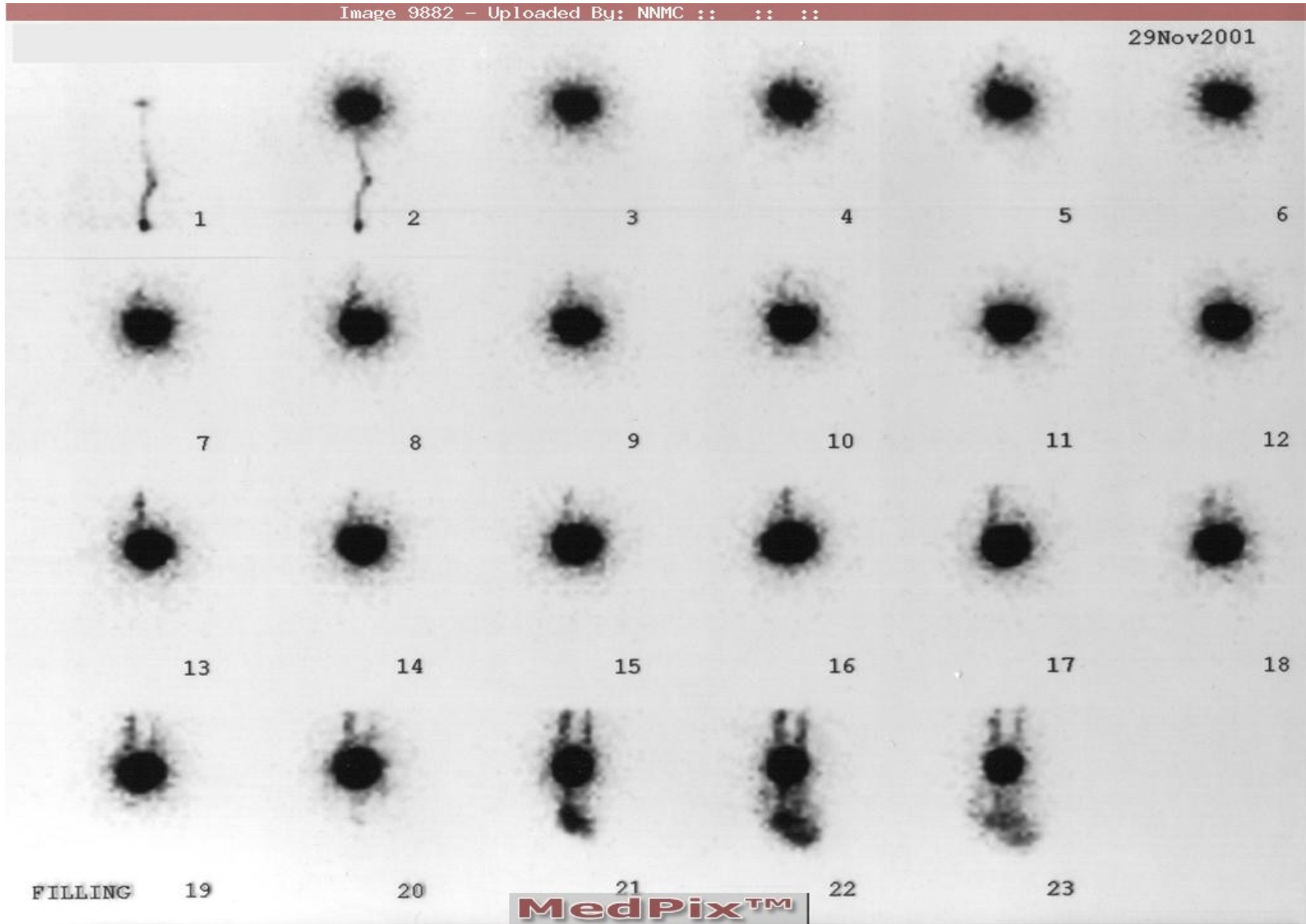

Organ containing  
radiopharmaceutical

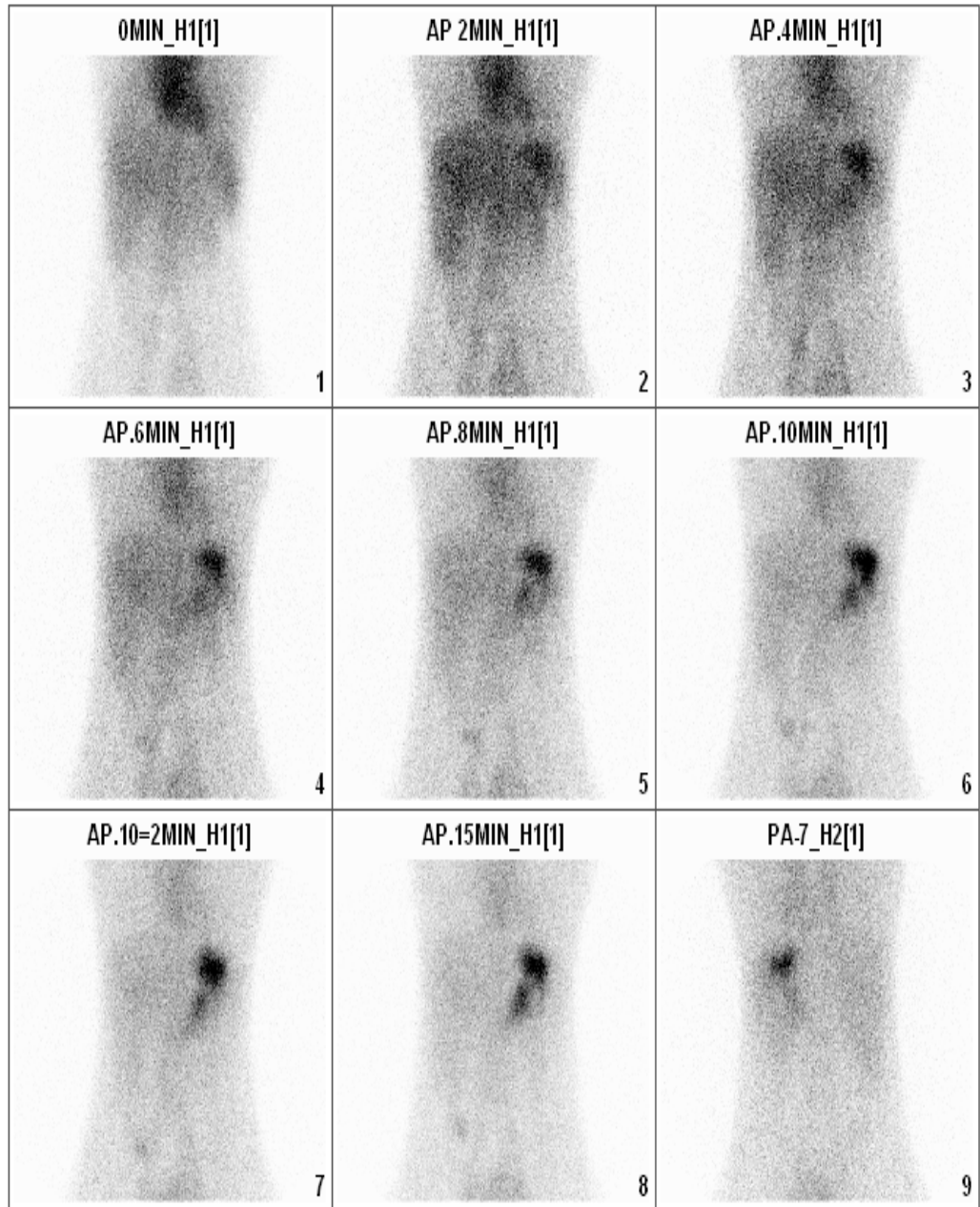
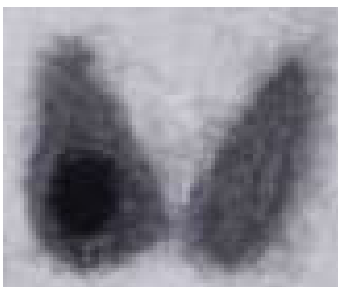
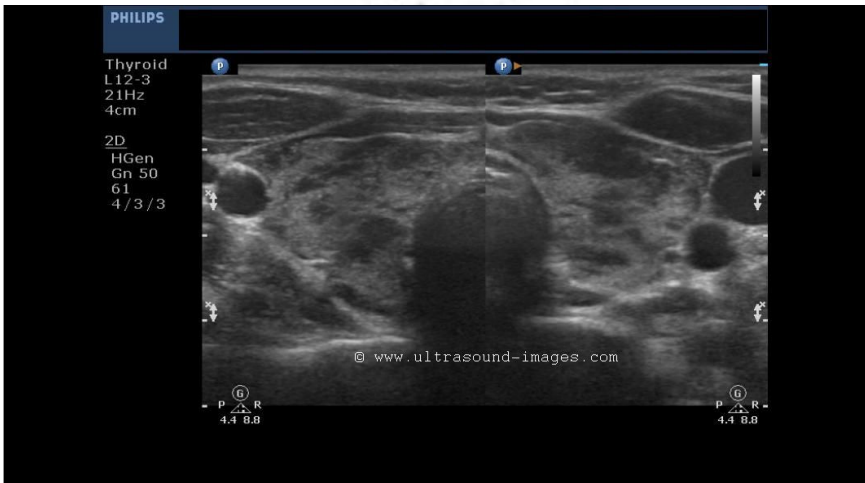
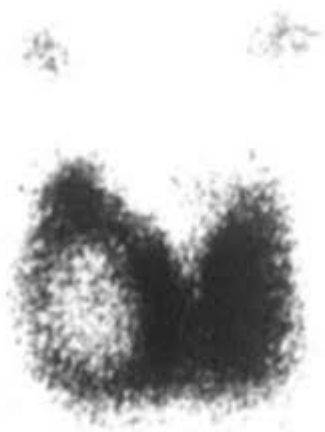

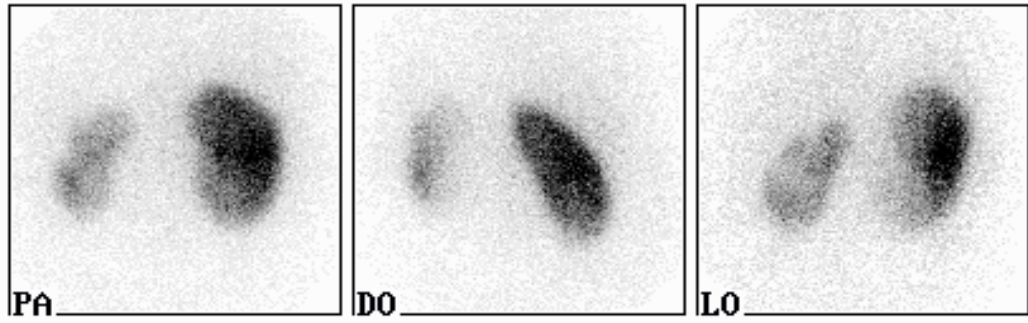
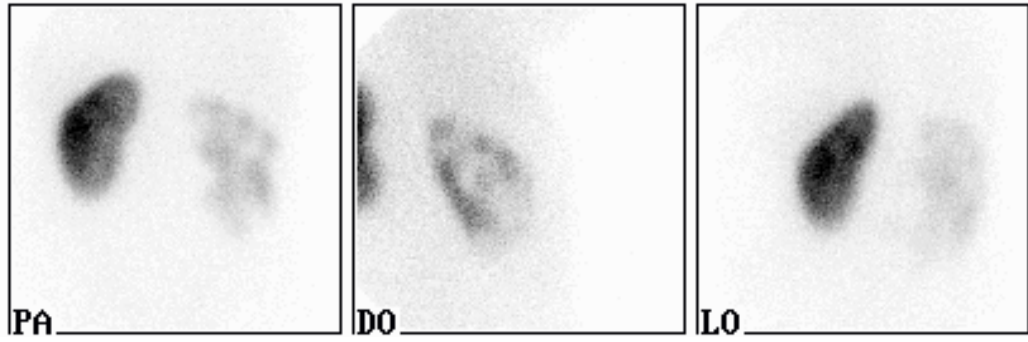
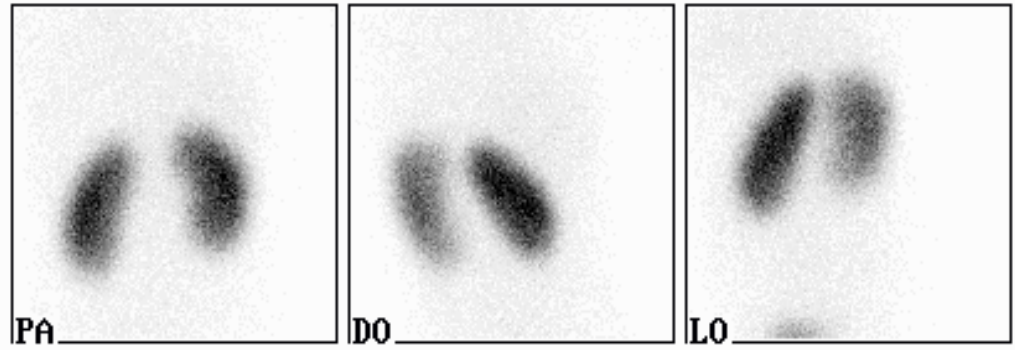



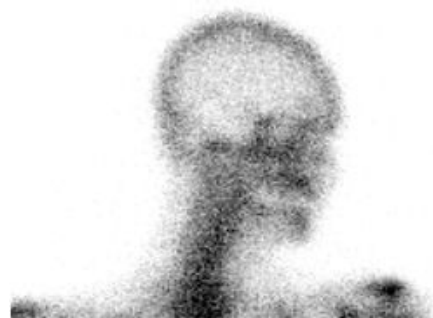

Adzioski Oloman  
Transplantiran bubreg  
25-10-2006

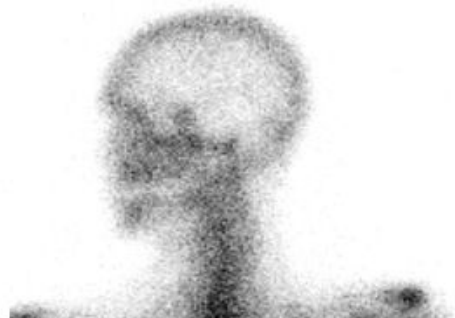



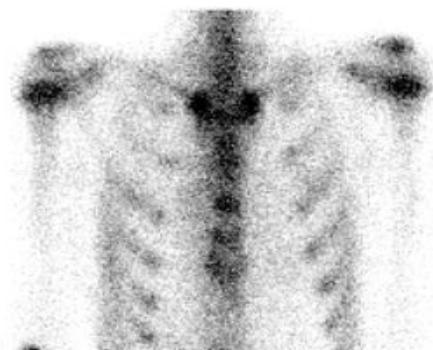




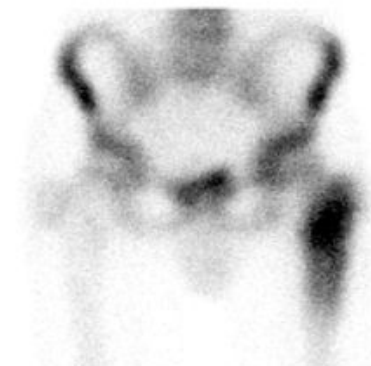DL GLAVA 150K



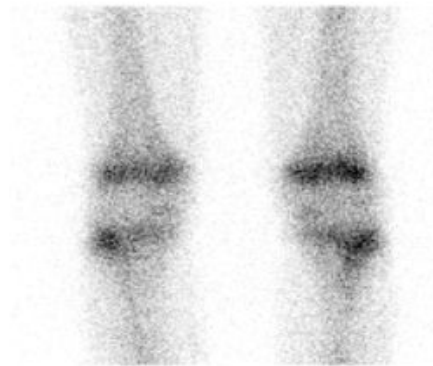
LL GLAVA 150K



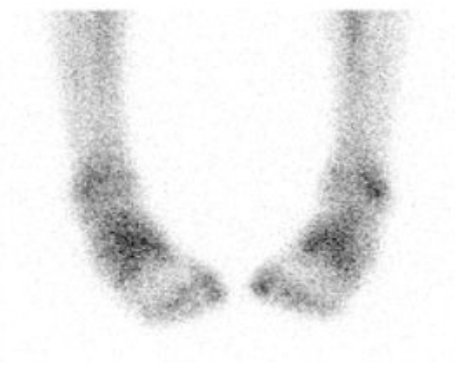AP RAMENJA 300K



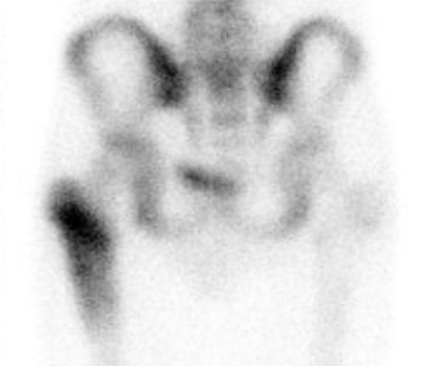AP KARLICA 799K



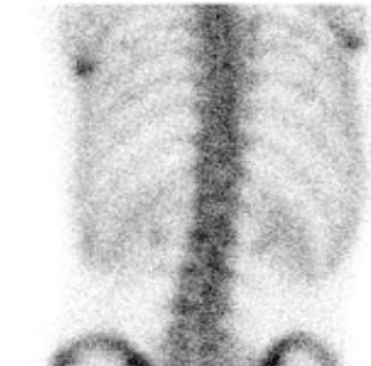
AP KOLENA 149K



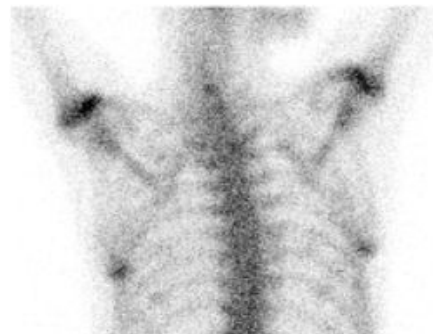AP STAPALA 100K



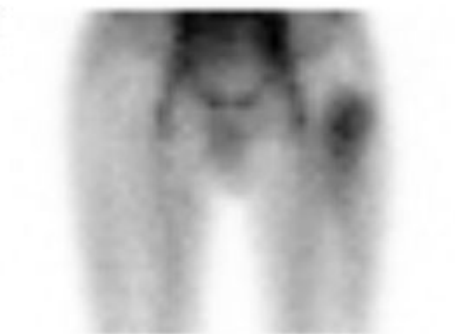
PA KARLICA 799K



PA KICMA 301K



PA RAMENJA 300K



pool 496K




Patient Name: azemi, durmiss

Patient ID: 2487

Study Name: Skelet

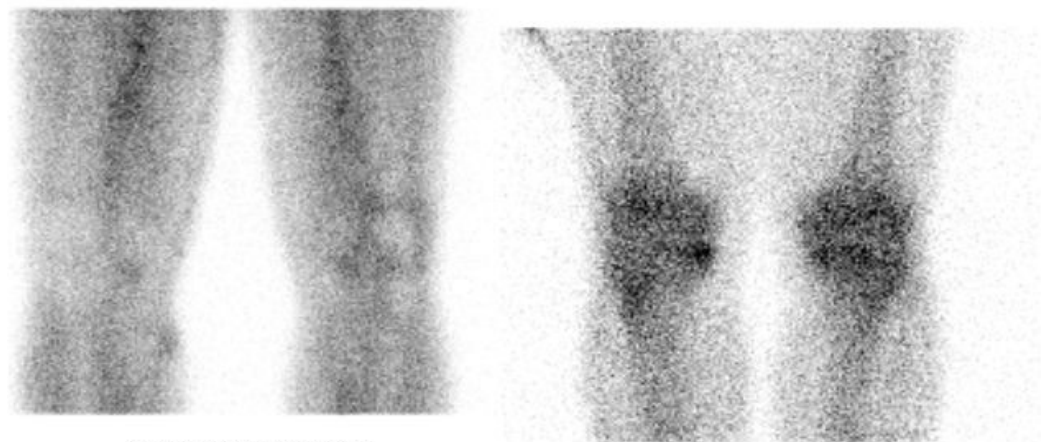
Study Date: 04.02.2005

vaskularna 04.02.2005



statici 04.02.2005

<static> 04.02.2005



pool 500K Duration:134sec

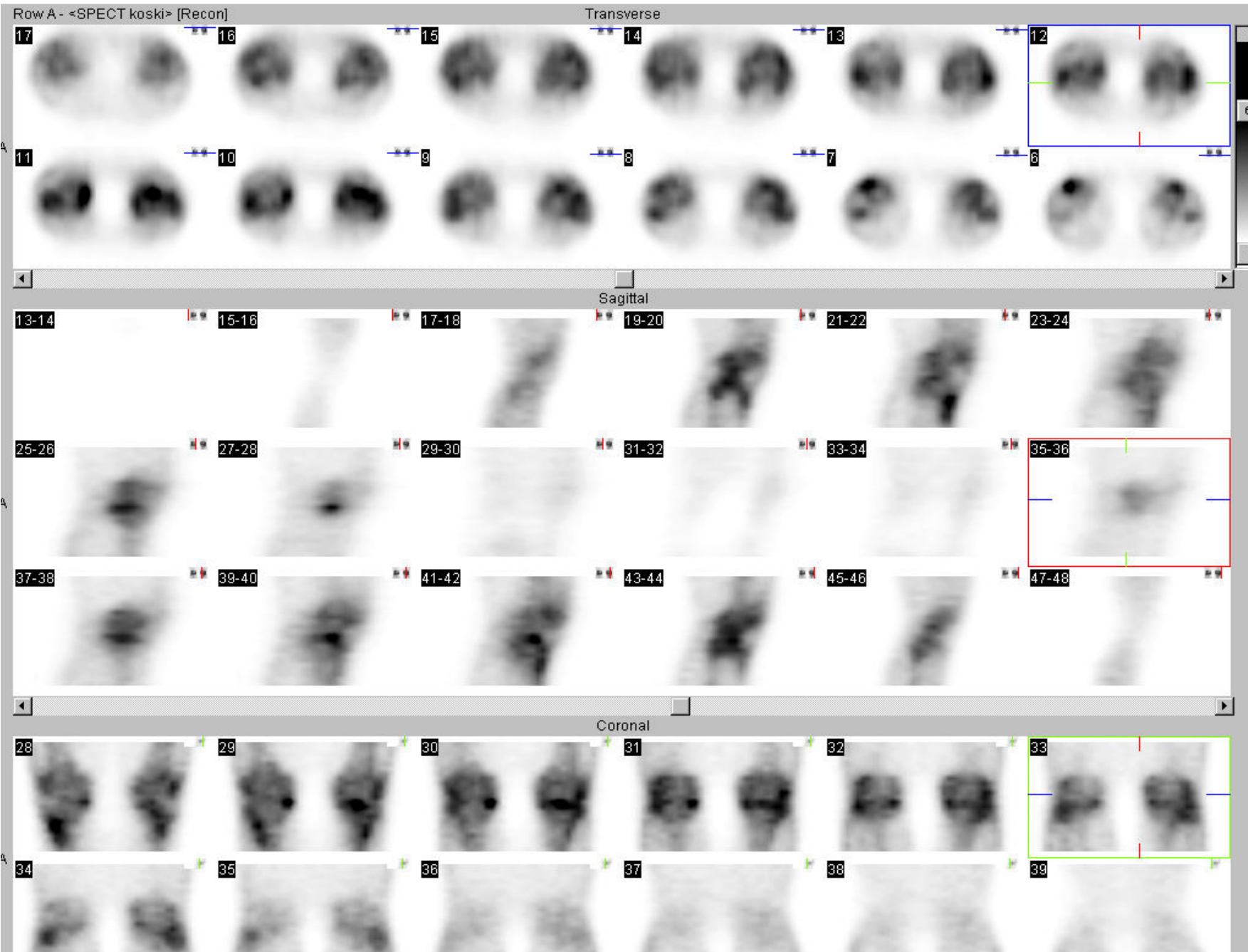
AP 152K Duration:124sec

Patient Name: azemi, durmiss

Patient ID: 2487

Study Name: Skelet

Study Date: 04.02.2005







**Transverse**  
ANT  
R I G H T      L E F T  
POST

47      48      49      50      51

◀ ▶

**Sagittal**  
HEAD  
P O S T      A N T  
FEET

63      64      65      66      67

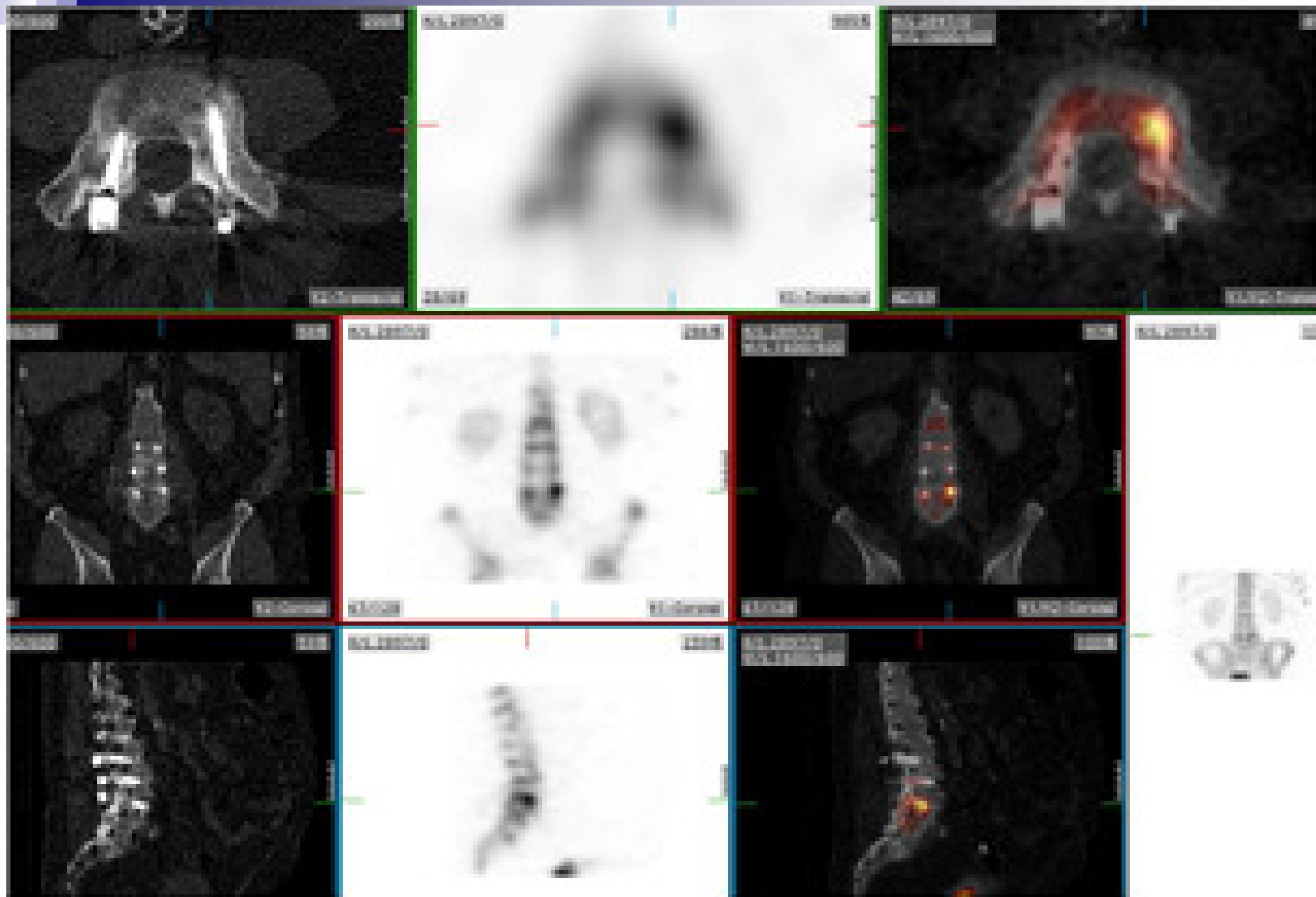
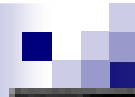◀ ▶

**Coronal**  
HEAD  
R I G H T      L E F T  
FEET

54      55      56      57      58

◀ ▶

↶ ↷



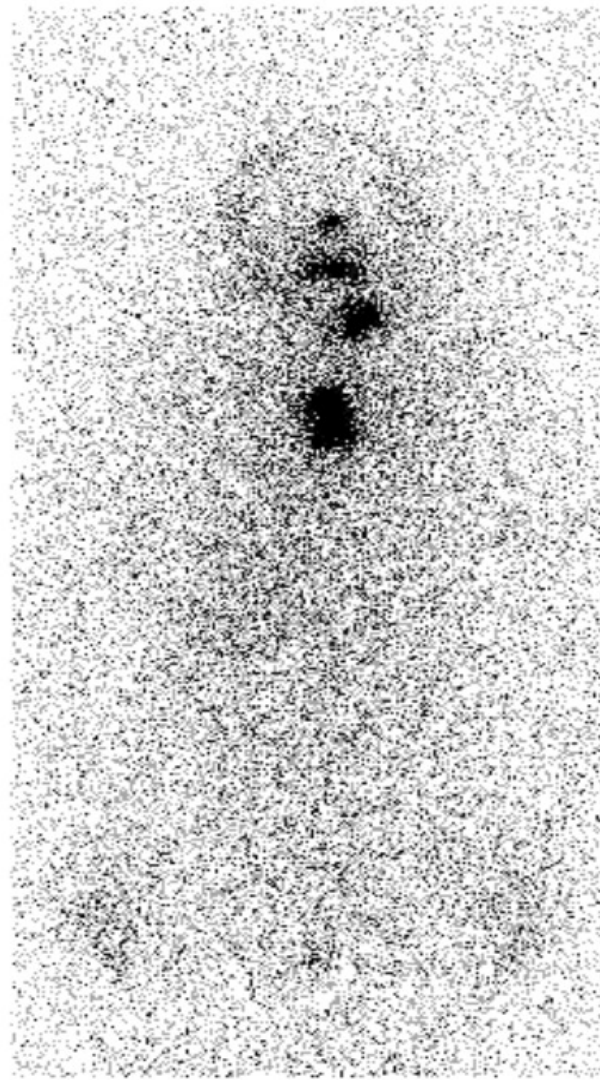



Patient Name: josifoska, dobrica

Patient ID: 13665

Study Date: 04.03.2011

Study Time: 08:37:24





# SPECT/CT

- SPECT principles
- Iterative SPECT reconstruction
- Advantage of SPECT/CT hybrid imaging
- Current clinical applications of SPECT/CT



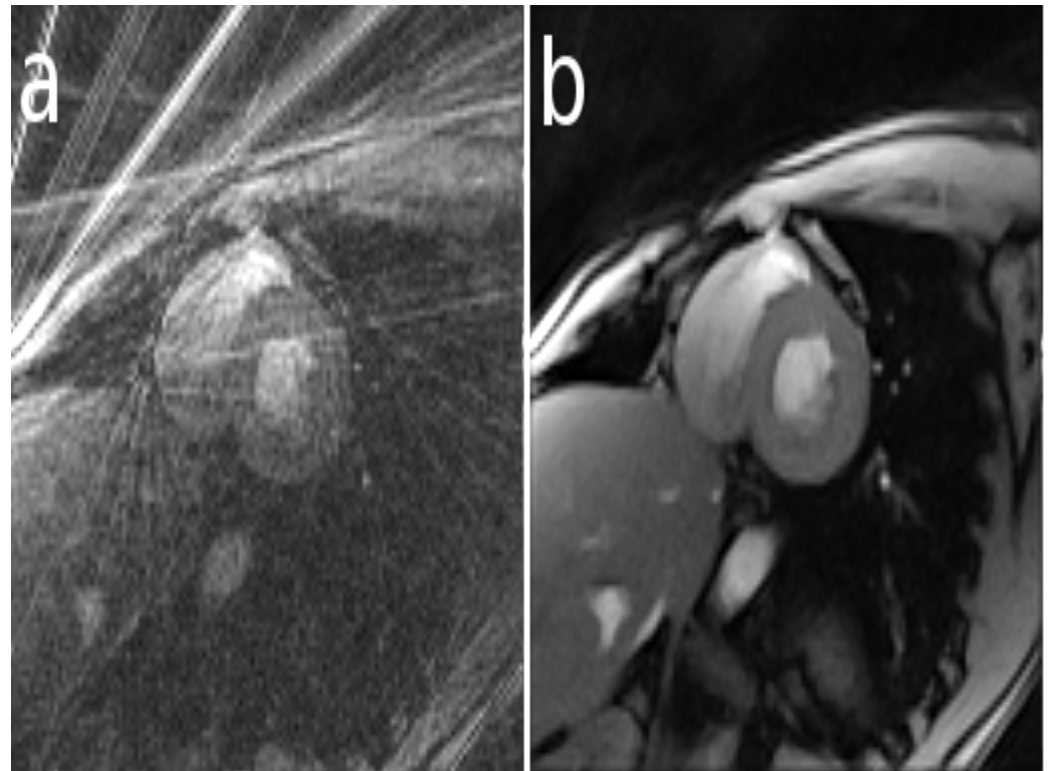
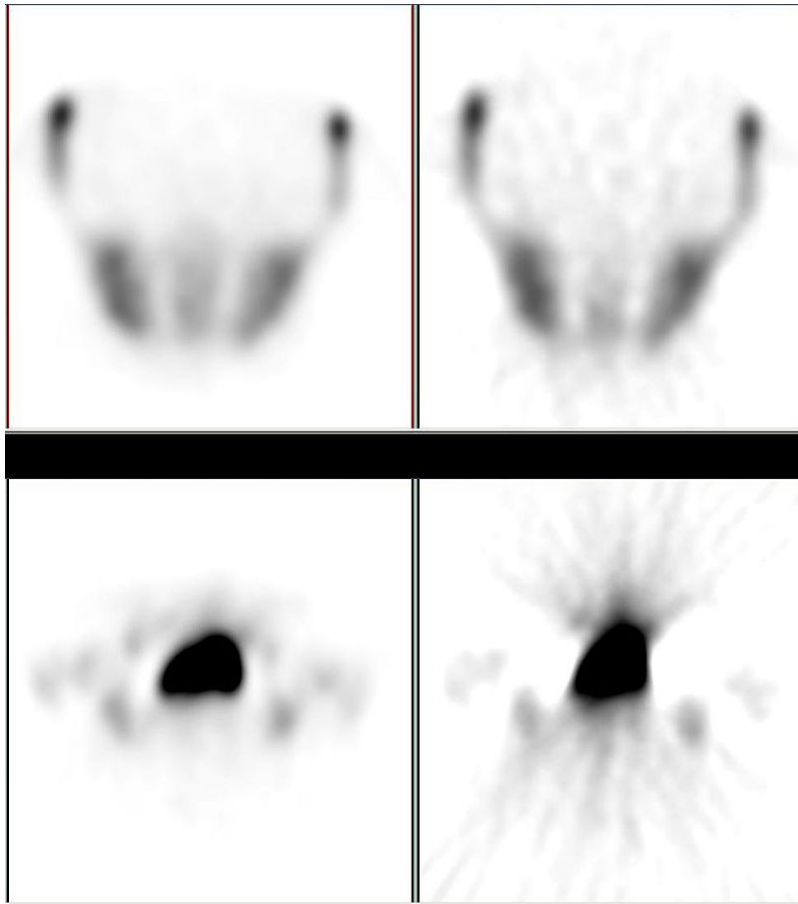
# SPECT principles

- Flat panel *head* used for detection
- Acquisition time depending on
  - detector, collimator
  - size of the imaging region
  - amount of activity available

**Data Acquisition** - low energy all purpose collimator/high resolution; 30sec/projection in 64 projections over 360 degrees on single-headed gamma camera

- acquisition processing
- uniformity correction
- filtered backprojection

# Iterative reconstruction / filtered back projection





## Dual Isotope Imaging with SPECT

- Bone scan with  $^{99m}\text{Tc}$ -MDP and Thyroid imaging with  $^{123}\text{I}$ /thyroid and parathyroid imaging
- $^{99m}\text{Tc}$  (140.5 keV)
- $^{123}\text{I}$  (159.0 keV)

Energy window ( $^{99m}\text{Tc}$ )

140 keV

Energy window ( $^{123}\text{I}$ )

160 keV

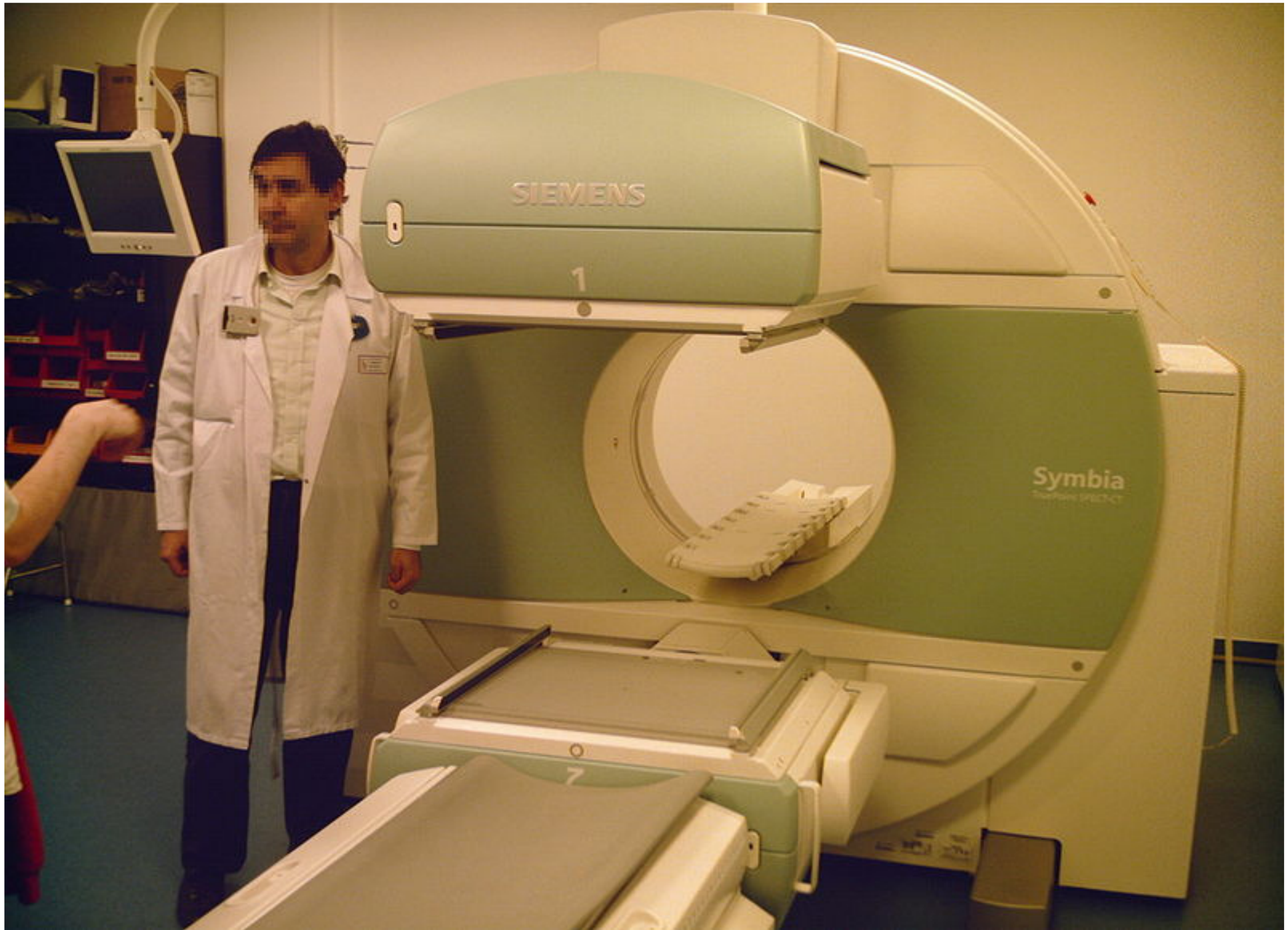

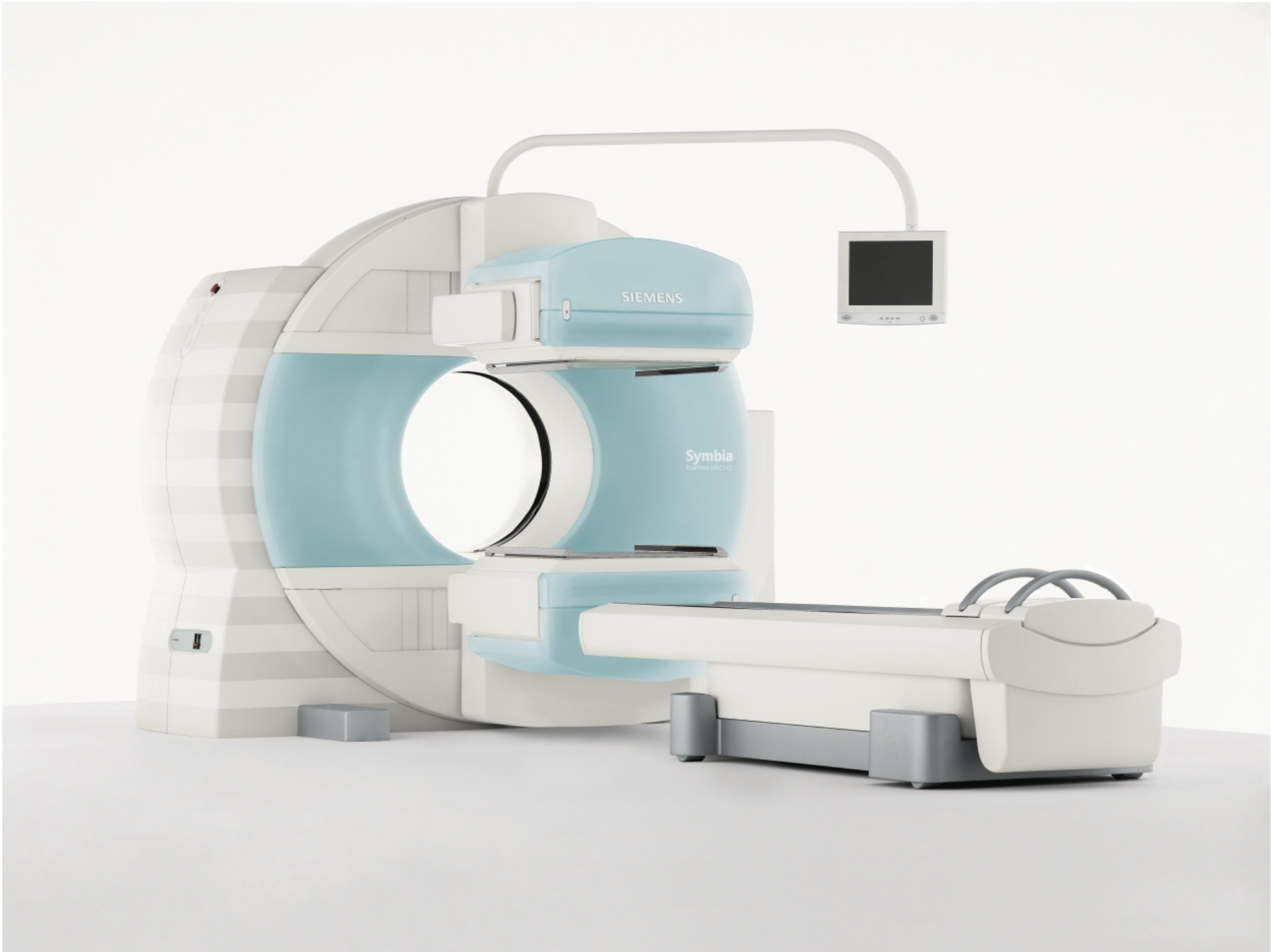# SPECT radionuclides

- $^{99m}\text{Tc}$  T1/2 = 6 hr,  $\gamma$  = 140 keV
- $^{111}\text{In}$  T1/2 = 67 hr;  $\gamma$ 's = 172, 245 keV
- $^{123}\text{I}$  T1/2 = 13 hr,  $\gamma$  = 159 keV
- $^{67}\text{Ga}$  T1/2 = 78 hr;  $\gamma$ 's = 93, 184, 296 keV
- $^{201}\text{Tl}$  T1/2 = 73 hr, 70 keV X-rays,  $\gamma$  = 167 keV
- $^{131}\text{I}$  T1/2 = 193 hr,  $\gamma$  = 364 keV\*
- $^{153}\text{Sm}$  T1/2 = 46 hr,  $\gamma$  = 103 keV\*

\* used for internal therapy ( $\beta^-$ ) as well!!!



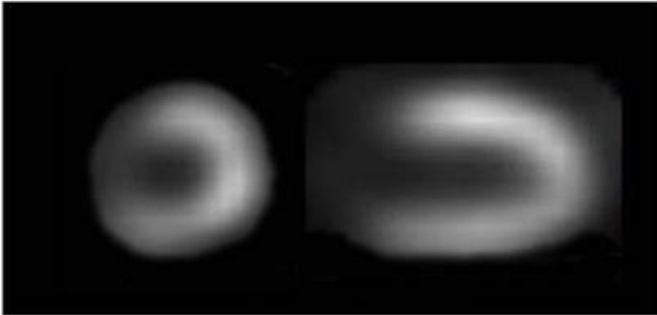
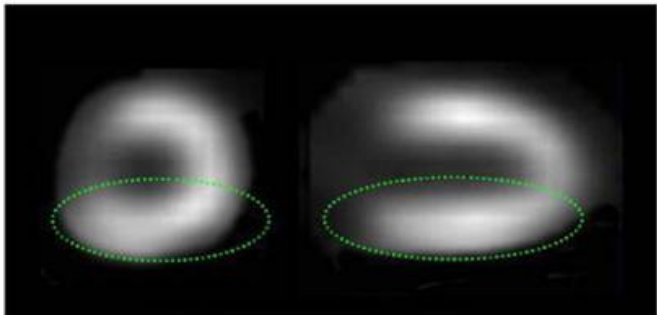

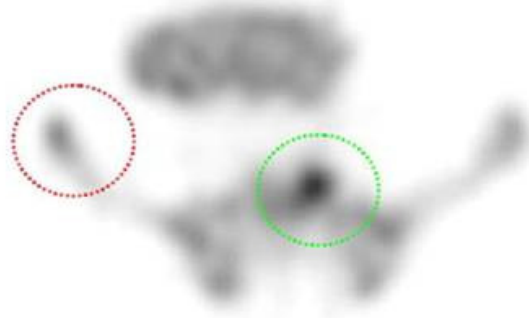
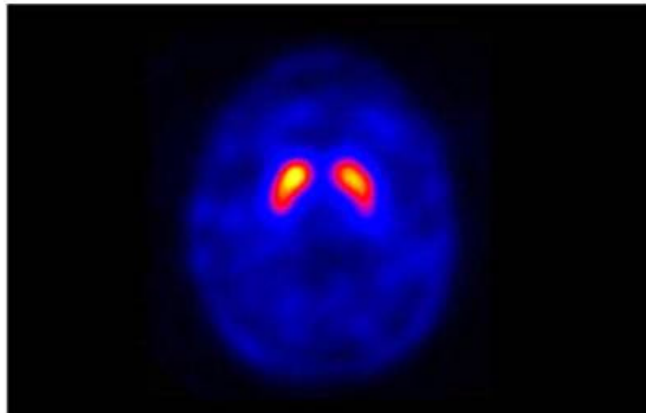
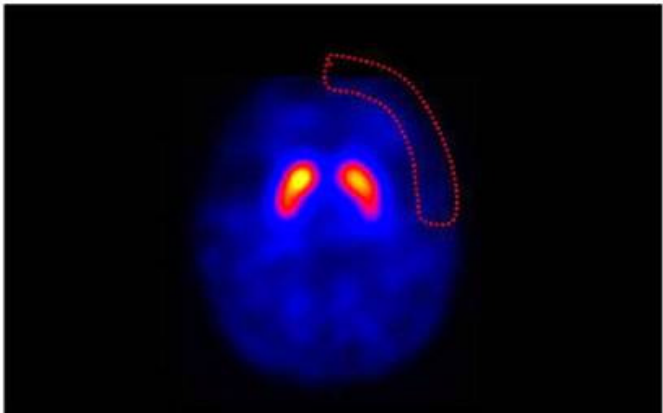






# BENEFITS OF FUSION IMAGING

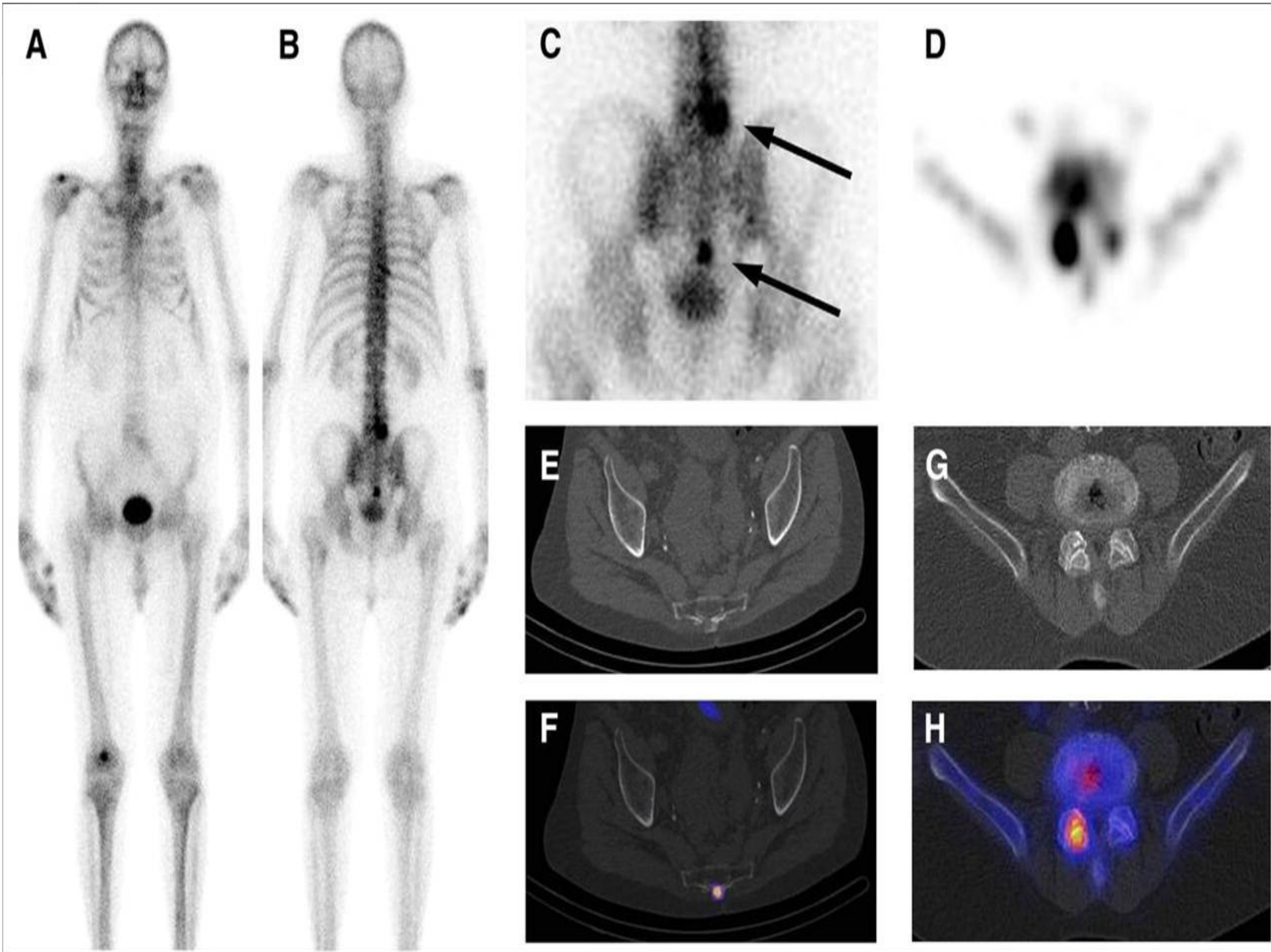
- Increased sensitivity and specificity
- Precise anatomic localization of findings seen in nuclear imaging
- Identify normal physiologic activity which can be misinterpreted as disease
- Patient convenience. Eliminates need for multi-day imaging protocol

	without CT attenuation correction	with CT attenuation correction
cardiac		
skeletal		
brain		



# MAIN INDICATIONS FOR SPECT/CT

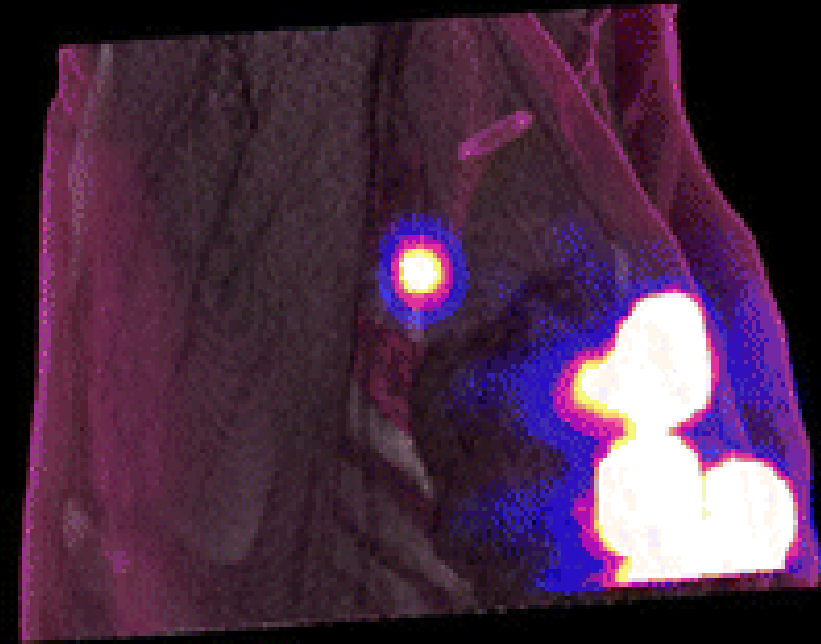
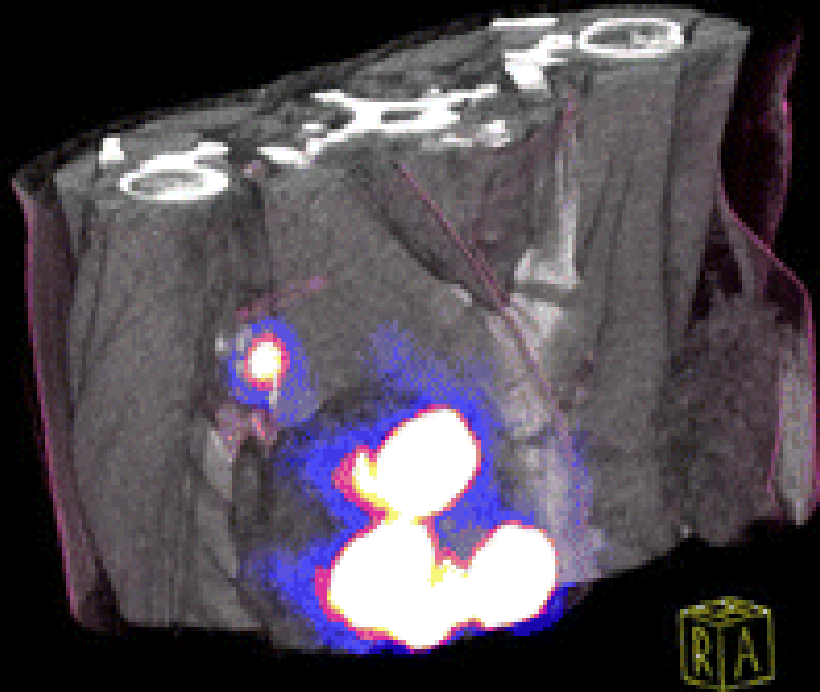
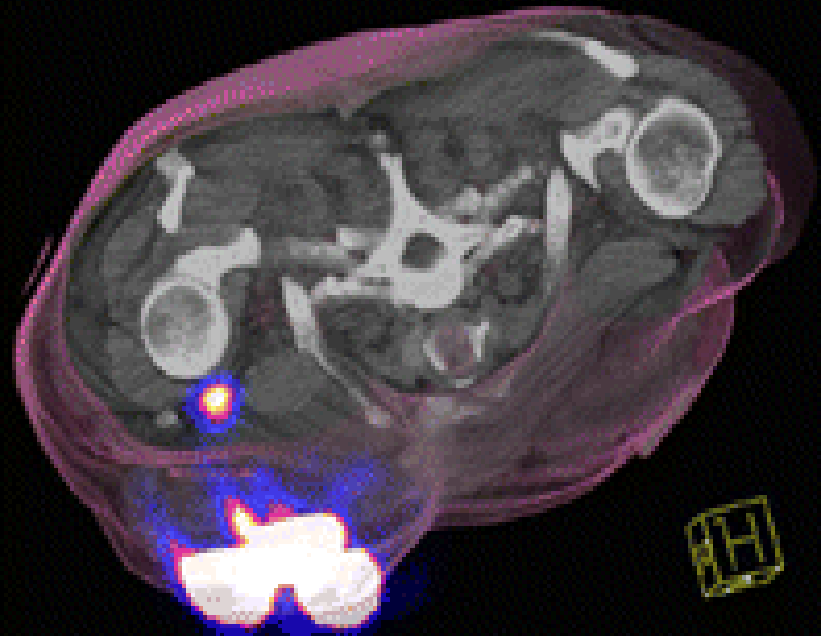
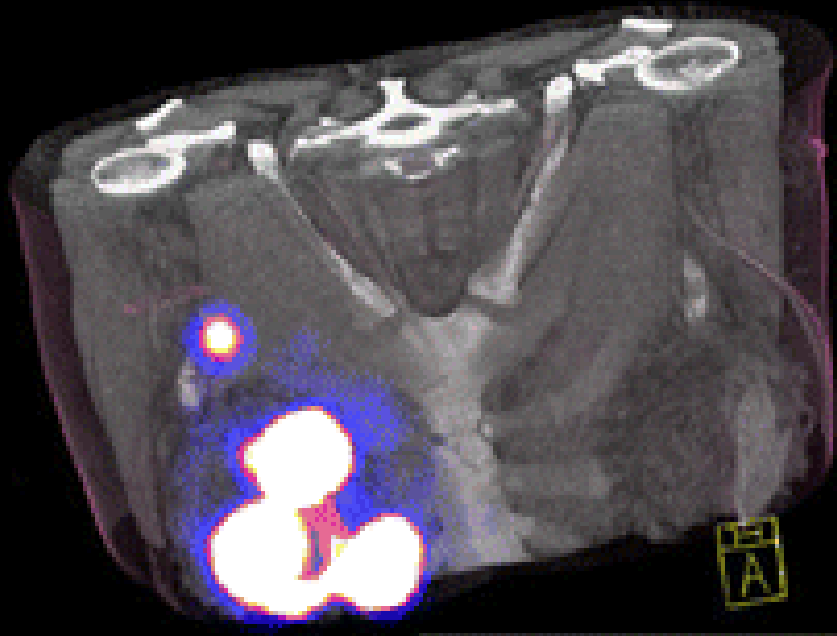
- Bone Scanning
- Graft Infections
- Cardiac Imaging
- Parathyroid Imaging
- Lymphoscintigraphy
- Tumor and mass localization
- Patients with abdominal pain
- Thyroid Cancer Staging



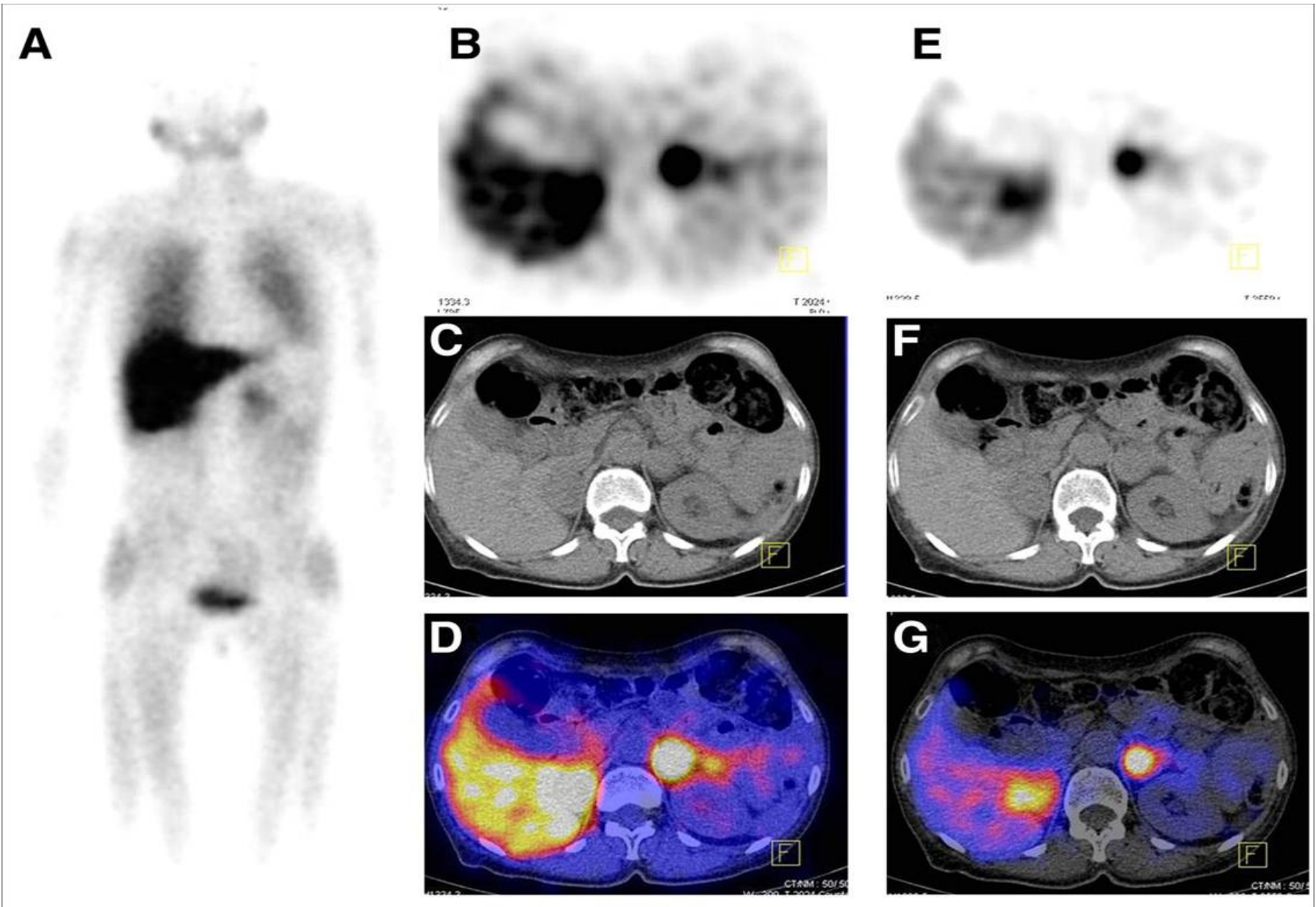


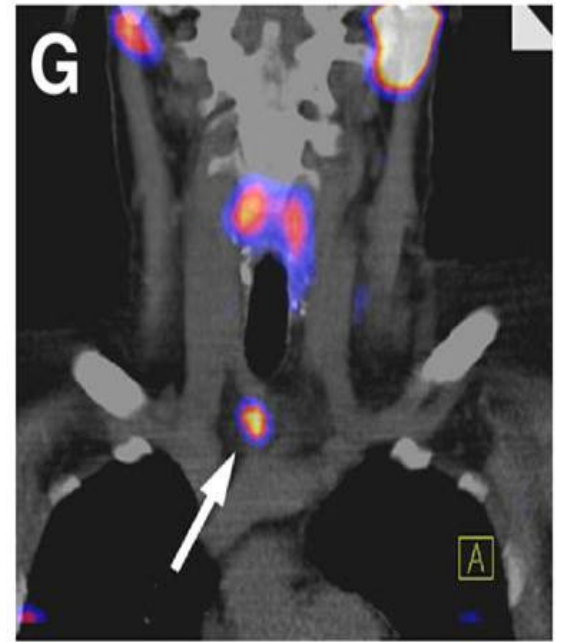
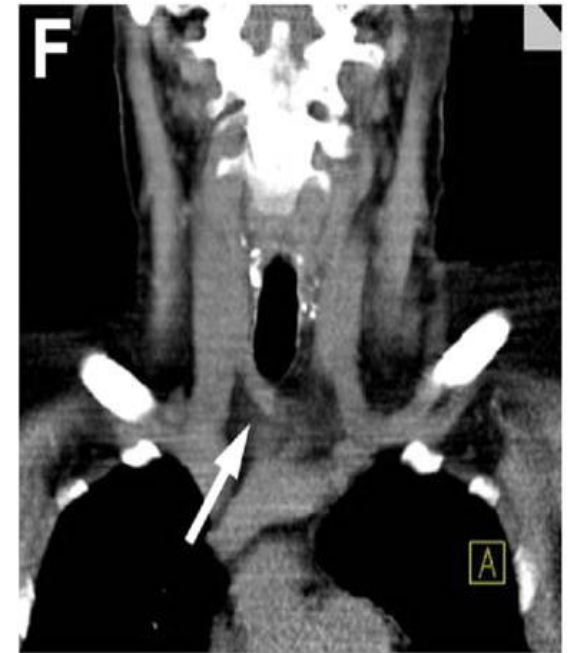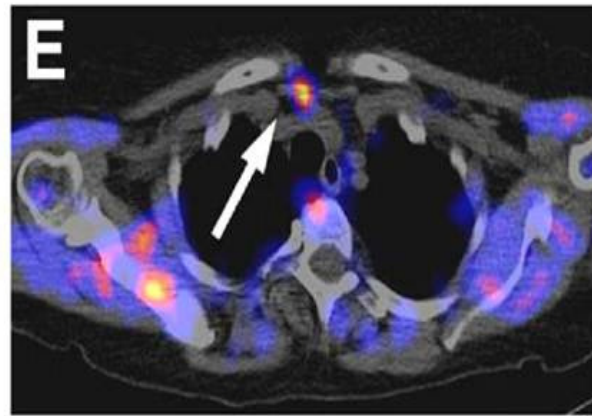
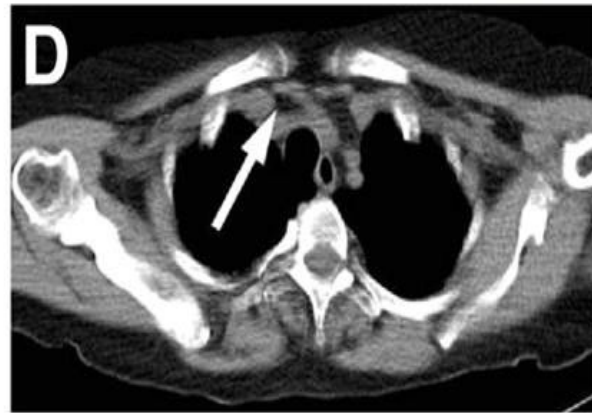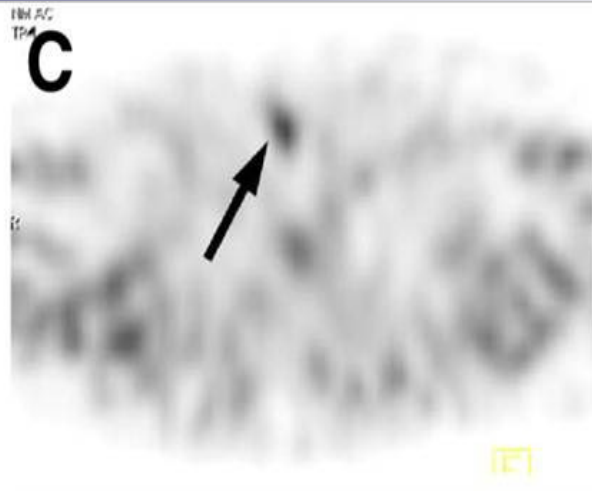
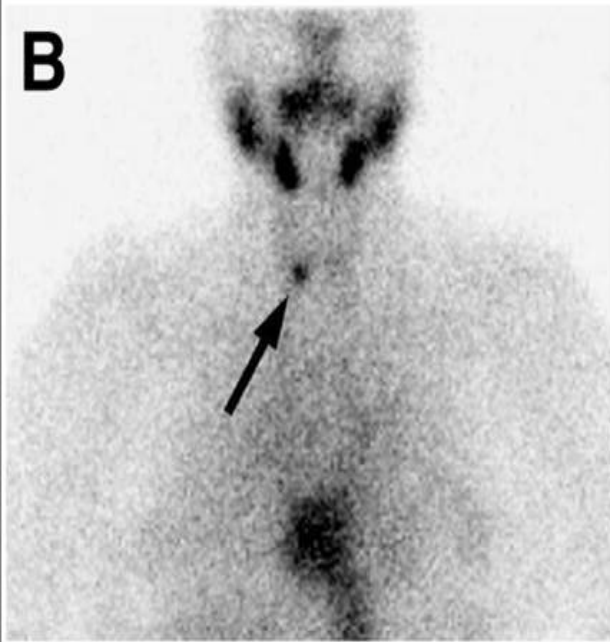
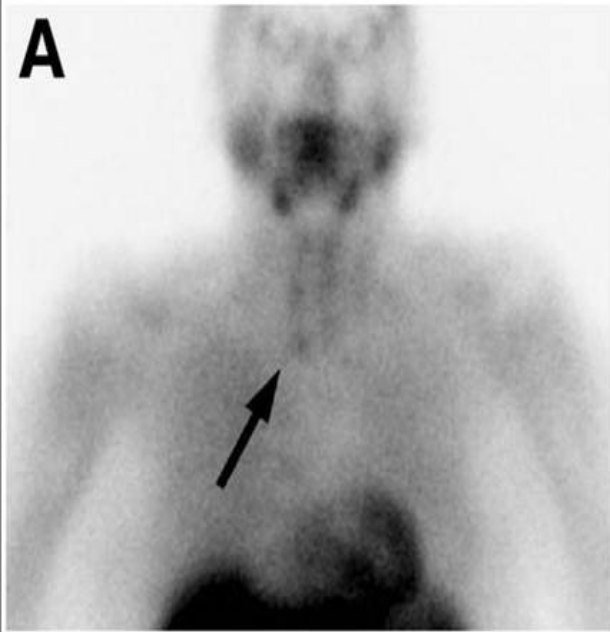
# BONE SCANS

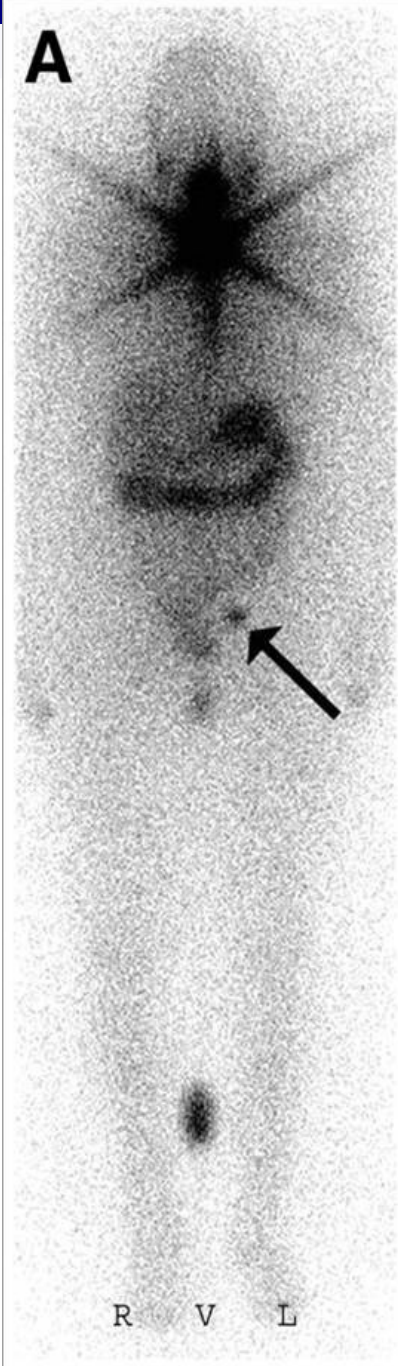
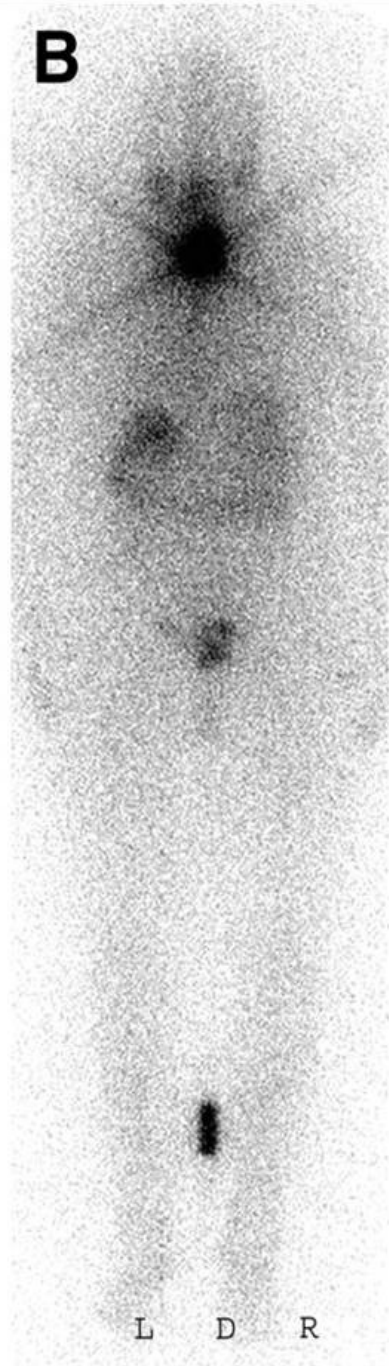
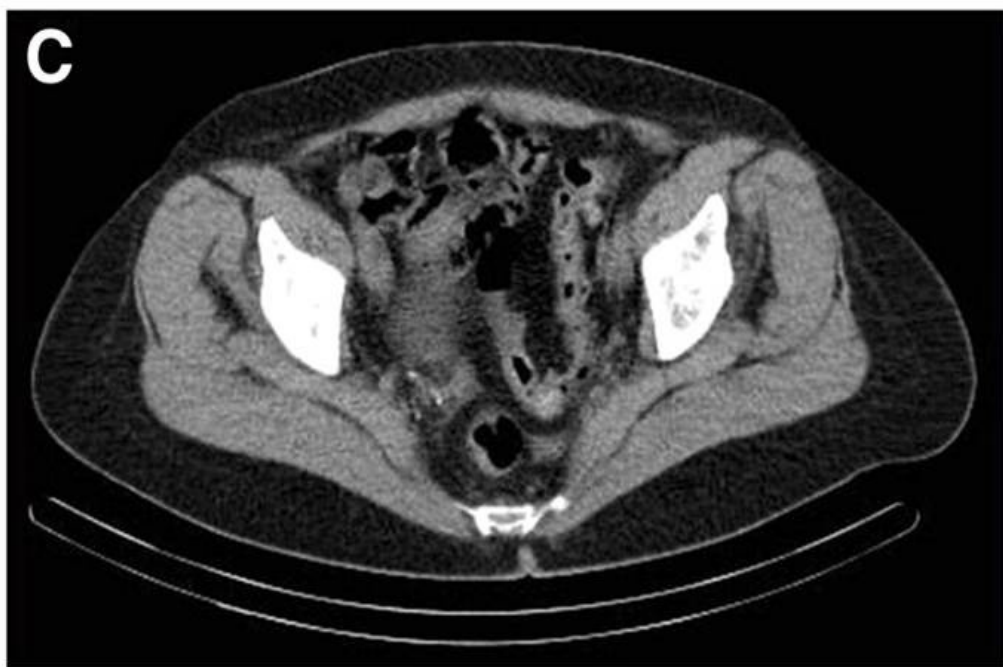
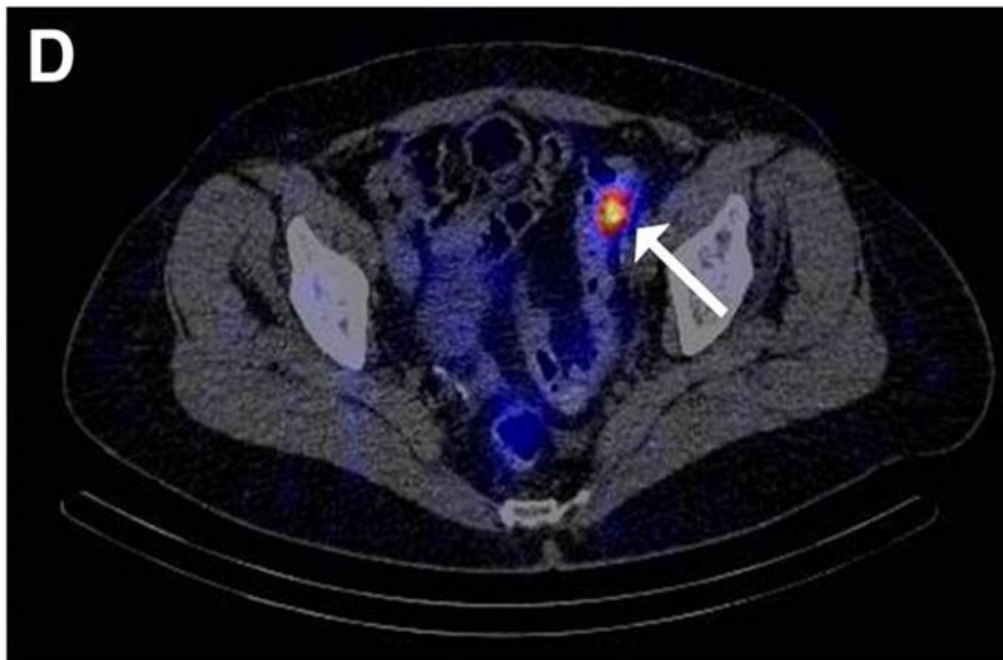
- Highly sensitive, but not often specific
- Benign processes can simulate malignancy
- Neoplastic lesions may occur in distribution suggestive of arthritic change
- Soft tissue abnormalities are usually not detected on routine bone scanning









**A****B****C****D**



Sarajevo Mai 2012

la physique des particules élémentaires,  
au LHC, l'expérience CMS,  
les recherches en cours.

D. Denegri  
CE Saclay, IRFU/SPP, France





THANK YOU. ENJOY THE CONFERENCE!

